



Original articles

Investigating the efficacy of ultrasound-guided ethanol retention technique for endometrioma sclerotherapy and its effect on pro-inflammatory cytokine levels: A single-arm clinical trial

Roghayeh Anvari Aliabad¹, Aliyeh Ghasemzadeh¹, Kobra Hamdi¹, Nazli Navali¹, Parvin Hakimi¹, Laya Farzadi¹ *¹ Women's Reproductive Health Research Center, Tabriz University of Medical Sciences, Tabriz, Iran

H I G H L I G H T S

- IL-1 β and AMH were lower, and IL-6 was higher in the endometriosis group.
- The treatment significantly decreased dysmenorrhea, dyspareunia, and cyst diameter.
- The treatment had no significant effect on the IL-1 β , IL-6, and AMH levels.

A R T I C L E I N F O

Keywords:
Endometrioma
Ethanol retention
Inflammation
Infertility

A B S T R A C T

Background: Endometriosis is a chronic inflammatory disease affecting about 10% of women of reproductive age. Endometrioma is the most common presentation of endometriosis in ovaries.

Objectives: Herein, the authors study the effect of the ultrasound-guided ethanol retention technique for endometrioma sclerotherapy and its effect on the plasma levels of pro-inflammatory cytokines.

Materials and methods: Each endometrioma was aspirated and washed with 0.9% saline until clearance and then 2/3 of the cyst volume was filled with ethanol 98%. Patients were followed for 3 months. After that, changes in their cyst diameter, dyspareunia, dysmenorrhea, and antral follicular count were assessed. Also, the sera levels of Interleukin 1 β (IL-1 β), IL-6, and IL-8 were assayed before and after the treatment. The primary sera levels were also compared with a control group.

Results: In the treatment and control groups, 23 and 25 individuals (respectively) with a matched mean age (p -value = 0.680) were enrolled in the study. Among the laboratory variables, IL-1 β (p -value = 0.035), as well as AMH (p -value = 0.002), were lower, and IL-6 (p -value = 0.011) was higher in the endometriosis group compared to the controls. Following the treatment, dysmenorrhea, dyspareunia, and the mean diameter of all cysts were significantly (p -values < 0.001) decreased in the treatment group. Also, right (p -value = 0.022) and left (p -value = 0.002) ovaries' antral follicular counts were increased following the treatment. No significant change was found among any of the investigated laboratory levels (p -value > 0.05).

Conclusion: Ethanol retention method is proven to be safe and could improve the clinical status of patients with endometrioma. Although further studies are necessary.

Introduction

The presence of endometrial-like tissue in any organ/space other than the uterus has been defined as endometriosis [1]. This disease with a prevalence of up to 18% [2] (average 10%) [3] among women of fertility age is a common gynecologic issue. Also, the prevalence increases up to 42% and 31% in women with chronic pelvic pain and infertility, respectively [2]. The symptoms vary from asymptomatic to severe pelvic pain and infertility. According to the 2008 United States health care

costs for diseases report, endometriosis and a chronic disease such as diabetes place an economically same burden as each other with an average of 4000\$ [1]. The pathogenesis of endometriosis involves a combination of different pathways occurring within the immune system (inflammation), angiogenesis, and endocrine system. The endometrial tissue could present itself anywhere besides the uterus, activate the immune system, and, therefore, induce an inflammatory response via chemokines, prostaglandins, and cytokines [4]. Studies have shown that the serum/abdominal fluid levels of pro-inflammatory cytokines and

* Corresponding author.

E-mail address: Farzadi.l@tbzmed.ac.ir (L. Farzadi).<https://doi.org/10.1016/j.clinsp.2023.100224>

Received 17 January 2023; Revised 25 March 2023; Accepted 16 May 2023

chemokines such as Interleukin 1β (IL- 1β), IL-6, IL-8, and Tumor Necrosis Factor α (TNF- α) are higher in patients with endometriosis [4–7].

The presence of endometriosis in ovaries might cause a cyst named endometrioma, also known as a chocolate cyst [1]. Despite endometriosis being small lesions for which laparoscopic visualization is the golden standard of diagnosis [8], endometrioma could only be diagnosed via vaginal ultrasound or Magnetic Resonance Imaging (MRI) [9]. It has been shown that excision of endometrioma could negatively influence the ovarian follicular reserve represented by decreased Anti-Müllerian Hormone (AMH) [10].

Accordingly, this study aims to investigate the efficacy of an alternate treatment option, the ultrasound-guided ethanol retention technique for endometrioma sclerotherapy, and its effect on the pro-inflammatory cytokine levels in a setting of a prospective investigation with a 3-month follow-up.

Materials and methods

Study setting and ethics

This clinical trial was conducted in a tertiary obstetrics/gynecology hospital in Tabriz, Iran between January 2022 and August 2022. The inclusion criteria were considered as any women aged 18–49 with the approved diagnosis of endometrioma and a cyst diameter greater than 3 centimeters. The exclusion criteria were active cancer, abnormal CA-125 levels, pregnancy, history of any biological medications such as monoclonal antibodies in the past three months, consumption of any corticosteroids and/or Non-Steroidal Anti-Inflammatory Drugs (NSAIDs) in the past seven days, and cysts bigger than 150 mL. The patients were asked to voluntarily sign a consent form after being explained the aims and methods of the study according to their level of knowledge. This study has been approved by the Medical Ethics Committee of Tabriz University of Medical Sciences (IR.TBZMED.REC.1400.598) and registered in the Iranian Registry of Clinical Trials (IRCT) with approval number IRCT20130115012146N9.

Methodology

After meeting the inclusion and exclusion criteria, patients were enrolled in the study. Before the intervention, 5 mL of peripheral blood from the cubital vein was harvested from each patient. Then, they underwent vaginal ultrasound evaluation, and the volume of their cyst (s) was recorded. The fluid was aspirated consequently, and the cyst was washed with 0.9% saline solution until clearance. Finally, ethanol 98% was injected into the cyst(s) equal to 2/3 of its volume and retained there. The patients were followed for three months, after which they underwent another ultrasound investigation and blood sampling. A time interval of three months was set for the follow-up evaluation according to a similar study [11]. Also, before and three months after the intervention patients were asked to declare their dyspareunia and dysmenorrhea on a scale of 1–10 (10 severe pain, 5 moderate pain, and 1 lowest possible pain). This study also included a control group. This group donated 5 mL of blood and expressed their dyspareunia and dysmenorrhea score. Moreover, their antral follicular counts were investigated using ultrasound.

Healthy control group

In this study, in order to have a better understanding of the disease effect on the mentioned baseline characteristics, a healthy comparison group, as a control group at baseline was also evaluated. These individuals were assessed for levels of IL- 1β , IL-6, IL-8, and AMH. Also, their dyspareunia and dysmenorrhea scores as well as antral follicular counts were investigated and reported.

Enzyme-linked immunosorbent assay (ELISA)

The harvested blood samples were centrifuged at $1500 \times g$ for 10 minutes at 4°C and the supernatant (sera) was harvested and stored at -70°C . The levels of IL- 1β , IL-6, IL-8, AMH, and CA-125 were assayed by the ELISA method according to each kit manufacturer's instruction.

Statistical analysis

All the demobiographic data were recorded in a Microsoft Excel file by two different individuals and in case of any mismatch, a third person re-checked the issue. The categorical and continuous variables are shown as n (%) and mean \pm Standard Deviation (SD), respectively. The Kolmogorov-Smirnov test was used to check the normality assumption. Between-group analysis was performed through independent Student's *t*-test or Mann-Whitney test as a parametric and non-parametric test, respectively. For before and after analysis, paired *t*-test or Wilcoxon signed-rank test was used. Also, for the categorical variables, the authors benefited from Chi-Square/Fisher's exact tests. Any *p*-value less than 0.05 was considered statistically significant.

Results

After meeting the exclusion criteria, 23 out of 25 patients (mean age of 35.87 ± 5.11 years) were enrolled in the study (Fig. 1) with a mean infertility duration of 3.70 ± 4.30 years. After vaginal ultrasound evaluation, a total of 37 cysts with a mean volume of 65.45 ± 56.91 mL (mean diameter of 43.24 ± 13.11 mm) were demonstrated in the patient group. The pathology report for all aspirated fluid was compatible with endometriosis accompanied by the finding of “hemorrhagic black ground and hemosiderin-laden macrophages and neutrophils”. The mean age of 25 healthy individuals enrolled in the study was 35.24 ± 5.36 years (other details demonstrated in Table 1). No endometrioma was found in the control group. The scores for dyspareunia and dysmenorrhea in both groups are provided in Table 1.

According to the analyses, age and previous pregnancy history were found to not differ significantly between the groups (*p*-values > 0.05). Considering the clinical symptoms, dysmenorrhea and dyspareunia scores were significantly lower in the control group in comparison to the endometriosis group (*p*-values < 0.001). Regarding the ultrasound variables, the control group had a significantly higher number of right and left antral follicular counts (*p*-value < 0.001). Among the laboratory variables, IL- 1β (*p*-value = 0.035), IL-6 (*p*-value = 0.011), and AMH (*p*-value = 0.002) were significantly different in the endometriosis group compared to the controls (details have been shown in Table 1).

No significant side effect was reported by patients during the follow-up period. Following the ultrasound-guided ethanol retention technique for endometrioma sclerotherapy, the already mentioned variables were investigated in the intervention group. The mean diameter of all cysts was significantly reduced from 43.24 ± 13.11 to 21.83 ± 14.54 mm (*p*-value < 0.001). Accordingly, the treatment significantly reduced the scores of both dysmenorrhea and dyspareunia (*p*-values < 0.001). In the ultrasound investigation, it was shown that the right (*p*-value = 0.022) and left (*p*-value = 0.002) ovaries' antral follicular counts were increased following the treatment. No significant change was found among the laboratory levels (details have been provided in Table 2).

Discussion

The current study aimed to investigate the change in the pro-inflammatory profile of patients with endometrioma following receiving ethanol retention sclerotherapy. The levels of IL- 1β and IL-6 were detected to be higher in the patients with endometrioma compared to a control group. Also, the treatment didn't change the pro-inflammatory profile in patients. However, statistically significant changes in the cyst diameter,

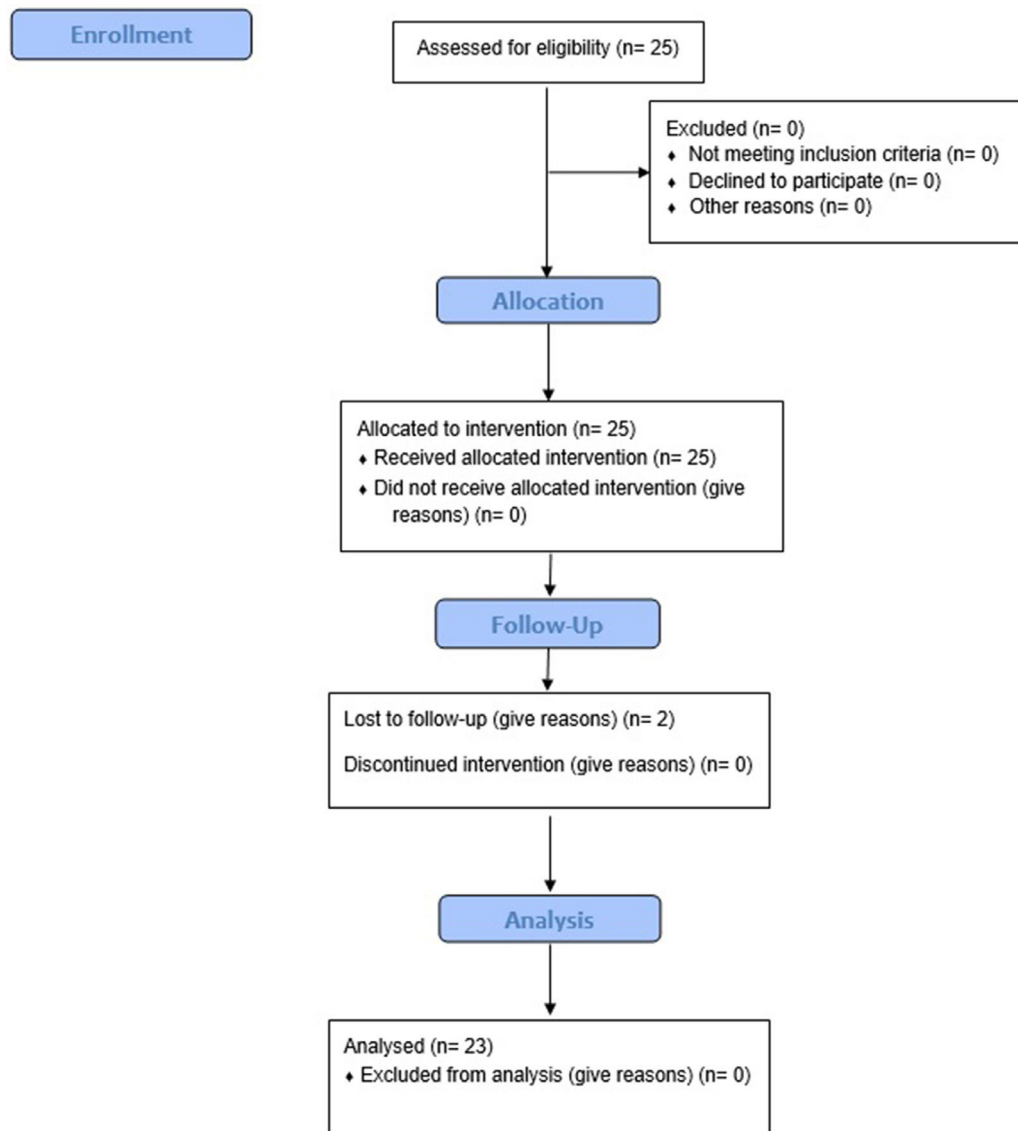


Fig. 1. Flow diagram of enrolment of patients in the study.

Table 1
Baseline characteristics between control and intervention groups.

Variable	Intervention group (n = 23)	Control group (n = 25)	p-value
Age	35.87 ± 5.11	35.24 ± 5.36	0.680 ^a
Previous pregnancy (%)	12 (52.17%)	13 (52.0%)	0.990 ^b
Dyspareunia score (of 10)	5.93 ± 2.46	2.13 ± 1.64	<0.001 ^a
Dysmenorrhea score (of 10)	7.56 ± 2.46	4.12 ± 2.02	<0.001 ^a
Left ovary antral follicular count	3.21 ± 2.31	6.62 ± 2.84	<0.001 ^a
Right ovary antral follicular count	3.08 ± 2.55	6.66 ± 2.71	<0.001 ^a
Interleukin 1β (pg/mL)	40.30 ± 50.54	97.74 ± 178	0.035 ^c
Interleukin 6 (pg/mL)	2.63 ± 3.95	0.56 ± 0.17	0.040 ^c
Interleukin 8 (pg/mL)	3.78 ± 14.28	1.05 ± 1.84	0.068 ^b
Anti-müllerian hormone (ng/mL)	1.28 ± 1.26	3.23 ± 2.59	0.002 ^c

Control group is a healthy compare group, p-value ^a is calculated based on the independent t-test, p-value ^b is calculated based on the Chi-Square test, p-value ^c is calculated based on the Mann Whitney test.

dyspareunia, dysmenorrhea, and ovary antral follicular count were found following the intervention.

In a study on 40 individuals with endometriosis, the serum, and peritoneal levels of IL-1β, IL-6, IL-10, and IL-37 were investigated and

Table 2
Statistical comparisons of variables between before and after the intervention (n = 23).

Variable	Before (n = 23)	After (n = 23)	p-value
Cyst diameter	43.24 ± 13.11	21.83 ± 14.54	<0.001 ^b
Dyspareunia score	5.93 ± 2.46	3.39 ± 2.46	<0.001 ^a
Dysmenorrhea score	7.56 ± 2.46	4.08 ± 3.20	<0.001 ^a
Left ovary antral follicular count	3.21 ± 2.31	4.91 ± 2.59	0.002 ^a
Right ovary antral follicular count	3.08 ± 2.58	4.43 ± 2.64	0.022 ^a
Interleukin 1β (pg/mL)	40.30 ± 50.54	39.00 ± 36.03	0.475 ^a
Interleukin 6 (pg/mL)	2.63 ± 3.95	4.23 ± 6.44	0.288 ^a
Interleukin 8 (pg/mL)	3.78 ± 14.28	0.62 ± 0.14	0.273 ^b
Anti-müllerian hormone (ng/mL)	1.28 ± 1.26	1.31 ± 1.54	0.481 ^a

p-value ^a is calculated based on the paired t-test, p-value ^b is calculated based on the Wilcoxon signed-rank test.

compared with 32 healthy controls. According to their analyses, it was shown that the serum and peritoneal levels of IL-1β and IL-10 were not significantly different between controls and patients with endometriosis. On the other hand, the serum and peritoneal levels of IL-6 and IL-37 were significantly higher in the endometriosis group compared to the controls [12]. These findings somehow (except for IL-1β) were

compatible with our findings. Another study investigated the serum concentrations of IL-6 and IL-8 in patients with endometrioma and deep infiltrating endometriosis as well as a healthy control group. According to their results, the levels of IL-6 in the sera of patients with endometrioma were significantly higher [13], similar to the results from our study.

To our knowledge, no study has evaluated the differences in sera levels of IL-1 β , IL-6, and IL-8 before and after the alcohol retention model. However, in a study comparing the efficacy of ethanol retention and aspiration models, authors have reported reduced pain and increased antral follicular count following the retention technique [14]. Although this study could be considered as a leading research in many aspects, there are still limitations to it among which the most important is the small sample size. Also, not investigating the peritoneal fluid along with serum is considered another limitation. Although the authors studied the most important pro-inflammatory factors associated with endometriosis, more factors could be analyzed which authors suggest for further studies.

Conclusion

Herein, it was demonstrated that the ultrasound-guided ethanol retention technique for endometrioma sclerotherapy seems to be a safe method due to no side effects reported by the patients. Although no significant changes were observed in the pro-inflammatory profile of the patients following the treatment, this method was able to reduce cyst diameter, dysmenorrhea, and dyspareunia as well as an increase in the antral follicular count. The authors suggest further detailed clinical trials on a greater population sample size.

Authors' contributions

Conceptualization: RAA and LF. Investigation: RAA, AG, KH, NN, PH, and LF. Methodology: RAA, LF. Project administration: RAA and LF. Validation: RAA. Supervision: LF. Software: RAA. Writing – original draft: RAA, AG, KH, NN, PH, and LF. Writing – review & editing: RAA, AG, KH, NN, PH, and LF.

Trail registration number

IRCT20130115012146N9.

Medical Ethics Committee approval number

IR.TBZMED.REC.1400.598.

Declaration of Competing Interest

The authors declare that they have no known competing financial interests or personal relationships that could have appeared to influence the work reported in this paper.

Funding

This study was not funded.

Supplementary materials

Supplementary material associated with this article can be found in the online version at doi:10.1016/j.clinsp.2023.100224.

References

1. Zondervan KT, Becker CM, Missmer SA. Endometriosis. *N Engl J Med* 2020;**382**(13):1244–56.
2. Moradi Y, Shams-Beyranvand M, Khateri S, Gharahjeh S, Tehrani S, Varse F, et al. A systematic review on the prevalence of endometriosis in women. *Indian J Med Res* 2021;**154**(3):446–54.
3. Shafrir AL, Farland LV, Shah DK, Harris HR, Kvaskoff M, Zondervan K, et al. Risk for and consequences of endometriosis: a critical epidemiologic review. *Best Pract Res Clin Obstet Gynaecol* 2018;**51**:1–15.
4. Symons LK, Miller JE, Kay VR, Marks RM, Liblik K, Koti M, et al. The immunopathophysiology of endometriosis. *Trends Mol Med* 2018;**24**(9):748–62.
5. Vercellini P, Viganò P, Somigliana E, Fedele L. Endometriosis: pathogenesis and treatment. *Nat Rev Endocrinol* 2014;**10**(5):261–75.
6. Sikora J, Mielczarek-Palacz A, Kondra-Anasz Z. Association of the precursor of interleukin-1 β and peritoneal inflammation-role in pathogenesis of endometriosis. *J Clin Lab Anal* 2016;**30**(6):831–7.
7. Li S, Fu X, Wu T, Yang L, Hu C, Wu R. Role of interleukin-6 and its receptor in endometriosis. *Med Sci Monit* 2017;**23**:3801–7.
8. Dunselman GA, Vermeulen N, Becker C, Calhaz-Jorge C, D'Hooghe T, De Bie B, et al. ESHRE guideline: management of women with endometriosis. *Hum Reprod* 2014;**29**(3):400–12.
9. Nisenblat V, Bossuyt PM, Farquhar C, Johnson N, Hull ML. Imaging modalities for the non-invasive diagnosis of endometriosis. *Cochrane Database Syst Rev* 2016;**2**(2). Cd009591.
10. Practice Committee of the American Society for Reproductive Medicine. Endometriosis and infertility: a committee opinion. *Fertil Steril* 2012;**98**(3):591–8.
11. Han K, Seo SK, Kim MD, Kim GM, Kwon JH, Kim HJ, et al. Catheter-directed sclerotherapy for ovarian endometrioma: short-term outcomes. *Radiology* 2018;**289**(3):854–9.
12. Jiang J, Jiang Z, Xue M. Serum and peritoneal fluid levels of interleukin-6 and interleukin-37 as biomarkers for endometriosis. *Gynecol Endocrinol* 2019;**35**(7):571–5.
13. Carmona F, Chapron C, Martínez-Zamora M-A, Santulli P, Rabanal A, Martínez-Flórens M, et al. Ovarian endometrioma but not deep infiltrating endometriosis is associated with increased serum levels of interleukin-8 and interleukin-6. *J Reprod Immunol* 2012;**95**(1–2):80–6.
14. Hsieh CL, Shiau CS, Lo LM, Hsieh TT, Chang MY. Effectiveness of ultrasound-guided aspiration and sclerotherapy with 95% ethanol for treatment of recurrent ovarian endometriomas. *Fertil Steril* 2009;**91**(6):2709–13.