



Enfermedades Infecciosas y Microbiología Clínica

www.elsevier.es/eimc



Original article

Hemophagocytic lymphohistiocytosis associated with *Leishmania*: A hidden passenger in endemic areas



Jon Badiola^{a,*}, Leopoldo Muñoz-Medina^b, José Luis Callejas^c, Alicia Delgado-García^a, Manuel Jurado^a, José Hernández-Quero^b

^a Department of Hematology and Hemotherapy, Hospital Universitario Virgen de las Nieves, Granada, Spain

^b Department of Infectious Disease, Hospital Universitario San Cecilio, Granada, Spain

^c Department of Autoimmune Diseases, Hospital Universitario San Cecilio, Granada, Spain

ARTICLE INFO

Article history:

Received 8 January 2020

Accepted 19 April 2020

Available online 28 May 2020

Keywords:

Hemophagocytic lymphohistiocytosis

Leishmania

Kala-azar

Real-time PCR

ABSTRACT

Introduction: Hemophagocytic lymphohistiocytosis (HLH) is an aggressive and life-threatening syndrome characterized by excessive immune activation. We analyzed the presentation, diagnosis and prognosis of our cohort of HLH-*Leishmania* cases.

Methods: We studied HLH cases in patients over 14 years of age in the province of Granada (Spain), from January 2008 to November 2019.

Results: In this study, *Leishmania* was the predominant trigger of adult HLH in our region. There were no differences in the clinical-analytical presentation between HLH triggered by *Leishmania* and those initiated by a different cause. RT-PCR was the best tool to identify *Leishmania* as the trigger of HLH, given that the other microbiological tests showed low sensitivity to detect the parasite in our HLH-*Leishmania* cases.

Conclusion: A comprehensive search for *Leishmania* is mandatory in HLH cases. Based on our findings, we propose that RT-PCR for *Leishmania* in bone marrow samples must be included in HLH differential diagnostic protocols.

© 2020 Elsevier España, S.L.U. and Sociedad Española de Enfermedades Infecciosas y Microbiología Clínica. All rights reserved.

Linfocitosis hemofagocítica asociada a *Leishmania*: el pasajero oculto en zonas endémicas

RESUMEN

Introducción: La linfocitosis hemofagocítica (LHH) es un síndrome agresivo y potencialmente mortal caracterizado por una activación inmune excesiva. Analizamos la presentación, el diagnóstico y el pronóstico de nuestra cohorte de casos LHH-*Leishmania*.

Métodos: Estudiamos los casos de LHH en pacientes mayores de 14 años en la provincia de Granada (España) desde enero de 2008 hasta noviembre de 2019.

Resultados: En este estudio, la *Leishmania* fue el desencadenante principal de la LHH en adultos en nuestra región. No hubo diferencias en la presentación clínico-analítica entre la LHH desencadenada por *Leishmania* y las iniciadas por otra causa. La PCR en tiempo real fue la mejor herramienta para identificar la *Leishmania* como el desencadenante de LHH, dado que las otras pruebas microbiológicas mostraron baja sensibilidad para detectar el parásito en nuestros casos de LHH-*Leishmania*.

Conclusión: Una búsqueda exhaustiva de la *Leishmania* es obligatoria en los casos de LHH. Considerando nuestros hallazgos, proponemos que la PCR en tiempo real de *Leishmania* en médula ósea se incluya en los protocolos de diagnóstico diferencial de LHH.

© 2020 Elsevier España, S.L.U.

y Sociedad Española de Enfermedades Infecciosas y Microbiología Clínica. Todos los derechos reservados.

Palabras clave:

Linfocitosis hemofagocítica

Leishmania

Kala-azar

PCR en tiempo real

* Corresponding author.

E-mail address: jbadilagonzalez@gmail.com (J. Badiola).

Introduction

Hemophagocytic lymphohistiocytosis (HLH) is a rare and devastating heterogeneous disorder in which defects in natural killer (NK) and T-cell granule-mediated cytotoxic function produce an uncontrolled inflammatory immune response and cytokine storm that lead to tissue damage and organ failure. Based on the HLH-2004 trial,¹ the diagnosis is performed when ≥ 5 of the following criteria are fulfilled: fever, splenomegaly, cytopenia, hypertriglyceridemia and/or hypofibrinogenemia, tissular hemophagocytosis phenomena, low NK-cell activity, hyperferritinemia and elevated sCD25. The number of reported HLH cases, especially in the adult population, has increased dramatically in the last years, probably due to the rise in the identification of the syndrome.²

The initial causative agent in most HLH cases is an inflammatory insult. As regards this, even if the predominant causes differ per country and age group, infectious diseases and neoplasms are the most common triggers worldwide.³

Visceral leishmaniasis (VL), also known as kala-azar, is a systemic infectious disease affecting the reticuloendothelial system caused by protozoa of the genus *Leishmania*, which are transmitted by the bite of infected phlebotomine sandflies. VL is globally spread and is endemic in more than 60 countries, with about 100,000 new cases each year.⁴ In Spain *Leishmania* is endemic, especially in Mediterranean areas, and has an incidence of 0.76 cases/100,000 inhabitants per year. The province of Granada is on the national average (0.49–0.95 cases/100,000 inhabitants per year).⁵

An association between VL and HLH is well-described in the literature, especially in childhood.^{6–8} Indeed, the *Leishmania* parasite is the most common protozoan zoonotic trigger of HLH.^{3,9} In spite of this, the association between both conditions is uncommon as *Leishmania* is the suggested trigger of HLH in only 0.77–2.1% of the cases.^{3,10} In the present work, we begin by providing a general description of HLH cases to proceed then to analyze the presentation, diagnosis and prognosis of the HLH-*Leishmania* entity in our cohort.

Methods

We collected HLH cases of patients over 14 years of age as diagnosed following the HLH-2004 criteria¹ in the two tertiary hospitals (*Hospital Universitario Virgen de las Nieves* and *Hospital Universitario San Cecilio*) in the province of Granada, in southern Spain. The timeframe of our search begins in January 2008 and finishes in November 2019.

We retrospectively collected demographic characteristics (sex, age), clinical features (presence of immunosuppression, highest measured fever and hepatosplenomegaly), laboratory findings (hemoglobin, leucocytes and platelet count, triglyceride, ferritin, lactate dehydrogenase [LDH], liver function tests, creatinine, C-reactive protein [CRP] and fibrinogen), evidence of the presence of hemophagocytosis phenomena, suggested trigger, treatment administered and outcome. The demographic, clinical, laboratory and pathological findings were obtained from the medical records of the day in which the diagnosis of HLH was made.

In *Leishmania*-triggered HLH cases we also collected microbiological findings that allowed the diagnosis, such as parasite visualization (Fig. 1), leishmanial antigen in urine (latex agglutination test, KAtex), molecular detection of DNA (Real-Time PCR [RT-PCR]) in bone marrow and spleen (in those cases in which the splenectomy had been performed) and parasite isolation by in vitro culture (Novy-MacNeal-Nicolle medium).

We first provide a basic descriptive analysis of the data and then we proceed with the statistical analysis. Categorical variables

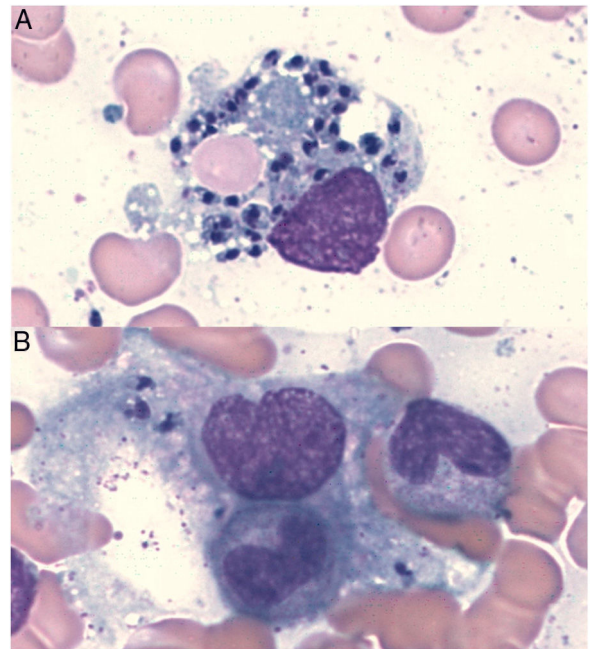


Fig. 1. Intracellular *Leishmania* amastigotes in macrophages with hemophagocytic phenomena (A: erythrocytes, B: band neutrophil) in a bone marrow aspiration sample (Wright's stain, original magnification $\times 100$).

are analyzed using Pearson's Chi-squared test, while continuous variables are compared with two-tailed, independent-samples Student's *t*-test or Mann–Whitney *U* test when there was a deviation from normality in the data. We set the significance level to $\alpha < 0.05$.

Results

Thirty patients were diagnosed with HLH in the timeframe analyzed. Infectious diseases were the most common triggers – 13 cases (43.3%: 6 *Leishmania*, 4 CMV, 1 EBV, 1 HIV and 1 *Brucella*) – followed by oncohematological triggers – 6 cases (20%: 2 T and 2 B lymphomas, 1 acute lymphoblastic leukaemia and 1 colorectal cancer) –, autoimmune triggers – 6 cases (20%: 4 systemic lupus erythematosus, 1 inflammatory bowel disease and 1 antiphospholipid syndrome) – and idiopathic causes – 5 cases (16.6%) –.

There were no statistically significant differences in the characteristics or in the clinical-analytical presentation between HLH triggered by *Leishmania* and those cases initiated by a different cause (see [Supplementary material](#)).

The clinical and analytical characteristics at presentation, the results of the microbiological diagnosis tests and the follow-up of HLH-*Leishmania* patients can be found in [Table 1](#).

In 2 of the cases, a splenectomy was performed due to suspicion of a splenic lymphoproliferative disorder at the beginning of process. The HLH-2004 treatment protocol¹ was initiated in one of them because there were no analytical findings suggestive of *Leishmania* (negative visualization and culture in the bone marrow and negative antigen in urine [RT-PCR was not performed]). Interestingly, this patient had a deteriorating clinical course with HLH relapse despite the multiple immunosuppressant treatments administered. We then obtained a new bone marrow sample where we had a direct visualization of the parasite and positive culture results. Accordingly, a diagnosis of disseminated *Leishmania* was made and the corresponding treatment was initiated. In order to determine if the parasite was present before the immunosuppressant treatment, we performed an RT-PCR for *Leishmania* in the previous splenectomy sample (taken at the time of HLH diagnosis), obtaining a positive result.

Table 1Clinical and analytical characteristics at presentation, results of the microbiological diagnostic tests and follow-up of HLH-*Leishmania* patients.

Patient	1	2	3	4	5	6
Sex	F	M	M	M	M	F
Age (years)	27	72	46	43	67	47
Immunosuppression	—	—	+(HIV)	—	—	—
Fever (°C)	38.5	38.7	39.5	40.8	38.8	38.5
Hepatomegaly	+	—	+	+	+	+
Splenomegaly	+	+	+	+	+	+
Lymphadenopathy	—	—	+	—	+	—
Cytopenia						
Hb (g/dL)	6.4	11.1	6.7	8.9	7.5	7.7
Neutr. (/μL)	1640	1570	250	700	1510	910
Plt. (/μL)	87,000	47,000	13,000	73,000	62,000	20,000
Triglycerides (mg/dL)	232	223	164	411	216	459
Fibrinogen (mg/dL)	NA	NA	NA	NA	263	93
Ferritin (ng/mL)	1790	14,135	2799	3581	5528	11,995
Hemophagocytosis	+(BM and Spleen)	+(BM)	+(BM)	+(Spleen)	+(BM)	+(BM)
Creatinine (mg/dL)	0.9	1.3	4	0.9	2.38	0.48
Total Bilirubin (mg/dL)	1.1	1.26	19.9	0.44	15.3	2.63
ALT/AST (IU/L)	74/68	337/184	16/18	143/67	143/293	16/53
LDH (IU/L)	946	3250	384	847	573	135
CRP (mg/L)	84	157	255	142	253	201
Time from the onset of symptoms to diagnosis (days)						
HLH	43	11	64	59	35	64
VL	657	7	42	63	35	62
Microbiological diagnostic tests						
Parasite visualization	—	+	+	—	—	+
RT-PCR	+(at relapse) +(in spleen retrospectively) +(in BM at relapse)	+(in BM)	+(in BM)	+(in BM and spleen)	+(in BM)	+(in BM)
Urine Ag	—	+	—	—	+	+
Culture (NNN)	+(at relapse) —	+	—	NA	NA	—
Therapy	CS, IVIG, CycA, VP-16 At relapse: Tocilizumab and LAmB	CS, CycA, IVIG, LAmB	CS, IGIV, LAmB	CS, LAmB	CS, IVIG, LAmB	CS, IVIG, LAmB
Outcome	Alive	Death (non HLH or VL related)	Death (HLH and VL related)	Alive	Alive	Alive
Relapse						
HLH	+	—	—	—	—	—
VL	—	—	—	—	—	—
Median follow-up (months)	136	66	2	77	42	8

ALT/AST, Alanine Aminotransferase/Aspartate Aminotransferase; BM, Bone marrow; CRP, C-reactive protein; CS, Corticosteroids; CycA, Cyclosporine; F, Female; Hb, Hemoglobin; HIV, Human immunodeficiency virus; HLH, Hemophagocytic lymphohistiocytosis; IVIG, Intravenous immunoglobulin; LAmB, Liposomal amphotericin; LDH, Lactate dehydrogenase; M, Male; NA, No available; Neutr, Neutrophil; NNN, Novy-MacNeal-Nicolle medium; Plt, Platelets; RT-PCR, Real-time PCR; VL, Visceral leishmaniasis; VP-16, Etoposide.

All the six *Leishmania* patients were treated with liposomal amphotericin B (5 mg/kg on days 1, 5 and 10 and monthly for 3 additional doses) and methylprednisolone (0.5–1 mg/kg/daily). One patient with HIV developed multiorgan failure and died 4 days after the HLH diagnosis. Importantly, the mortality rate of *Leishmania* patients (16.6%) was lower than the rate of patients without *Leishmania* (45.8%), although this difference did not reach statistical significance ($X_1^2 = 1.7$; $p = 0.19$).

Conclusions

The overlap in the clinical and analytical presentation between HLH and VL and the fact that HLH triggered by *Leishmania* is indistinguishable from that triggered by a different agent, make the diagnosis of this association a considerable challenge. *Leishmania*, far from being an infrequent cause of HLH, is the predominant trigger of adult HLH in our region, being the causative agent in 20% of all the HLH cases. This percentage is considerably higher than those reported in the previous studies,^{3,10} which may be attributable to three factors: first, the study was done in an endemic area; second, the preexisting clinical suspicion of the HLH-*Leishmania*

association; and third, the use of molecular tests to detect the parasite. In our opinion, due to diagnostic challenges, this association may be underestimated with fatal consequences in endemic areas.

VL, caused by *Leishmania infantum* (the only endemic species in the Iberian Peninsula) and *Leishmania donovani*, is the single form of leishmaniasis related with HLH. Although the precise mechanisms of *Leishmania*-triggered HLH onset remain unknown, it seems that the Th1/Th2 disbalance and the cytokine storm produced by the abnormal T-lymphocyte response induced by the parasite may result in uncontrolled activation of the mononuclear phagocyte system leading to HLH.^{11,12}

The identification of the exact trigger in HLH is mandatory. The precise treatment of the causing agent will likely result in the elimination of the stimulus that initially caused the abnormal immune activation.^{2,3} Consequently, it can be argued that those therapies specifically aimed at the treatment of the triggering agent will be essential in patients with secondary HLH^{7,8,13} making other aggressive treatments such as chemotherapy-based protocols or allogeneic hematopoietic stem cell unnecessary. These considerations are especially important in those cases of HLH

associated with infections where severe immunosuppression without an adequate antimicrobial agent could be devastating. Consequently, the prognosis seems to be better in those HLH cases where *Leishmania* is identified and treated.^{7,8,10} However, in our experience, in cases where the cytokine release syndrome has been identified, the addition of low-dose corticosteroids and immunoglobulins to the treatment of the trigger could be beneficial to cease the cytokine storm. In the deceased patient in our series, the diagnosis of HLH triggered by *Leishmania* was performed when the disease had already progressed. This emphasizes the need of the early diagnosis of this association.

Excluding the presence of *Leishmania* should be mandatory in every HLH patient with all possible tools, given that a multiple test approach for the diagnosis of *Leishmania* is currently recommended.^{4,14} However, it is crucial to keep in mind that the visualization of the parasite in the bone marrow smear, the detection of leishmanial antigen in urine and the in vitro culture have low sensitivity to identify patients with combined HLH and *Leishmania*, probably because of the paucimicrobial nature of the disorder.^{6–8,12} In our study, DNA-based assays seem to be the best tool to identify *Leishmania* as the trigger of HLH, being positive in all of our cases. Thus, leishmanial RT-PCR in bone marrow should be included in HLH protocols. In future studies, other diagnostic methods like RT-PCR in peripheral blood, serological tests (recombinant antigen rK39, direct agglutination tests, enzyme-linked immunosorbent assays or indirect fluorescent antibody tests) or cell-mediated immune response tests should be explored to ascertain their usefulness in identifying *Leishmania* as HLH trigger.

Furthermore, the importance of the association between HLH and *Leishmania* could be bidirectional. Hypertriglyceridemia has been identified as a marker of severity in VL.¹⁵ This could identify those VL cases where the inflammation is more severe and where the HLH may be underrecognized.¹⁶ Consequently, the early detection of these cases by the clinician is vital to evaluate the need for complementary immunosuppressant therapy.

In light of our findings, we suggest that an active and intensive search of *Leishmania* is required in every case of HLH in endemic areas. Moreover, because of the current migratory movements and the ensuing rise of *Leishmania*-HLH cases in non-endemic areas,^{10,13} the proposed *Leishmania* search strategy should be applied worldwide.

Authorship

JB, LMM, JLC, ADG, MJ and JHQ: analyzed and interpreted the data, revised and approved the final manuscript. JB, LMM and JHQ: contributed manuscript writing.

Funding

The author(s) received no specific funding for this work.

Conflict of interest

The authors do not have potential conflicts of interest.

Appendix A. Supplementary data

Supplementary data associated with this article can be found, in the online version, at [doi:10.1016/j.eimc.2020.04.012](https://doi.org/10.1016/j.eimc.2020.04.012)

References

- Henter JL, Horne A, Aricó M, Egeler RM, Filipovich AH, Imashuku S, et al. HLH-2004: diagnostic and therapeutic guidelines for hemophagocytic lymphohistiocytosis. *Pediatric Blood and Cancer*. 2007;48:124–31.
- Jordan MB, Allen CE, Weitzman S, Filipovich AH, McClain KL. How I treat hemophagocytic lymphohistiocytosis. *Blood*. 2011;118:4041–52.
- Ramos-Casals M, Brito-Zeron P, Lopez-Guillermo A, Khamashta MA, Bosch X. Adult haemophagocytic syndrome. *Lancet*. 2014;383:1503–16. [http://dx.doi.org/10.1016/S0140-6736\(13\)61048-X](https://doi.org/10.1016/S0140-6736(13)61048-X).
- Burza S, Croft SL, Boelaert M. Leishmaniasis. *Lancet* (Lond, Engl). 2018;392:951–70. Available from: <https://linkinghub.elsevier.com/retrieve/pii/S0140673618312042>
- Fernández Martínez B, Gómez Barroso D, Cano Portero R. La leishmaniasis en España: evolución de los casos notificados a La Red Nacional de Vigilancia Epidemiológica desde 2005 a 2017 y resultados de la vigilancia de 2014 a 2017. *Boletín epidemiológico Sem*. 2019;27. Available from: <http://revista.isciii.es/index.php/bes/issue/view/254>
- Koubâa M, Mâaloul I, Marrakchi C, Mdhaïffar M, Lahiani D, Hammami B, et al. Hemophagocytic syndrome associated with visceral leishmaniasis in an immunocompetent adult-case report and review of the literature. *Ann Hematol*. 2012;91:1143–5. [http://dx.doi.org/10.1007/s00277-011-1367-0](https://doi.org/10.1007/s00277-011-1367-0).
- Scalzoni M, Ruggiero A, Mastrangelo S, Trombatore G, Ridola V, Maurizi P, et al. Hemophagocytic lymphohistiocytosis and visceral leishmaniasis in children: case report and systematic review of literature. *J Infect Dev Ctries*. 2016;10:103–8. Available from: <http://jicd.org/index.php/journal/article/view/26829545>
- Rajagopala S, Dutta U, Chandra KSP, Bhatia P, Varma N, Kochhar R. Visceral leishmaniasis associated hemophagocytic lymphohistiocytosis – case report and systematic review. *J Infect*. 2008;56:381–8. Available from: <https://linkinghub.elsevier.com/retrieve/pii/S0163445308000984>
- Cascio A, Pernice LM, Barberi G, Delfino D, Biondo C, Beninati C, et al. Secondary hemophagocytic lymphohistiocytosis in zoonoses. A systematic review. *Eur Rev Med Pharmacol Sci*. 2012;16:1324–37. Available from: <http://www.ncbi.nlm.nih.gov/pubmed/23104648>
- Bode SFN, Bogdan C, Beutel K, Behnisch W, Greiner J, Henning S, et al. Hemophagocytic lymphohistiocytosis in imported pediatric visceral leishmaniasis in a nonendemic area. *J Pediatr*. 2014;165, 147–153.e1. Available from: <https://linkinghub.elsevier.com/retrieve/pii/S0022347614003114>
- Kharazmi A, Kemp K, Ismail A, Gasim S, Gaafar A, Kurtzhals JA, et al. T-cell response in human leishmaniasis. *Immunol Lett*. 1999;65:105–8. Available from: <http://www.ncbi.nlm.nih.gov/pubmed/10065635>
- Ozyürek E, Özçay F, Yılmaz B, Özbek N. Hemophagocytic lymphohistiocytosis associated with visceral leishmaniasis: a case report. *Pediatr Hematol Oncol*. 2005;22:409–14. Available from: <http://www.ncbi.nlm.nih.gov/pubmed/16020131>
- Watkins ER, Shamasunder S, Cascino T, White KL, Katrak S, Bern C, et al. Visceral leishmaniasis-associated hemophagocytic lymphohistiocytosis in a traveler returning from a pilgrimage to the Camino de Santiago. *J Travel Med*. 2014;21:429–32. Available from: <https://academic.oup.com/jtm/article-lookup/doi/10.1111/jtm.12145>
- Aronson N, Herwaldt BL, Libman M, Pearson R, Lopez-Velez R, Weina P, et al. Diagnosis and treatment of leishmaniasis: clinical practice guidelines by the Infectious Diseases Society of America (IDSA) and the American Society of Tropical Medicine and Hygiene (ASTMH). *Clin Infect Dis*. 2016;63:e202–64. Available from: <http://www.ncbi.nlm.nih.gov/pubmed/27941151>
- Lal CS, Verma RB, Verma N, Siddiqui NA, Rabidas VN, Pandey K, et al. Hypertriglyceridemia: a possible diagnostic marker of disease severity in visceral leishmaniasis. *Infection*. 2016;44:39–45. [http://dx.doi.org/10.1007/s15010-015-0811-9](https://doi.org/10.1007/s15010-015-0811-9).
- Colomba C, Di Carlo P, Scarlata F, Iaria C, Barberi G, Famà F, et al. Visceral leishmaniasis, hypertriglyceridemia and secondary hemophagocytic lymphohistiocytosis. *Infection*. 2016;44:391–2. [http://dx.doi.org/10.1007/s15010-016-0881-3](https://doi.org/10.1007/s15010-016-0881-3).