

## CLINICAL NOTE

# Isolated fracture of the body of the hamate bone. About a case

J. Torres,<sup>a,\*</sup> F. Abat,<sup>b</sup> E. Monteiro,<sup>a</sup> P. Gelber<sup>b</sup>

<sup>a</sup> Servicio Cirugía Ortopédica, Hospital S. Joao, Porto, Portugal

<sup>b</sup> Servicio Cirugía Ortopédica y Traumatología, Hospital de la Santa Creu i Sant Pau, Barcelona, Spain

Received November 21, 2010; accepted April 4, 2011

### KEYWORDS

Hamate fracture;  
Isolated;  
Conservative treatment

### Abstract

**Objective:** To demonstrate, through a clinical case, that fractures of the hamate bone are very infrequent and even more so those that affect its body without there being fractures of the other associated carpal bones. Due to its infrequency and to the non-specificity of its clinical manifestations, they are usually difficult to diagnose.

**Material and methods:** We present a case of a 24 year old male who suffered an isolated comminuted fracture of the body of the hamate bone. It was treated conservatively and full recovery without any functional deficit was obtained.

**Conclusions:** It is important to consider this type of fracture when confronted with a direct traumatism to the hand. Performing computed tomography (CT) is recommended in order to correctly identify the fracture and assess any possible associated lesions. The therapeutic decision depends on the degree of comminution of the fracture, its stability and any joint involvement.

© 2010 SECOT. Published by Elsevier España, S.L. All rights reserved.

### PALABRAS CLAVE

Fractura ganchoso;  
Aislada;  
Tratamiento conservador

### Fractura aislada del cuerpo del hueso ganchoso. A propósito de un caso

### Resumen

**Objetivo:** Mostrar mediante un caso clínico que las fracturas del hueso ganchoso son muy poco frecuentes, mucho menos aún las que afectan al cuerpo del mismo sin fracturas asociadas de otros huesos del carpo. Debido a su infrecuencia y a la inespecificidad de sus manifestaciones clínicas, suelen ser de difícil diagnóstico.

**Material y método:** Presentamos el caso de un varón de 24 años, que sufrió fractura conminuta aislada del cuerpo del hueso ganchoso. Fue tratado de forma conservadora, obteniéndose una recuperación *ad integrum* sin déficit funcional.

\* Corresponding author.

E-mail: jmcftorres@hotmail.com (J. Torres).

**Conclusiones:** Es importante considerar este tipo de fracturas ante un traumatismo directo sobre la mano. Es recomendable la realización de una tomografía computerizada (TC) para caracterizar correctamente la fractura y valorar las posibles lesiones asociadas. La decisión terapéutica depende del grado de conminución de la fractura, de su estabilidad y de la afectación articular.

© 2010 SECOT. Publicado por Elsevier España, S.L. Todos los derechos reservados.

## Introduction

Fractures of the hamate bone are quite rare, constituting about 2% of all carpal fractures.<sup>1,2</sup> Owing to the rise in popularity of racquet and bat sports, there has been an increase in the incidence of type I fractures.<sup>1,3-6</sup>

They are classified as type I when they involve the bone's hook and type II when they involve its body.<sup>2</sup> Type II fractures are usually caused by direct trauma and are extremely rare—even more so when it is an isolated fracture, for it is difficult to injure the hamate without affecting the other carpal bones.<sup>2</sup>

Besides being a rare injury, it can be difficult to diagnose because patients usually put off going to the doctor, and the physical examination is usually non-specific, sometimes even painless. In Urgent Care, neurological and vascular examination accompanied by simple x-rays is essential; in

cases of diagnostic uncertainty, computerised tomography (CT) should be done.<sup>7-9</sup>

The choice between conservative and surgical treatment should be based on stability of the fracture<sup>5,10,11</sup> and on joint involvement.

We present a clinical case of an isolated fracture of the body of the hamate bone—an injury with an uncertain prognosis due, in part, to the lack of information in the literature on this subject.

## Clinical case

This was a 24-year-old patient who came to Urgent Care 48 hours after suffering direct trauma to the left hand caused by the impact of its ulnar aspect against a door.

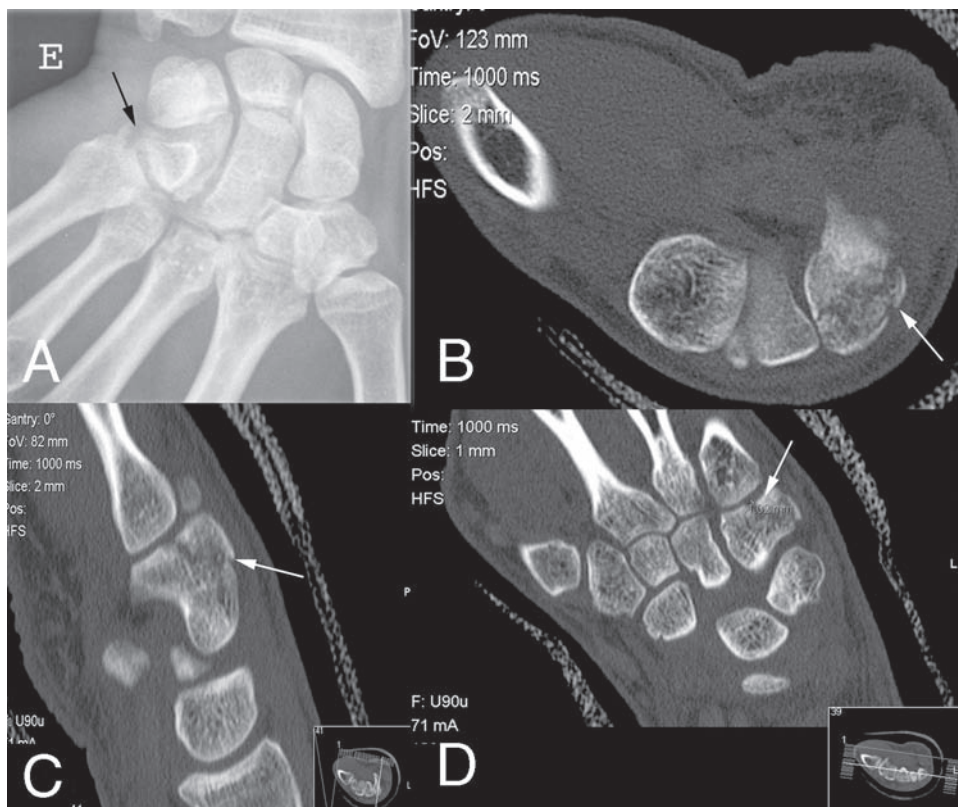


Figure 1 A) Initial x-ray with isolated fracture of the body of the hamate. B-D) Follow-up CT of the fracture at 1 week.

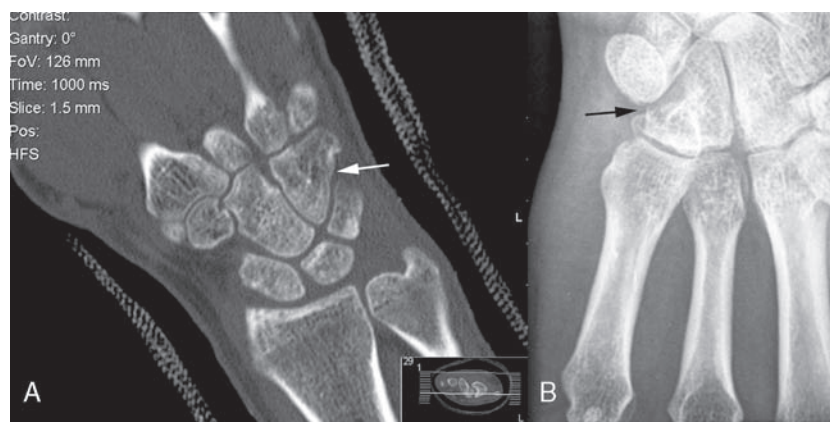


Figure 2 A) Follow-up CT at 8 weeks. B) Follow-up x-ray at 16 weeks.

Physical examination revealed mild oedema in the carpal area and diffuse pain in the hand, which increased with ulnar deviation movements.

On simple x-rays (fig. 1A), there was evidence of an isolated fracture of the body of the hamate.

In view of the main bone fragment's small size and very slight displacement, it was decided to initiate conservative treatment using a dorsal plaster splint for 1 week to control the oedema.

CT was done 1 week later (fig. 1, B-D), which showed a slight displacement of the fracture. It was decided to continue with conservative treatment, switching to a forearm cast.

On follow-up x-ray at 6 weeks, there was evidence of further displacement. Another follow-up CT done at 8 weeks (fig. 2A) showed that the fracture callus was sufficient to change the immobilisation back to a dorsal plaster splint for another 2 months.

Patient was subsequently started on in-home rehabilitation exercises, and a full recovery of wrist mobility and grip strength was achieved after 4 weeks.

X-rays were taken at the 16-week follow-up (fig. 2B), which showed complete recovery with no joint step-off. At 2 years, the patient remains asymptomatic.

## Discussion

Our patient presented with a type II fracture of the hamate with no associated injuries, which is extremely rare,<sup>1,2</sup> and there are scant references in the literature on this subject. The difficulty in diagnosing these fractures means they are easily underdiagnosed, with the risk of sequelae attendant upon a fracture with joint involvement being left untreated.

The various treatment options remain under discussion.<sup>5,10,11</sup> In our patient's case, despite the joint involvement, comminution of the fracture advised against both open reduction with osteosynthesis and fixation via percutaneous pins.

It is important that this type of fracture come to mind when the hand has suffered direct trauma. CT is recommended to properly characterize the fracture and evaluate the commonly associated injuries. The choice of

treatment depends on the degree of fracture comminution, fracture stability, and joint involvement.

## Protection of human and animal subjects

The authors declare that no experiments were performed on humans or animals for this investigation.

## Confidentiality of data

The authors will declare that they have followed the protocols of their work centre on the publication of patient data and that all the patients included in the study have received sufficient information and have given their informed consent in writing to participate in that study.

## Right to privacy and informed consent

The authors declare that no patient data appears in this article.

## Evidence level

Evidence level V.

## References

1. Rockwood and Green's fractures in adults. 6th ed. Philadelphia, Pa: Lippincott Williams & Wilkins, 2006.
2. Lister G. The Hand: Diagnosis and Indications. 3rd ed. Philadelphia, Pa: Churchill Livingstone; 1993. p. 88-92.
3. Hirano K, Inoue G. Classification and treatment of hamate fractures. *Hand Surg.* 2005;10:151-7.
4. Guha AR, Marynissen H. Stress fracture of the hook of the hamate. *Br J Sports Med.* 2002;36:224-5.
5. Boulas HJ, Milek MA. Hook of the hamate fractures. Diagnosis, treatment, and complications. *Orthop Rev.* 1990;19:518-29.
6. Bishop AT, Beckenbaugh RD. Fracture of the hamate hook. *J Hand Surg [Am].* 1988;13:135-9.

7. Failla JM. Hook of hamate vascularity: vulnerability to osteonecrosis and nonunion. *J Hand Surg [Am]*. 1993;18:1075-9.
8. Welling RD, Jacobson JA, Jamadar DA, Chong S, Caoili EM, Jebson PJ. MDCT and radiography of wrist fractures: radiographic sensitivity and fracture patterns. *AJR Am J Roentgenol*. 2008;190:10-6.
9. Andresen R, Radmer S, Sparmann M, Bogusch G, Banzer D. Imaging of hamate bone fractures in conventional X-rays and high-resolution computed tomography. An in vitro study. *Invest Radiol*. 1999;34:46-50.
10. Scheufler O, Andresen R, Radmer S, Erdmann D, Exner K, Germann G. Hook of hamate fractures: critical evaluation of different therapeutic procedures. *Plast Reconstr Surg*. 2005;115:488-97.
11. Gutiérrez Carbonell P, Cebrián Gómez R, Sánchez Candell F. Fractura de la apofisis unciforme del hueso ganchoso. *Rev Ortop Traum*. 1996;40:47-50.