

■ IMAGES IN OTORRHINOLARYNGOLOGY

Laryngeal Chondronecrosis Following Radiotherapy and Concurrent Chemotherapy

Mónica Hernando,^a Ana Hernando,^b and Julia Calzas^c

^aServicio de Otorrinolaringología, Hospital de Fuenlabrada, Madrid, Spain

^bServicio de Neurorradiología, Hospital de Fuenlabrada, Madrid, Spain

^cServicio de Oncología, Hospital de Fuenlabrada, Madrid, Spain

Laryngeal chondronecrosis is one of the main complications of radiation therapy in the treatment of cancer of the larynx. The illustrations provided show a chondronecrosis of the thyroid cartilage following concurrent radiation therapy and chemotherapy. Figure 1 (an axial helicoidal computed tomography with collimation of 2.5 after contrast, taken 1 month after the radiation therapy) shows fragmentation of the thyroid cartilage with a “moth-eaten” appearance, presence of air bubbles in the anterior commissure, oedema of the prelaryngeal soft tissues, and sclerosis of the arytenoid cartilages, all signs characterizing chondroradionecrosis, although they may also be produced by a tumour. Figure 2, taken 4 months later, shows a clear progression with absence of the anterior portion of the thyroid cartilage: only the upper and lower apophyses and the posterior third of the surfaces remain. Figure 3 shows a 3-dimensional reconstruction of the same tomography.

This kind of complication generally occurs between 3 and 12 months after finishing treatment. Classically, the arytenoid is the cartilage most frequently involved and many predisposing factors have been identified: radiation dosage, associated chemotherapy, poor general health, infiltration of the cartilage by the tumour, surgical manipulations after radiation therapy, etc. Chandler’s classification for the staging of the degree of laryngeal necrosis after radiation is very useful for therapeutic guidance. Low grade radionecroses (Chandler I and II) have a good response to conservative treatment, including humidification, corticosteroid treatment, and antibiotic therapy.

In degrees III and IV, the current proposal is to treat with hyperbaric oxygen, in view of the encouraging results of recent studies.

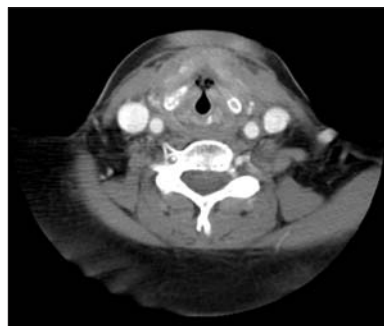


Figure 1. Computed tomography taken 1 month after conclusion of the protocol for concurrent radiation therapy and chemotherapy.

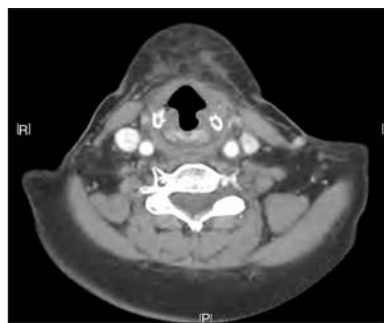


Figure 2. Computed tomography taken 4 months after conclusion of the protocol for concurrent radiation therapy and chemotherapy.

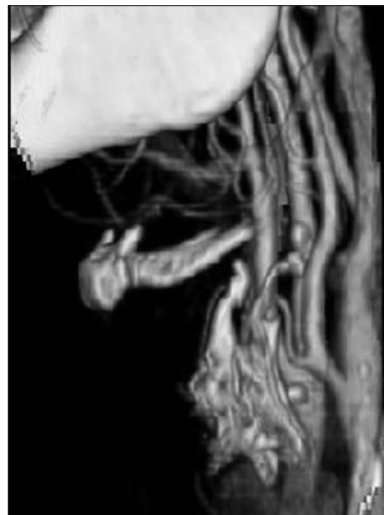

Figure 3. Three-dimensional reconstruction of the computed tomography taken 4 months after conclusion of the treatment protocol.

Correspondence: Dra. M. Hernando.
Unidad de Otorrinolaringología. Hospital de Fuenlabrada.
Camino del Molino, 2. 28942 Fuenlabrada. Madrid. España.
E-mail: monicahernandoc@hotmail.com

Received October 8, 2007.

Accepted for publication November 22, 2007.