

Servicio de Neumología, Hospital Clínico Universitario, Valencia, España

\* Autor para correspondencia.

Correo electrónico: [mulet.alba@gmail.com](mailto:mulet.alba@gmail.com) (A. Mulet).

<https://doi.org/10.1016/j.opresp.2020.08.002>  
2659-6636/

© 2020 Sociedad Española de Neumología y Cirugía Torácica (SEPAR). Publicado por Elsevier España, S.L.U. Este es un artículo Open Access bajo la licencia CC BY-NC-ND (<http://creativecommons.org/licenses/by-nc-nd/4.0/>).

## Síndrome torácico agudo, una enfermedad progresiva no reconocida



### Acute Chest Syndrome: An Unrecognized Progressive Condition

Dear Editor:

The authors describe a case of an acute chest syndrome (ACS) in whom fast recognition of the diagnosis and fast referral to the Intensive Care Unit (ICU) with early institution of exchange transfusion (ExT) were fundamental to avoid the need for invasive mechanical ventilation (IMV) and clinical worsening.

A 26-year-old black man with sickle cell disease (SCD, homozygous) on regular treatment with hydroxyurea presented to the emergency department with a worsening 5-day pleuritic chest pain of sudden onset and nonproductive cough. The physical examination was normal. Laboratory tests revealed hemoglobin (Hb) 10.4 g/dL (his basal), normal platelet count ( $307 \times 10^9/L$ ), leukocytosis ( $16.26 \times 10^9/L$ ) and C-reactive protein (CRP) 1.8 mg/dL. Chest radiography (CxR) showed no consolidation (Fig. 1A). He was treated with intravenous (IV) hydration, paracetamol, diclofenac, tramadol and morphine 20 mg with no control of pain. With the diagnosis of vaso-occlusive crisis, he was admitted in Internal Medicine ward. He maintained IV hydration, IV opioids and antibiotic therapy (AB) was started with amoxicillin/clavulanic acid 1.2 g *tid*. Within 72 h the patient showed a progressive clinical worsening with fever ( $38.5^\circ C$ ), uncontrolled chest pain with perfusion of morphine, purulent sputum, dyspnea, type I respiratory failure ( $FiO_2$  40% by venturi mask,  $PaO_2/FiO_2 = 217$  mmHg), CRP 29.1 mg/dL, decrease in Hb (7.5 g/dL, HbS 74%) with hemolysis (LDH 2299 U/L, total bilirubin 5.51 mg/dL, direct bilirubin 2.04 mg/dL), thrombocytopenia ( $118 \times 10^9/L$ ) and new bilateral pulmonary infiltration on CxR (Fig. 1B). With the diagnosis of ACS he was transferred to the ICU where he underwent two ExT with removal of 450 cc of blood from internal jugular vein catheter and blood replacement after with good clinical tolerance. Within 24 h HbS reduced to 58.9% (Hb 8.8 g/dL) with improvement of chest pain and respiratory failure ( $FiO_2$  40% by venturi mask,  $PaO_2/FiO_2 = 300$  mmHg). The  $FiO_2$  was progressively reduced, IV hydration and pain control were maintained and AB was switched to piperacilin/tazobactam 4.5 g q6 h and azithromycin 500 mg once daily. Blood cultures and urine antigen tests were negative. *Haemophilus influenzae* was isolated from sputum culture.

The clinical, laboratory (Hb 9.4 g/dL, HbS 54.9%, LDH 866 U/L, total bilirubin 0.98 mg/dL, direct bilirubin 0.58 mg/dL, platelets  $303 \times 10^9/L$ , CRP 4.57) and radiological courses were favorable (Fig. 1C). He was discharged after completing the AB.

SCD is a genetic disorder affecting Hb caused by a single mutation in the gene encoding the  $\beta$ -globin chain which forms HbS. The homozygous form is the most common form.<sup>1</sup> HbS is less soluble than normal Hb. On desoxygenation it polymerizes within the cell inducing a sickle shape of red blood cells (RBC). Their shorter lifespan promotes hemolysis within the vessels and they occlude small and sometimes larger vessels causing vaso-occlusive events responsible for acute episodes of severe pain, stroke, avascular necrosis, kidney, hepato-biliary and pulmonary complications.<sup>1</sup>

ACS is a distinctive complication and the leading cause of death of SCD.<sup>2</sup> ACS is characterized by new pulmonary infiltrate in CxR consistent with alveolar consolidation plus either cough, fever, hypoxia, chest pain or dyspnea.

Our patient met the criteria for the diagnosis but with late radiologic findings. In fact, most patients are admitted with vaso-occlusive crises with no radiographic and clinical symptoms and develop ACS after a few days.<sup>2,3</sup> A single physical examination or radiograph may not be adequate for early diagnosis. Therefore it should be strongly suspected when pulmonary symptoms and signs occur even with normal CxR findings specially in an isolated episode of vaso-occlusive crisis.

The different causes of ACS may coexist progressing to a common final pathway of reduced ventilation with hypoxia and increased sickling. One of them is pulmonary infection caused most frequently by *Chlamydia*, *Mycoplasma* and viral infections.<sup>2</sup> On the other hand, severe vaso-occlusive crisis of multiple bones can cause fat embolism with pulmonary vascular obstruction and pulmonary infarction. When it affects the thorax may cause regional alveolar hypoventilation.<sup>4,5</sup>

ACS can rapidly progress to severe respiratory failure within 24 h and severe hypoxia is a predictor of poor outcome.<sup>6</sup> Radiographic evidence of extensive lobar involvement and platelet count inferior to  $200\,000/mm^3$  at diagnosis were found to be as well independent predictors of respiratory failure.<sup>3</sup> Although no hemodynamic impairment was reported in the patient, the occurrence of shock

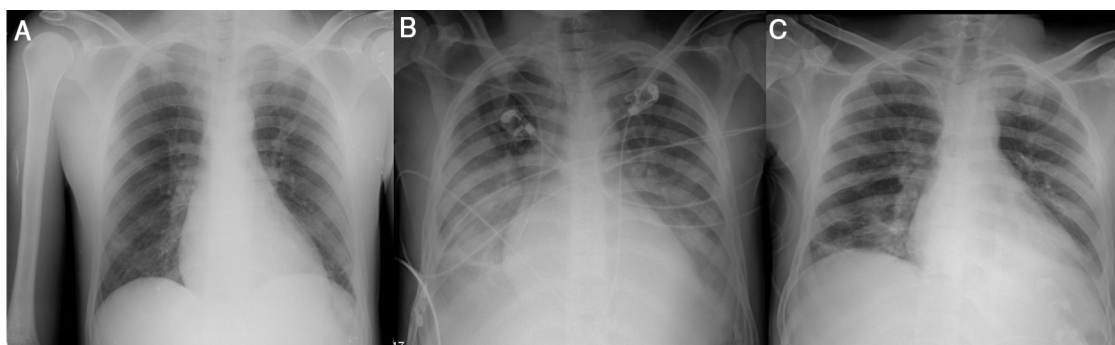


Fig. 1. Evolution of radiological course. CxR in emergency department admission (A), on ICU admission (B) and at discharge (C).

is not uncommon. Thus vigilance should be maintained closely for early treatment.

The aim of treatment is to prevent or reverse acute respiratory failure. The mainstays of management are pain control, rehydration, oxygenation with close monitoring for worsening respiratory failure with possibility of invasive mechanical ventilation (IMV) and treatment of any identifiable precipitating cause. The clinical presentation is similar whether due to infectious or non-infectious causes whereby empirical AB should be initiated with coverage for atypical bacteria. Adequate pain control usually requires initially high doses of opiates. IV hydration is preferred when patient is not able to drink adequate amounts aiming for 3–4 l a day. However, it should be taken carefully to not cause fluid overload which will exacerbate lung injury.

A simple transfusion or an ExT with removal of the patient's own blood and transfusing blood cause improvements in clinical and radiologic outcomes in the hypoxic patient.<sup>7</sup> Yet ExT seems to be more beneficial in severe clinical features, namely worsening hypoxia and dyspnea, decreasing Hb, multilobar disease and neurological complications.<sup>6</sup> ExT is a potentially life-saving procedure that allows improvement of anemia by replacing sickle cells without increasing blood viscosity and tissue oxygenation whilst reducing microvascular sickling. The target Hb should be 10–11 g/dL<sup>7</sup> but there is no evidence for an optimal volume of RBC exchange and/or HbS% target. ExT can be done manually with minimal equipment in ICU. In our patient, the amount of RBC to be exchanged was decided based on the clinical response to the treatment.

The fast clinical's deterioration and the delayed admission to the ICU are responsible to ACS as the leading mortality cause of SCD.<sup>4</sup> Therefore we want to alert the clinicians to maintain tight clinical vigilance in these patients for early recognition of ACS as potential complex and near-fatal condition. The fast ICU referral, even if no organ failure is present, with appropriate therapeutic modalities prevents as well the need of IMV and its associated complications.

## Conflicts of interest

The authors have no conflicts of interest to declare.

## Bibliografía

- Fortin PM, Hopewell S, Estcourt LJ. Red blood cell transfusion to treat or prevent complications in sickle cell disease: an overview of Cochrane reviews (Review). *Cochrane Database Syst Rev*. 2016; 2016, pii: CD012082.
- Mak V, Davies SC. The pulmonary physician in critical care. *Illustrative case 6: acute chest syndrome of sickle cell anaemia*. *Thorax*. 2003;58:726–8.
- Vichinsky EP, Neumayr LD, Earles AN, Williams R, Lennette E, Dean D, et al. Causes and outcomes of the acute chest syndrome in sickle cell disease. *N Engl J Med*. 2000;342:1855–65.
- Cecchini J, Fartoukh M. Sickle cell disease in the ICU. *Curr Opin Crit Care*. 2015;21:569–75.
- Farooq S, Omar M, Salzman G. Acute chest syndrome in sickle cell disease. *Hosp Pract*. 2018;46:144–51.
- Howard J, Hart N, Roberts-Harewood M, Cummins M, Awogbade M, Davis B. Guideline on the management of acute chest syndrome in sickle cell disease. *Br J Haematol*. 2015;169:492–505.
- Howard J. Sickle cell disease: when and how to transfuse. *Hematology. American Society Hematology. Educ Prog*. 2016;625–31, 2016.

Marta Freixa<sup>a,\*</sup>, Glória Nunes da Silva<sup>a</sup>,  
Fernanda Paula Santos<sup>b</sup>, Filipe Froes<sup>b</sup>

<sup>a</sup> Internal Medicine Department, Hospital Pulido Valente – CHULN, Lisbon, Portugal

<sup>b</sup> Intensive Care Unit, Hospital Pulido Valente – CHULN, Lisbon, Portugal

Corresponding author.

E-mail address: [marta.freixa90@gmail.com](mailto:marta.freixa90@gmail.com) (M. Freixa).

<https://doi.org/10.1016/j.opresp.2020.08.004>  
2659-6636/

© 2020 Sociedad Española de Neumología y Cirugía Torácica (SEPAR). Published by Elsevier España, S.L.U. This is an open access article under the CC BY-NC-ND license (<http://creativecommons.org/licenses/by-nc-nd/4.0/>).

## Un camino hacia el futuro más esperanzador en los pacientes con linfangioleiomiomatosis: sirolimus



### A More Hopeful Path to the Future in Lymphangioleiomyomatosis Patients: Sirolimus

Estimado Director:

La linfangioleiomiomatosis (LAM) es una enfermedad pulmonar infrecuente, quística, que puede progresar causando fracaso respiratorio. Se puede considerar una neoplasia de tejidos blandos, por la proliferación de células parecidas a las del músculo liso en las vías aéreas, paredes de vasos linfáticos pulmonares o vénulas. Podemos distinguir 2 formas de presentación: asociada a esclerosis tuberosa (TSC-LAM) las células LAM presentan mutaciones de pérdida de función de los genes supresores tumorales *tuberous sclerosis complex*<sup>1,2</sup> (TSC1/2), mostrando una activación anómala de la vía de señalización mediada por *mechanistic target of rapamycin* (mTOR); o esporádica (S-LAM), donde solo se presenta en mujeres<sup>1,2</sup>. Existen casos en los que se acompaña de afectación extrapulmonar, por ejemplo, en forma de angiomiolipomas o linfangioleiomiomas a nivel abdominal. En los últimos años se ha empezado a utilizar un tratamiento con un inhibidor de mTOR, como es el sirolimus, comprobándose su eficacia y seguridad a largo plazo<sup>3</sup>.

Presentamos el caso de una mujer de 37 años no fumadora, diagnosticada de atresia esofágica y fístula traqueoesofágica inter-

venida en su infancia y reintervenida a los 19 años, asma bronquial alérgica, deficiencia de alfa-1 antitripsina genotipo Pi\*SS y bronquiectasias en lóbulo medio e inferior izquierdo, con episodios de bronconeumonías de repetición aspirativas. A la exploración física se aprecia una auscultación respiratoria con hipofonesis y crepitantes finos en base izquierda, siendo el resto normal. Entre las pruebas complementarias destaca un moderado descenso de la alfa-1 antitripsina (88 mg/dl; 116-232 mg/dl), con el resto de parámetros analíticos, incluyendo inmunoglobulinas séricas y sus subclases, normales.

Tras la visualización de la tomografía computarizada de tórax de alta resolución, dada la sospecha diagnóstica, se solicitaron niveles plasmáticos de factor de crecimiento vascular endotelial (VEGF), que fue de 27,4 (normal < 128,9 pg/ml), sin volver a repetirse su determinación durante el seguimiento debido a la normalidad en el parámetro; también se realizó un estudio genético con secuenciación de los genes TSC1 y TSC2, resultando negativo. Se le realizó endoscopia respiratoria para revisar la fístula y un lavado broncoalveolar, sin mostrar aislamientos microbiológicos. En el estudio funcional respiratorio se aprecia una obstrucción leve al flujo aéreo, sin respuesta a prueba broncodilatadora, y moderada afectación de la difusión, siendo normales los volúmenes pulmonares. Sus valores prebroncodilatación absolutos y porcentajes con respecto a sus teóricos son: capacidad vital forzada (FVC)= 3.100 ml-98%; volumen espirado máximo en el primer segundo de la espiración forzada (FEV1)= 2.140 ml-79%; FEV1/FVC= 0,69; flujo espiratorio forzado entre el 25-75% de la capacidad vital forzada = 1.270 ml/s-