



# Enfermedades Infecciosas y Microbiología Clínica

www.elsevier.es/eimc



Scientific letter

## Fosfomicin: Salt is what really matters



### Fosfomicina: La sal es lo que de verdad importa

Dear Editor,

Fosfomicin, discovered in 1969 by a Spanish scientist, is a broad-spectrum bactericidal antibiotic that interferes with both gram-positive and negative cell wall synthesis. There are three different formulations depending on the salt, which it is formulated with: On the one hand calcium and tromethamine/trometamol for oral treatment and, on the other hand, disodium for intravenous treatment. Oral fosfomicin is mainly used for urinary tract infection (UTI) in women, mainly caused by *Escherichia coli* and *Enterococcus faecalis*.<sup>1</sup> The two oral formulas are also used in recurrent UTI prophylaxis. The question is, whether both are equally appropriate for prophylaxis.

In February 2020 at the Alto Deba health organization (67,000 inhabitants) in Gipuzkoa (Spain), there were 21 patients with calcium fosfomicin (FC) with a prophylactic dose: 500 mg/24–72 h and 80 patients with fosfomicin trometamol (FT): 3 g every 10 days, 15 days or weekly. Different national and international guidelines about recurrent UTI were reviewed without reference to FC. In fact, according to the Martindale Pharmacotherapeutica Consultation Guide, FC is available or has been available in these countries: Spain, Italy, Mexico, Argentina, Japan and China.<sup>2</sup> In Spain, the Fisterra guideline takes FC into account.

The recommended dose in the Fisterra guide (last access: 07/05/2020) for UTI prophylaxis is FC 500 mg/day or FT 3 g every 10 days. In reviewing literature consulted<sup>3–4</sup> we notice that the authors refer only to the FT.

With the term “fosfomicin tromethamine OR trometamol” appear in PubMed (last access: 12/05/2020): 7740 articles, of which those published in the last 10 years are: 2413. “fosfomicin calcium”: 54 results and limited to the last 10 years: 16.

A study in 2016 analyzed the kinetics of both fosfomicin formulations. The oral bioavailability of FT is 34–58%, with absorption mainly in the small intestine. FT is absorbed 6 times more than the FC during the first 2 h and 3–4 times more in the first 12 h, the explanation may be because calcium salt is hydrolyzed and inactivated by gastric juices.<sup>5</sup> Other studies compare the bioavailability of FT vs FC (40% vs 12%).<sup>6,7</sup> Concentrations of a single dose of FT of 2 g are 2–4 times higher than a single dose of 3 g of FC.<sup>8</sup>

The justification for the usage of the single dose of FT is based on its pharmacokinetics. After administration of a single dose, a maximum concentration of 22–32 g/ml is reached in about 2 hours with an elimination half-life of 2.4–7.3 h and an area under the curve of 145–228 g/ml h. This achieves a high urinary concentration (1000–4000 g/ml) by remaining >100 g/ml for 30–48 h.<sup>7</sup>

Taking into account the pharmacokinetic differences between the two salts, some author<sup>6</sup> points out that they should not be treated as equivalent formulations. In addition, most studies of prophylaxis or treatment in UTI are based on trometamol salt and there is only one descriptive study<sup>9</sup> noticing the effectiveness of FC in the treatment of uncomplicated cystitis. However, according to the comparative study of FT 2 g versus FC 3 g<sup>8</sup> it seems logical to think that the calcium formulation of 500 mg is not pharmacokinetically adequate for establishing doses of 500 mg/day in prophylaxis. There should be a clear distinction in the clinical usefulness of both formulations. In fact, recently, in acute and chronic prostatitis, it is perceptible that, in enterobacteria resistant to fluorquinolones and cotrimoxazole, favorable results have been obtained with the use of FT 3 g/day for one week, followed by 3 g to alternate days for 6 weeks.<sup>10</sup>

Therefore, the absence on literature of use of FC in prophylaxis and its different pharmacokinetics compared to trometamol salt would justify the exclusion of FC from the protocol of antibiotic prophylaxis in recurrent UTI and, possibly, its progressive disappearance from routine clinical practice also in the treatment of UTI. After all, in terms of fosfomicins, salt is what really matters.

## Funding

This manuscript is not funded by anyone.

## Conflict of interest

None.

## References

- Candel FJ, Matesanz David M, Barberán J. New perspectives for reassessing fosfomicin: applicability in current clinical practice. *Rev Esp Quimioter*. 2019;32 Suppl. 1:1–7.
- The Royal Pharmaceutical Society of Great Britain. Martindale. The Complete Drug Reference. Available from: <https://www.micromedexsolutions.com/micromedex2/librarian/CS/1E7056/ND.PR/evidencexpert/ND.P/evidencexpert/DUPLICATIONSHIELDSYNC/BC3E71/ND.PG/evidencexpert/ND.B/evidencexpert/ND.AppProduct/evidencexpert/ND.T/evidencexpert/PFActionId/evidencexpert.IntermediateToDocumentLink?docId=5026-a&contentSetId=30&title=Fosfomicin&servicesTitle=Fosfomicin> [accessed 29.05.20].
- National Institute for Health and Care Excellence (NICE). Urinary tract infection (recurrent): antimicrobial prescribing. NICE guideline [NG112]; 2018. Available from: <https://www.nice.org.uk/guidance/ng112>.
- Bonkat B, Pickard R, Bartoletti R, Cai T, Bruyère F, Geerlings SE, et al. Urological Infections. EAU (European Association of Urology); 2018. Available from: <http://uroweb.org/guideline/urological-infections/#3>
- Falagas ME, Vouloumanou EK, Samonis G, Vardakas KZ. Fosfomicin. *Clin Microbiol Rev*. 2016;29:321–47.
- Iwata K. Are all fosfomicins alike? *J Infect Chemother*. 2016;22:724.
- Sastry S, Doi Y. Fosfomicin: resurgence of an old companion. *J Infect Chemother*. 2016;22:273–80.
- Borsa F, Leroy A, Fillastre JP, Godin M, Moulin B. Comparative pharmacokinetics of tromethamine fosfomicin and calcium fosfomicin

- in young and elderly adults. *Antimicrob Agents Chemother.* 1988;32:938–41.
9. Matsumoto T, Muratani T, Nakahama C, Tomono K. Clinical effects of 2 days of treatment by fosfomycin calcium for acute uncomplicated cystitis in women. *J Infect Chemother.* 2011;17:80–6.
10. Zhanel GG, Zhanel MA, Karlowsky JA. Oral fosfomycin for the treatment of acute and chronic bacterial prostatitis caused by multidrug-resistant *Escherichia coli*. *Can J Infect Dis Med Microbiol.* 2018;2018:1404813.

Lorea Arteche-Eguizabal<sup>a,\*</sup>, Saioa Domingo-Echaburu<sup>a</sup>,  
Ainhoa Urrutia-Losada<sup>a</sup>, Santiago Grau-Cerrato<sup>b</sup>

<sup>a</sup> Pharmacy Department, Hospital Alto Deba, Arrasate-Mondragón, Gipuzkoa, Spain

<sup>b</sup> Pharmacy Department, Hospital del Mar, Barcelona, Spain

\* Corresponding author.

E-mail address: lorea.artecheguizabal@osakidetza.eus (L. Arteche-Eguizabal).

<https://doi.org/10.1016/j.eimc.2020.06.006>

0213-005X/ © 2020 Elsevier España, S.L.U. and Sociedad Española de Enfermedades Infecciosas y Microbiología Clínica. All rights reserved.

## ***Coxiella burnetii*-infected abdominal endovascular aortic stent graft in a kidney transplant recipient**



### ***Infección de stent endovascular aórtico-abdominal en un trasplantado renal por *Coxiella burnetii****

Q fever is caused by *Coxiella burnetii*, an intracellular Gram-negative bacterium that produces prolonged bacteriemia and represents great risk of persistent infections for patients with valve pathology or vascular defects.<sup>1</sup> This infection may have serious consequences in renal transplant recipients, especially if cardiovascular abnormalities are present.<sup>2</sup> We present the case of a renal transplant recipient with weight loss and malaise.

A 65-year-old patient, with a kidney transplant from 2011 with baseline serum creatinine around 1.15 mg/dl. He was receiving tacrolimus (levels around 5–7 ng/ml) and mycophenolic acid (180 mg/d) as immunosuppressive therapy. He also had an endovascular prosthesis for an abdominal aortic aneurysm from 2006 and referred several trips to Africa in the past 20 years. He was also the owner of a scrap dealing company in rural area of Castilla-La Mancha (Spain).

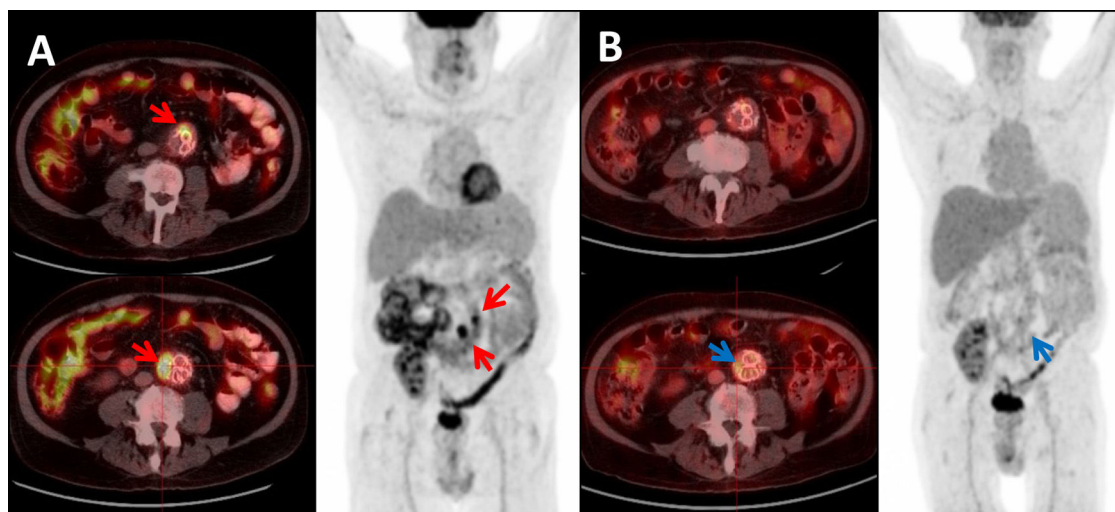
Since June 2018, he endorsed gradual onset of non-specific symptoms (malaise, persistent low grade fever and weakness), and a 10 kg weight loss in one year. The patient consulted on August 2019: laboratory examinations of previous 3 months revealed increased value of liver enzymes and C reactive protein (CRP). Multiple blood cultures were negative for bacteria and fungi. A fluorine

18-fluorodeoxyglucose positron emission tomography/computed tomography (18F-FDG PET/CT) was performed, showing aorto-iliac endovascular stent graft with heterogeneous content in aneurismatic sack and striation of the peri-aortic fat tissue, suggestive of peri-graft infectious process.

IgG anti-phase I and phase II antibodies for *C. burnetii* were reactive at titers of 1:8192 and 1:16,384 respectively, with later detection of *Coxiella burnetii* DNA in blood sample by polymerase chain reaction (PCR).

Diagnosis of chronic Q fever was confirmed and the patient began treatment with doxycycline 200 mg/d and hydrochloroquine (400 mg/24 h because of gastrointestinal symptoms). No surgical intervention was performed due to high risk of aneurism rupture and compromise of vascularization of kidney allograft. After a three-month follow up period, patient was asymptomatic, had gained weight and in the last serological tests, IgG anti-phase I and phase II antibodies titers were 1:2048 and 1:8192 respectively. A follow up PET/TC performed three months after initiation of antibiotic therapy, showed an evident decrease in metabolic activity in the aneurismatic aortic sack (Fig. 1). Unfortunately, three months later the patient passed away due to an aggressive intrahepatic cholangiocarcinoma, precluding us from providing long-term follow up information about the infection.

Chronic Q fever is associated with high morbidity and mortality if left untreated and is more common in elderly subjects and those who are immunosuppressed.<sup>3</sup> Diagnosis of Q fever relies on serology and IFA (indirect immunofluorescence assay). In acute infection, the phase II antibody response appears first and is higher



**Fig. 1.** 18F-FDG PET/CT showing: (A) Maximum intensity projection (MIP) and Axial-fused PET/CT images: two foci of high intensity FDG uptake in the aortic graft (SUVmax 17.79 and 9.46 respectively), consistent with infection of the graft (red arrows). (B) Same patient and same projections showing: significant decrease in FDG uptake after treatment (SUVmax 3.70 and 2.78 respectively) (blue arrows).