



Enfermedades Infecciosas y Microbiología Clínica

www.elsevier.es/eimc



Brief report

Organizing pneumonia secondary to influenza infection: Two case reports and a literature review

Andrea Nuñez-Conde^a, Ester Marquez-Algaba^b, Vicenç Falcó^b, Benito Almirante^b, Joaquin Burgos^{b,*}

^a Internal Medicine Department, University Hospital Vall d'Hebron, Universitat Autònoma de Barcelona, Barcelona, Spain

^b Infectious Diseases Department, University Hospital Vall d'Hebron, Universitat Autònoma de Barcelona, Barcelona, Spain

ARTICLE INFO

Article history:

Received 28 January 2019

Accepted 5 April 2019

Available online 22 May 2019

Keywords:

Cryptogenic organizing pneumonia
Secondary organizing pneumonia
Bronchiolitis obliterans organizing pneumonia

ABSTRACT

Background: Organizing pneumonia (OP) is a rare complication of influenza virus infection but scarce data are available. The recognition of this entity is important because require appropriate treatment.

Methods: We report two cases and perform a systematic review on PubMed database. Only cases with histological confirmation of OP and influenza virus positive laboratory test were included.

Results: We collected 16 patients. Median age was 52 year, 20% of patients were smokers and 43.8% had not any comorbidity. Influenza A virus infection was diagnosed in 75%. Clinical manifestation consisted on a respiratory deterioration with a median time of appearance of 14 days. Radiological pattern observed was ground-glass opacities with consolidations. Survival was observed in 12 patients (75%). All three patients who did not receive steroid treatment died.

Conclusion: Physicians must be aware that patients with influenza infection with a torpid course could be developing OP and prompt corticoid therapy should be instated.

© 2019 Elsevier España, S.L.U. and Sociedad Española de Enfermedades Infecciosas y Microbiología Clínica. All rights reserved.

Neumonía organizativa secundaria a infección por el virus de la gripe: comunicación de 2 casos y revisión de la literatura

RESUMEN

Antecedentes: La neumonía organizada (OP, por sus siglas en inglés) es una complicación poco frecuente de la gripe. El reconocimiento de esta entidad es importante porque requiere un tratamiento adecuado.

Métodos: Comunicamos 2 casos y realizamos una revisión sistemática en PubMed, incluyendo casos con confirmación histológica de OP y prueba de laboratorio positiva para gripe.

Resultados: Se recogieron 16 pacientes. La edad media fue de 52 años, el 20% eran fumadores y el 43,8% no tenían comorbilidades. El virus de la gripe A se identificó en el 75% de los casos. La presentación clínica consistió en un deterioro respiratorio, con una mediana de aparición de 14 días. El patrón radiológico más común fue opacidades en vidrio esmerilado con consolidaciones. Sobrevivieron 12 pacientes (75%). Los 3 pacientes que no recibieron tratamiento esteroideo murieron.

Conclusión: Los clínicos deben tener en cuenta que los pacientes con gripe con un curso tórpido puedan estar desarrollando una OP.

© 2019 Elsevier España, S.L.U.

y Sociedad Española de Enfermedades Infecciosas y Microbiología Clínica. Todos los derechos reservados.

Palabras clave:

Neumonía organizativa citogenética
Neumonía organizativa secundaria
Bronquiolitis obliterante
Virus de la gripe

Introduction

The influenza virus is a known cause of acute respiratory illness that occurs in epidemics worldwide. The major complications of influenza virus infection (IVI) are secondary bacterial superinfection and viral influenza pneumonia.¹ These complications affect especially older patients and those with chronic diseases.²

* Corresponding author.

E-mail address: jburgos@vhebron.net (J. Burgos).

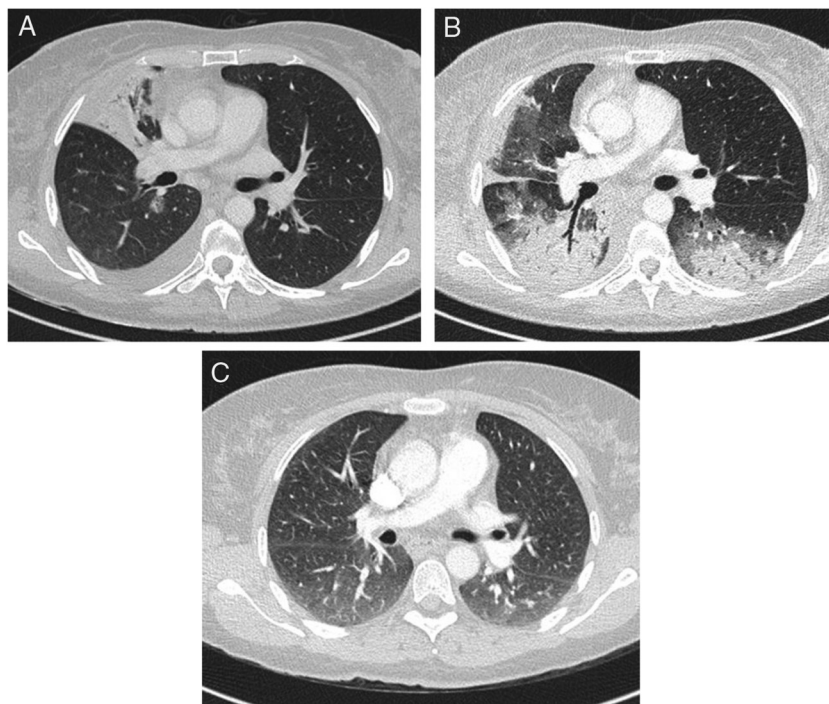


Fig. 1. Chest CT of patient 1: (A) day 0: consolidation in lower right lobe; (B) day 12: ground glass opacities plus consolidations in bilateral upper lobes; (C) day 110: almost complete resolution of consolidations.

Organizing pneumonia (OP) is an unusual interstitial lung disease that affects the distal bronchioles and alveoli, it is considered a nonspecific response to a lung injury.³ It can occur associated with connective tissue diseases, drugs, malignancy and bacterial or virus infections.⁴ Some authors reported that OP might occur as a rare complication after IVI. However, the differential diagnosis between secondary OP and other IVI complications, such as bacterial superinfection, it is difficult. Nevertheless, the diagnosis of secondary OP is important because requires specific therapy.

We report two cases of OP secondary to IVI and, because of the scarce data published about this complication, we carry out a review of published cases in the literature.

Material and methods

We report two cases of secondary OP diagnosed during the influenza outbreak of 2017–2018. A search on *PubMed* database was conducted to find other reported cases of secondary OP after IVI. The following keywords were used: “cryptogenic organizing-pneumonia”, “secondary organizing-pneumonia”, “bronchiolitis obliterans organizing-pneumonia;” and “influenza virus”. Only cases with histological confirmation of OP and personal history of IVI were included.

Results

Case 1

A 51-year-old white woman, who was a heavy smoker, was admitted to emergency department complaining of right pleuritic pain, fever, cough and flu-like symptoms. A chest X-ray showed consolidations in lower and medium pulmonary right lobes. Amoxicillin–clavulanic acid was initiated. She was also diagnosed of *influenza A* and oseltamivir was prescribed. Pneumococcal and *Legionella* urinary antigen test and blood and sputum culture

were negative. Despite treatment, the patient showed a progressive respiratory worsening with new onset left pleuritic pain. At day 12 after admission, a chest computed tomography (CT) revealed consolidations in lower right lobe in resolution, but also appearance of new bilateral consolidations with ground glass opacities in upper pulmonary lobes. Treatment with intravenous methylprednisolone was initiated (dosage 1 mg/kg/day). Bronchoscopy was performed, and no virulent pathogens were isolated. Transbronchial biopsy diagnosed OP. Notable clinical improvement after steroid therapy was noticed and the patient was discharged on day 36. After oral prednisone therapy was tapered, disease recurred and she required an increase corticosteroid dosage. After that, the patient evolved correctly.

Case 2

A 55-year-old white male, who was a smoker, with a history of aortic valve replacement, was admitted to hospital with fever, dyspnea, productive cough and flu-like symptoms. Chest X-ray showed bilateral infiltrates. Amoxicillin–clavulanic acid and azithromycin were initiated. The patient presented progressive deterioration with respiratory failure, requiring endotracheal intubation and admission into Intensive Care Unit. He was diagnosed with *influenza A* infection. Antimicrobial therapy was changed to cefotaxime plus azithromycin plus oseltamivir. No other pathogens were identified. Two weeks later the patient improved and extubation was possible. 27 days after admission, his pulmonary function deteriorated again. Chest-CT showed extensive ground-glass opacities and bilateral consolidations (Fig. 1). Bronchoscopy and transbronchial lung biopsy was performed. All cultures were negative. Treatment with methylprednisolone was initiated (dose 1 mg/kg/day) and a progressive improvement was noticed. Histological results of transbronchial biopsy were compatible with OP. The patient was discharged on day 36 and therapy with oral prednisone was tapered. No recurrence of illness was observed.

Table 1
Basal and clinical characteristics of patients with post-influenza organizing pneumonia.

Author (Ref)	Age	Sex	Smoker	History of lung pathology	Another comorbidities	Initial symptoms	Influenza	UCI	Bacterial infection	Initial treatment	Onset (days)	Radiologic findings	OP symptoms	Histology	Treatment	Outcome
Fujita J ⁴	38	Female	NS	No	No	Fever, flu symptoms	A	No	No	ATB + Zanamivir	NS	Bilateral consolidations	No improvement	TB	Steroid pulse	Resolution
Torrego A ⁵	55	Female	No	Intermittent asthma	No	Myalgia, cough, fever	A	No	No	ATB + Oseltamivir	30	Bilateral consolidations	Respiratory deterioration (RF)	TB	Steroids 0.75 mg/kg	Resolution
Cornejo R ⁶	52	Female	Yes	No	Osteoarthritis	Cough, fever, myalgia, pleuritic pain, dyspnea	A	Yes	No	ATB + Oseltamivir + steroids	10	GGO + bilateral consolidations	Respiratory deterioration (RF)	OLB	Steroids 500 mg/d 3d tapering 24w	Resolution
Cornejo R ⁶	36	Male	No	No	Type 2 diabetes	Influenza-like symptoms + dyspnea	A	Yes	No	ATB + Oseltamivir + steroids	21	GGO + bilateral consolidations	Respiratory deterioration	OLB	Steroids 500 mg/d 3d tapering 24w	Resolution
Marchiori E ⁷	52	Male	No	Yes (not specified)	No	Dyspnea, fever, cough	A	MV	No	Oseltamivir	15	GGO + bilateral consolidations	Respiratory deterioration	Necropsy	–	Death
Gómez A ⁸	44	Female	No	No	No	Fever, malaise, headache, myalgias	A	No	No	Oseltamivir	26	GGO + bilateral consolidation	Respiratory deterioration	TB	Steroids 1 mg/kg 4w → 0.5 mg/kg (oral) 6w	Resolution
Gómez A ⁸	60	Male	No	No	No	Fever, myalgias, arthralgia	A	No	No	Oseltamivir	21	GGO + bilateral consolidation	Respiratory deterioration	TB	Steroids 1 mg/kg 4w → 0.5 mg/kg (oral) 6w	Resolution
Otto C ⁹	66	Female	No	Usual interstitial pneumonia, double lung transplantation	No	Persistent cough	A	Yes	No	ATB + Oseltamivir	11	GGO + bilateral consolidations	Respiratory deterioration (RF)	TB	High-dose steroids	Death
Fujita J ¹⁰	97	Female	No	No	Type 2 diabetes	Low fever, fatigue	A	No	No	NS	12	NS	Respiratory deterioration (ARDS)	Necropsy	–	Death
Fujita J ¹⁰	37	Male	No	No	Obesity	Fever, productive cough	A	MV	No	ATB + Oseltamivir	7	NS	Respiratory deterioration (ARDS)	Necropsy	–	Death
Kwock W ¹¹	45	Female	No	No	No	Fever, dyspnea, productive cough	B	MV	No	ATB + Oseltamivir	28	GGO + bilateral lung cysts	Respiratory deterioration (RF)	TB	Steroids 0.5 mg/kg 8w	Resolution
Asai N ¹²	23	Female	No	No	No	Fever, sore throat, cough	B	No	No	ATB + Oseltamivir	7	GGO + bilateral consolidations	Respiratory deterioration (RF)	TB	Steroids 0.55 mg/kg 20w	Resolution
Anjana V ¹³	60	Female	No	No	No	Fever, chills, bilateral rales	A/B	No	No	NS	14	Bilateral infiltrates	Respiratory deterioration	TB	Steroids	Resolution
Anjana V ¹³	52	Male	No	No	No	Dyspnea	B	MV	<i>E. aerogenes</i>	ATB	14	Bilateral infiltrates	Respiratory deterioration (RF)	OLB	Steroids	Resolution
HUVH	51	Female	Yes	No	Breast cancer	Fever, pleuritic chest pain, cough	A	No	No	ATB + Oseltamivir	12	GGO + unilateral consolidations	No improvement	TB	Steroids 1 mg/g 15d → tapering 10w	Resolution
HUVH	55	Male	Yes	No	Atrial fibrillation, aortic valve replacement	Cough, dyspnea, fever, rhinorrhoea, myalgias	A	Yes	No	ATB + Oseltamivir	27	GGO + bilateral consolidations	Respiratory deterioration (RF)	TB	Steroids 1 mg/kg 6d → tapering 12w	Resolution

ATB: antibiotic treatment; ARDS: acute respiratory distress syndrome; GGO: ground glass opacities; HUVH: Hospital Universitari Vall d'Hebron; MV: mechanical ventilation; NS: not specified; OLB: open lung biopsy; RF: respiratory failure; TB: transbronchial biopsy; w: weeks; d: day.

Literature review

We identified a 14 cases of OP secondary to IVI which were reported in 10 publications.^{4–13} Data is summarized in Table 1.

The median age of patients was 52 years (range 25–97 years) and 62.5% were woman. Only 20% were smokers, 25% had lung disease and 56.3% had any other comorbidity. 43.75% of individuals were previously healthy. *Influenza A virus* was diagnosed in 75% of cases. Clinical manifestations of secondary OP consisted on a paradoxical respiratory deterioration with cough and dyspnea; 43.8% of them progressed to respiratory failure and 12.5% to acute respiratory distress. The median time of appearance OP symptoms/signs was 14 days (range 7–30 days). The most common radiological pattern observed was bilateral, peripheral, ground-glass opacities with consolidations on chest-CT. Almost all patients (81.3%) received steroid treatment, of those 92.3% survived and 7.7% died. All three patients who did not receive steroid treatment died.

Discussion

Post-influenza OP is a rare complication of IVI that has been described in few case reports.^{4–13} However, the diagnosis of secondary OP is important, because without appropriate treatment could be fatal. In this article we provide some information that could help clinicians to suspect and diagnose this entity.

The major complication of IVI is bacterial superinfection pneumonia, which occurs most frequently in older patients with underlying chronic diseases.¹⁴ Nevertheless, secondary OP affect especially healthy young adults. Cases of post-influenza OP reported in the literature presented with a median age of 50 years, and 50% of them had not any relevant comorbidity.

The time of presentation should be also taking into consideration. Whereas influenza pneumonia is diagnosed in days 4–5 after the first symptoms appear and bacterial superinfection in days 7–10,^{4,15} in 2/3 of cases reported, secondary OP occurred after two weeks of influenza infection manifestations appears. Moreover, in about a quarter of cases OP occurred later, 4 weeks after the diagnosis of flu.

The typical clinical presentation of OP consists on a sub-acute paradoxical pulmonary function deterioration with non-productive cough, dyspnea that can progress to respiratory failure and occasionally, fever.

One of the most relevant findings that can lead to the diagnosis of post-influenza OP are the images at the chest-CT. At imaging, the most typical pattern consists on multiple and bilateral ground glass opacities and pulmonary consolidations, with peribronchovascular and subpleural distribution.

Secondary OP remains a diagnosis of exclusion. When the most common diagnoses have been ruled out, more invasive diagnostic procedures should be conducted if the patient's condition allows it. Transbronchial biopsy with anatomopathological examination of the samples obtained gives the definitive diagnosis, although that is only possible in a minority of patients. Histologically, Marchiori et al. correlated pathologic findings with CT images. They found that the areas of consolidation corresponded to alveoli filled with edema fluid, inflammatory exudate or hemorrhage.⁷ They also found that the ground-glass pattern reflected the alveolar septal thickening. In contrast, lung tissue from individuals affected of IVI showed as predominant features diffuse alveolar damage and alveolar hemorrhage.¹⁶

Corticosteroids are the cornerstone in the management of this entity. All post-influenza OP cases were resolved after

corticosteroid therapy, except for the patient with personal history of lung transplantation.⁹ All three patients who did not received corticosteroids died.^{6,9} In one of the studies found, a patient started steroid therapy after 84 days of initial symptoms and despite improvement, she suffered from secondary extensive lung fibrosis and residual dyspnea.¹¹ So, early corticosteroid treatment should be considered in cases of suspicions OP thus seems to improve outcome and avoid further complications. Most clinicians use moderate doses for prolonged periods of at least 3–6 months, but relapse is common when corticosteroids dosage is tapered off.

In conclusion, physicians must be aware that some patients with IVI, either *influenza A* or *B*, and a torpid clinical course could be developing OP. The presentation in healthy young adults 2–4 weeks after the onset of the symptoms, and a new appearance of consolidations or/and ground glass opacities on CT may suggest this diagnosis. In those scenarios, corticosteroids are the treatment of choice. This entity should be considered in the list of possible complications for patients with influenza who do not improve or have a clinical deterioration.¹

Conflict of interest

The authors declare no conflict of interests.

References

1. Uyeki TM, Bernstein HH, Bradley JS, Englund JA, File TM, Fry AM, et al. Clinical Practice Guidelines by the Infectious Diseases Society of America: 2018 update on diagnosis, treatment, chemoprophylaxis, and institutional outbreak management of seasonal influenza. *Clin Infect Dis.* 2019;68:e1–47.
2. Grohskopf LA, Sokolow LZ, Broder KR, Walter EB, Fry AM, Jernigan DB. Prevention and control of seasonal influenza with vaccines: recommendations of the advisory committee on immunization practices—United States, 2018–19 Influenza Season. *MMWR Recomm Rep.* 2018;67:1–20.
3. Cordier JF. Cryptogenic organizing pneumonia. *Eur Respir J.* 2006;28:422.
4. Fujita J, Bandoh S, Yamaguchi M, Higa F, Tateyama M. Chest CT findings of influenza virus-associated pneumonia in 12 adult patients. *Influenza Other Respir Viruses.* 2007;1:183–7.
5. Torrego A, Pajares V, Mola A, Lerma E, Franquet T. Influenza A (H1N1) organising pneumonia. *BMJ Case Rep.* 2010;27:2010.
6. Cornejo R, Llanos O, Fernández C, Carlos Díaz J, Cardemil G, Salguero J, et al. Organizing pneumonia in patients with severe respiratory failure due to novel A (H1N1) influenza. *BMJ Case Rep.* 2010;21:2010.
7. Marchiori E, Zanetti G, Fontes CA, Santos ML, Valiante PM, Mano CM, et al. Influenza A (H1N1) virus-associated pneumonia: high-resolution computed tomography–pathologic correlation. *Eur J Radiol.* 2011;80:e500–4.
8. Gómez-Gómez A, Martínez-Martínez R, Gotway MB. Organizing pneumonia associated with swine-origin influenza A H1N1 2009 viral infection. *AJR Am J Roentgenol.* 2011;196:W103–4.
9. Otto C, Huzly D, Kemna L, Hüttel A, Benk C, Rieg S, et al. Acute fibrinous and organizing pneumonia associated with influenza A/H1N1 pneumonia after lung transplantation. *BMC Pulm Med.* 2013;13:30.
10. Fujita J, Ohtsuki Y, Higa H, Azuma M, Yoshinouchi T, Haranaga S, et al. Clinicopathological findings of four cases of pure influenza virus A pneumonia. *Intern Med.* 2014;53:1333–42 [Epub 15.06.14].
11. Kwok WC, Lam SH, Wong MP, Ip MS, Lam DC. Influenza B/streptococcal co-infection complicated by organizing pneumonia. *Respirol Case Rep.* 2016;4:e00170.
12. Asai N, Yokoi T, Nishiyama N, Koizumi Y, Sakanashi D, Kato H, et al. Secondary organizing pneumonia following viral pneumonia caused by severe influenza B: a case report and literature reviews. *BMC Infect Dis.* 2017;17:572.
13. Yeldandi AV, Colby TV. Pathologic features of lung biopsy specimens from influenza pneumonia cases. *Hum Pathol.* 1994;25:47–53; Chertow DS, Memoli MJ. Bacterial coinfection in influenza: a grand rounds review. *JAMA.* 2013;309:275.
14. Memoli MJ, Athota R, Reed S, Czajkowski L, Bristol T, Proudfoot K, et al. The natural history of influenza infection in the severely immunocompromised vs nonimmunocompromised hosts. *Clin Infect Dis.* 2014;58:214.
15. Ajlan AM, Quiney B, Nicolaou S, Müller NL. Swine-origin influenza A (H1N1) viral infection: radiographic and CT findings. *AJR Am J Roentgenol.* 2009;193:1494–9.
16. Mauad T, Hajjar LA, Callegari GD, da Silva LF, Schout D, Galas FR, et al. Lung pathology in fatal novel human influenza A (H1N1) infection. *Am J Respir Crit Care Med.* 2010;181:72–9.