



IMAGE OF THE MONTH

Gastric Kaposi's sarcoma as a cause of upper gastrointestinal bleeding[☆]

Afectación gástrica de sarcoma de Kaposi como causa de hemorragia digestiva alta

Isabel Maestro Prada^{*}, David Collado Pacheco

Hospital Universitario Severo Ochoa, Leganés, Madrid, Spain



Kaposi sarcoma is a lymphatic endothelial cell neoplasm associated with human herpesvirus 8 (HHV-8) that is more common in males.¹ Four subtypes are distinguished: classic, generally with skin involvement and sometimes with visceral involvement, which tends not to be very aggressive; endemic or African, which follows a variable course and sometimes presents with infiltrative skin lesions and visceral involvement; epidemic, which is associated with human immunodeficiency virus (HIV), with mucocutaneous and visceral involvement; and immunosuppression-associated, which is usually aggressive, with lymphatic, mucosal and visceral involvement.^{1–3} Kaposi sarcoma with gastrointestinal involvement is not unusual in patients with HIV, and is generally asymptomatic.⁴

We report the case of a 73-year-old man of Spanish origin with a history of atrial fibrillation and dilated cardiomyopathy on treatment with simvastatin and acenocoumarol. He was diagnosed with Kaposi sarcoma with exclusively cutaneous involvement, and the corresponding lesions were

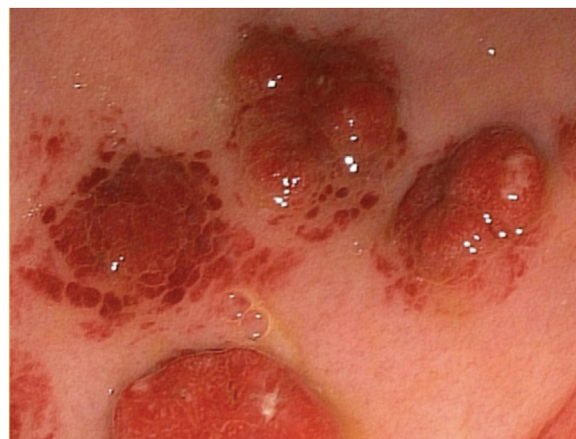


Figure 1 Endoscopic imaging showing raised violaceous nodules in the gastric body.

removed. He had not travelled outside Europe. His HIV serologies were negative, and his viral load was undetectable.

He visited the emergency department with abdominal pain and melaena, haemodynamic stability and mild anaemia, with an international normalised ratio (INR) of 1.8. Upper gastrointestinal endoscopy revealed multiple raised violaceous nodules in the gastric fundus and, in particular,

[☆] Please cite this article as: Maestro Prada I, Collado Pacheco D. Afectación gástrica de sarcoma de Kaposi como causa de hemorragia digestiva alta. *Gastroenterol Hepatol.* 2022;45:289–290.

^{*} Corresponding author.

E-mail address: isabelmaestroprada@gmail.com (I. Maestro Prada).

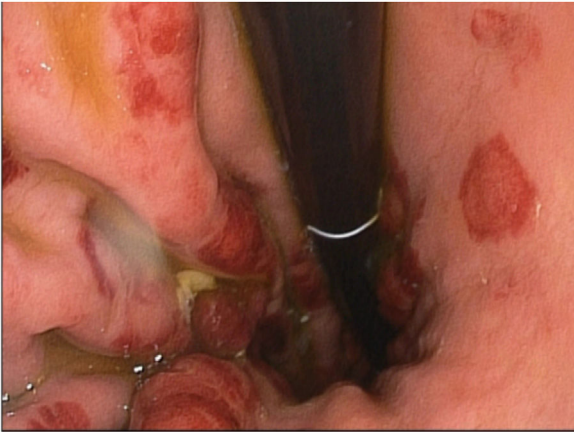


Figure 2 Endoscopic imaging showing raised violaceous nodules in the gastric body.

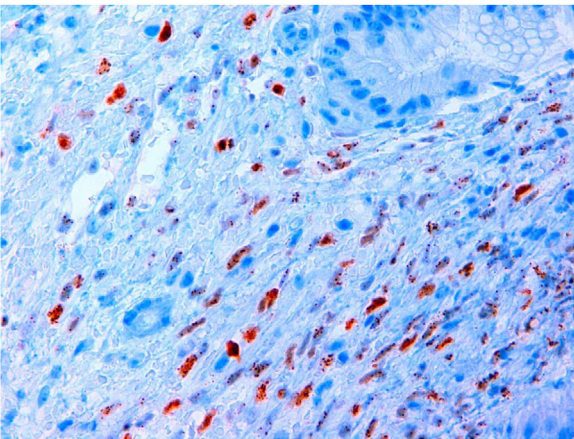


Figure 3 HHV-8 detected by immunohistochemistry, with positivity for fusiform tumour cell nuclei appearing in brown.

the proximal gastric body, in larger numbers towards the greater curvature, with the antrum spared (Figs. 1 and 2).

Pathology confirmed gastric mucosa with infiltration by Kaposi sarcoma; immunohistochemistry detected HHV-8.

A review of the literature on gastrointestinal involvement in Kaposi sarcoma found that, although gastric involvement is not unusual, presentation in the form of gastrointestinal bleeding is very uncommon (Fig. 3).

At the same time, the patient was diagnosed with a spermatocord sarcoma with liver and lung metastases; despite chemotherapy, he died months later.

Funding

No funding was received for this study.

Conflicts of interest

The authors declare that they have no conflicts of interest.

References

1. Lebbe C, Garbe C, Stratigos AJ, Harwood C, Peris K, Del Marmol V, et al. Diagnosis and treatment of Kaposi's sarcoma: European consensus-based interdisciplinary guideline (EDF/EADO/EORTC). *Eur J Cancer*. 2019;114:117–27.
2. Etemad SA, Dewan AK. Kaposi sarcoma updates. *Dermatol Clin*. 2019;37:505–17.
3. Vangipuram R, Tyring SK. Epidemiology of Kaposi sarcoma: review and description of the nonendemic variant. *Int J Dermatol*. 2019;58:538–42.
4. Akanbi O, Saleem N, Maddika S, Saba R. Kaposi sarcoma: an unusual cause of gastrointestinal bleeding. *BMJ Case Rep*. 2016;2016, bcr2016214664.