

IMAGE OF THE MONTH

Major duodenal diverticular bleeding

Hemorragia de divertículo duodenal



Joana Rita Carvalho^{a,*}, Inês Nogueira Fonseca^{b,1}, Carlos Freitas^a,
Paula Moura Santos^a, Luís Carrilho Ribeiro^a, Rui Tato Marinho^a

^a Department of Gastroenterology and Hepatology, North Lisbon Hospital Centre, Hospital de Santa Maria, Portugal

^b Department of Internal Medicine, North Lisbon Hospital Centre, Hospital de Santa Maria, Portugal

Duodenal diverticula (DD) are present in 20% of adults.^{1,2} Bleeding is a rare event (0.14% of upper gastrointestinal bleeding) and there is no defined gold standard method of haemostasis.^{3,4}

A 64-year-old female patient presented with melena with hemodynamic instability. At physical examination, she was tachycardic and nasogastric intubation did not show blood. Laboratory workup revealed acute normocytic

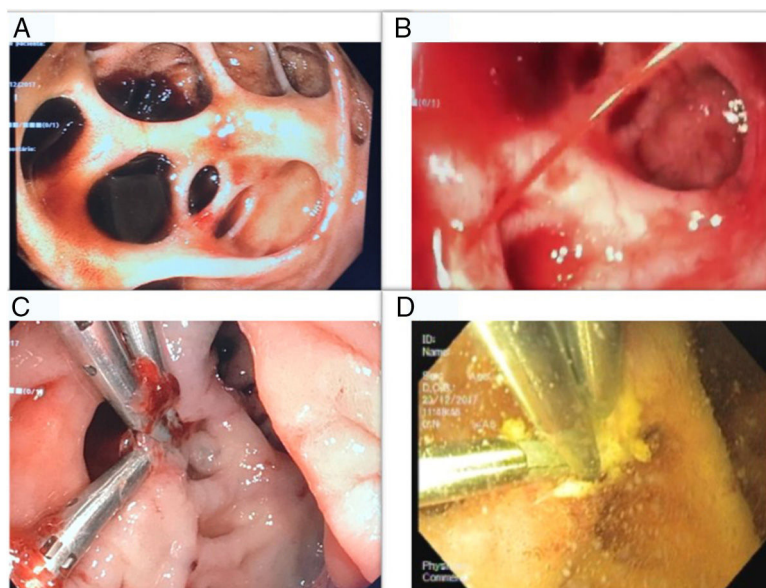


Figure 1 (A) UE revealing blood in the giant DD; (B) during observation, an arterial spurting of the DD was seen; (C) the bleeding was controlled with epinephrine and 3 hemoclips; (D) a second look endoscopy was performed without evidence of rebleeding.

* Corresponding author.

E-mail address: joana.rita.carvalho@gmail.com (J.R. Carvalho).

¹ Co-first authors.

anemia of 8.6 g/dL. An upper endoscopy (UE) was performed and revealed a giant diverticulum of the second duodenal portion, without blood. She presented a new episode of hemodynamic instability and a contrast CT revealed blood in the DD. A second UE was performed using a conventional colonoscope and revealed blood in the DD (Fig. 1A). During observation, an arterial spurting of the DD was seen (Fig. 1B); it was controlled with epinephrine and 3 hemoclips (Fig. 1C). A second look endoscopy was performed, without evidence of rebleeding (Fig. 1D). The patient was discharged 5 days later.

Most common endoscopic approaches include injection, thermal and mechanic methods alone or combined.⁴ Although there are no available comparative studies, theoretically, clipping seems to be better than injection methods.¹ It was suggested that air removal before hemoclip may reduce perforation.⁵

Funding

No funding.

Conflicts of interest

No conflicts of interest.

References

1. Onozato Y, Kakizaki S, Ishihara H, Iizuka H, Sohara N, Okamura S, et al. Endoscopic management of duodenal diverticular bleeding. *Gastrointest Endosc.* 2007;66:1042–9.
2. Khandelwal M, Akerman PA, Jones WF, Haber GB. Endoscopic therapy of a bleeding duodenal diverticulum. *Am J Gastroenterol.* 1995;90:1328–9.
3. Valdivielso Cortazar E, Madarnás Alonso L, Ortíz Marín S, Couto Worner I, Alonso Aguirre P. Duodenal diverticular bleeding: an endoscopic challenge. *Rev Esp Enferm Dig.* 2017;109:468–9.
4. Chen YY, Yen HH, Soon MS. Impact of endoscopy in the management of duodenal diverticular bleeding: experience of a single medical center and a review of recent literature. *Gastrointest Endosc.* 2007;66:831–5.
5. Lee SY, Hong SP, Hwang SK, Park PW, Rim KS. Duodenal perforation after endoscopic hemoclip application for bleeding from Dieulafoy's lesion in a duodenal diverticulum. *Gastrointest Endosc.* 2005;62:781–2.