

## Hepatic inflammatory pseudotumor related with IgG4<sup>☆</sup>



### Seudotumor inflamatorio hepático relacionado con IgG4

#### Introduction

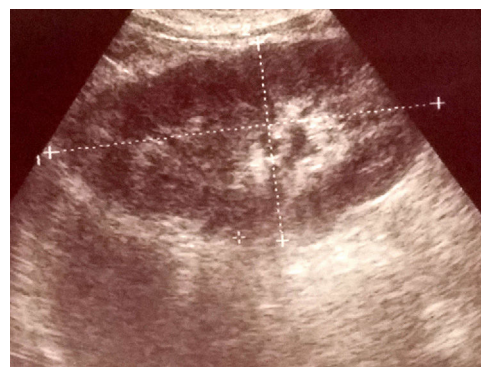Hepatic inflammatory pseudotumor (HIP) is a liver manifestation of a systemic disease that can occur in organs like lungs, salivary glands and pancreas. Etiology and pathogenesis of the disease is not clear with autoimmune etiology being the most common theory.<sup>1</sup> Recently, an attempt to explain the pathophysiology of the lesion in correlation with IgG4 has been undertaken. Pathological processes of inflammation can lead to specific set of changes in the tissue structure: lymphoplasmacytic inflammatory cells with fibrosis.<sup>2</sup> Herein, we report a case of HIP diagnosed by laparoscopic resection (Figs. 1–2).

#### Case report

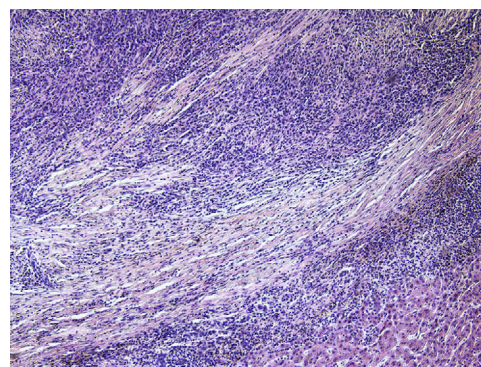
A 60-year-old man with a 5-years history of alcohol-related chronic pancreatitis with suspected liver tumors seen on routine CT has been referred for diagnosis. CT scans showed two poorly visible hypoechoic infiltrations; one in the segment II with a diameter of 28 mm and the one in segment VI with a diameter of 20 mm. On ultrasound only the tumor in segment II with a diameter of 14 mm has been noted. The segment VI was free of any pathology on intraoperative ultrasound. Percutaneous liver fine needle biopsy has been performed with cytology showing chronic inflammatory cells. Laboratory data showed increased serum concentrations of bilirubin and white blood cells. The patient has been referred for a laparoscopic biopsy. The surgical resection of the segment II of the liver was performed by laparoscopy. On the 5th postoperative day the patient presented with abdominal pain, distention and signs of peritonitis. On emergency laparotomy bile peritonitis has been diagnosed. The leaking stump of a bile duct has been sewn and abundant peritoneal lavage performed. Further postoperative course was uneventful. Histopathological examination of the liver tumor showed diffuse inflammatory infiltration with lymphoid cells coinciding with the diagnosis of IgG4 related HIP. The blood test examination showed serum IgG4 level of 19.1 g/L.

#### Discussion

The differential diagnosis of a HIP is difficult.<sup>3</sup> On imaging studies a HIP can mimic a metastatic disease, primary liver cancer or a benign lesion.<sup>4</sup> Patients with HIP tend to be over 60 years old and more often (8×) men than women. There were several cases of exposure to industrial solvents,



**Figure 1** Ultrasonography imaging shows a hypoechoic 14 mm mass.



**Figure 2** Microscopic view of IgG4-related hepatitis. The hepatic stroma shows extensive fibrosis and abundant inflammatory infiltrate.

dust, lubricants and pesticides.<sup>1</sup> In the differential diagnosis one has to consider especially Inflammatory pseudotumor which can occur in various locations (frequently in the lung). It can mimic malignant tumor. The lesion is composed of proliferation of fibrous tissue with presence of numerous inflammatory cells (plasma cells, lymphocytes, neutrophils, macrophages, multinucleated giant cells and eosinophils). HIP can be a IgG4-related disease. In our case there were two histological features of IgG4 – dense lymphoplasmacytic infiltrate and extensive fibrosis. On immunohistochemistry IgG stain showed many IgG-positive plasma cells and a number of IgG4-positive cells (focally >10 cells/HPF; but altogether IgG4/IgG (+) cell ratio was about 10–20%). Other tumors to be considered in differential diagnosis of HIP are tumors of parasitic origin (for example Entamoeba), neoplasms (inflammatory myofibroblastic tumor) and other causes of inflammatory infiltration in the liver.

In the majority of patients the diagnosis can be achieved by needle liver biopsy, however, as in our patient, resection is sometimes required to reach the diagnosis.<sup>5</sup>

Unfortunately, the risk of serious and even life threatening complications after this procedure is much higher than after non-surgical diagnostic procedures.<sup>6</sup> The full histopathological evaluation of the lesion, together with laboratory finding can give way to a firm diagnosis of a specific type of HIP.<sup>7</sup> Once the diagnosis is established treatment with steroids is suggested.<sup>3</sup> In patients who were diagnosed

<sup>☆</sup> This work has been presented during 6th Biennial Congress of the Asian-Pacific Hepato-Pancreato-Biliary Association in Yokohama, Japan, 7–10 June 2017.

by biopsy alone, liver resection can also be required as a definitive treatment when steroid therapy is futile.<sup>5</sup>

## Conflict of interests

The authors declare no conflict of interests.

## References

1. Kleger A, Seufferlein T, Wagner M, Tannapfel A, Hoffmann TK, Mayerle J. IgG4-related autoimmune diseases. *Dtsch Arztebl Int.* 2015;112:128–35.
2. Zen Y, Fujii T, Sato Y, Masuda S, Nakanuma Y. Pathological classification of hepatic inflammatory pseudotumor with respect to IgG4-related disease. *Mod Pathol.* 2007;20:884–94.
3. Shibata M, Matsubayashi H, Aramaki T, Uesaka K, Tsutsumi N, Sasaki K, et al. A case of IgG4-related hepatic inflammatory pseudotumor replaced by an abscess after steroid treatment. *BMC Gastroenterol.* 2016;16:89.
4. Calvo J, Carbonell N, Scatton O, Marzac C, Ganne-Carrie N, Wendum D. Hepatic nodular lymphoid lesion with increased IgG4-positive plasma cells associated with primary biliary cirrhosis: a report of two cases. *Virchows Arch.* 2015;467:613–7.
5. Ahn KS, Kang KJ, Kim YH, Lim TJ, Jung HR, Kang YN, et al. Inflammatory pseudotumors mimicking intrahepatic

- cholangiocarcinoma of the liver; IgG4-positivity and its clinical significance. *J Hepatobiliary Pancreat Sci.* 2012;19:405–12.
6. Komorowski AL, Li WF, Millan CA, Huang TS, Yong CC, Lin TS, et al. Temporary abdominal closure and delayed biliary reconstruction due to massive bleeding in patients undergoing liver transplantation: an old trick in a new indication. *J Hepatobiliary Pancreat Sci.* 2016;23:118–24.
  7. Umehara H, Okazaki K, Masaki Y, Kawano M, Yamamoto M, Saeki T, et al. Comprehensive diagnostic criteria for IgG4-related disease (IgG4-RD), 2011. *Mod Rheumatol.* 2012;22:21–30.

Oleksandr Legkiy<sup>a,\*</sup>, Justyna Wajda<sup>a,b</sup>, Anna Ćwierz<sup>a</sup>, Joanna Wysocka<sup>c</sup>, Andrzej L. Komorowski<sup>a</sup>

<sup>a</sup> Department of Surgical Oncology, Maria Skłodowska-Curie Memorial Cancer Center and Institute of Oncology, Cracow, Poland

<sup>b</sup> Department of Anatomy, Jagiellonian University Medical College, Cracow, Poland

<sup>c</sup> Department of Pathology, Maria Skłodowska-Curie Memorial Institute, Cancer Centre, Cracow, Poland

\* Corresponding author.

E-mail address: [oleksandr.legkiy@gmail.com](mailto:oleksandr.legkiy@gmail.com) (O. Legkiy). 2444-3824/

© 2018 Elsevier España, S.L.U. All rights reserved.

## Acute epidural haematoma as a presentation of hepatocellular carcinoma: Case report and literature review<sup>☆</sup>



### Hematoma epidural agudo como presentación de carcinoma hepatocelular: a propósito de un caso y revisión de la literatura

A 59-year-old Thai woman living in Spain for the past 20 years with a personal history of a partial nephrectomy and hysterectomy, who was not taking any regular medication. She attended our hospital's emergency department having suffered from general malaise, abdominal distension, jaundice and choluria over the course of two weeks, with her symptoms worsening in the second week. While having her history taken, she mentioned that she had received a blood transfusion in the 1980s. She said she did not take any medicines, herbal products or have tattoos. She travelled often, having visited Thailand and Switzerland in the last year. She had consumed 16 g of alcohol per day for the past five years. During the physical examination, she presented jaundiced skin and mucous membranes and painless

hepatosplenomegaly. Her laboratory tests revealed a previously unknown coagulopathy and abnormal liver parameters: total bilirubin 8.11 mg/dl, direct bilirubin 5.85 mg/dl, GOT 368 U/l, GPT 137 U/l, GGT 625 U/l, AP 190 U/l, CRP 14.39 mg/dl and prothrombin activity of 53%. Twenty-four hours after admission, she presented a sudden-onset intense holocranial headache and a rapid decline in consciousness (Glasgow Coma Score [GCS] of 5), with no focal neurological deficit. The patient was transferred to intensive care, where she underwent orotracheal intubation and a computed tomography (CT) scan of the head with intravenous contrast. The CT scan (Fig. 1) revealed the presence of a left-sided frontoparietal acute epidural haematoma (AEH) measuring 85 × 42 mm, with associated intracranial expansion and hypertensive hydrocephalus in the contralateral ventricle, probably secondary to an osteolytic cranial vault lesion, suggesting a metastatic aetiology. She underwent emergency neurosurgery, with a left frontotemporal craniotomy, evacuation of the haematoma and tumour resection.

The patient presented poor clinical progress, maintaining a GCS score of 3–4 as well as anuria. From a gastrointestinal point of view, an abdominal ultrasound was performed, showing liver cirrhosis with a focal heterogeneous lesion in segment II measuring 4 cm, a partial portal vein tumour thrombus with a hepatofugal flow and mild ascites. Her blood work up tested positive for the hepatitis C virus (HCV) antigen and antibody, with raised alpha-fetoprotein (2476 ng/ml). According to both clinical and analytical data, she presented a Child-Pugh score of C14 and a MELD score of 24. An anatomical pathology study of the skull lesion (bone and epidural) revealed the presence of epithelial tumour cells with abundant eosinophilic cytoplasm,

<sup>☆</sup> Please cite this article as: Delgado Maroto A, del Moral Martínez M, Diéguez Castillo C, Casado Caballero FJ. Hematoma epidural agudo como presentación de carcinoma hepatocelular: a propósito de un caso y revisión de la literatura. *Gastroenterol Hepatol.* 2019;42:177–179.