



## IMAGE OF THE MONTH

### Paterson-Brown-Kelly syndrome

### Síndrome de Paterson Brown Kelly

Satvinder Singh Bakshi<sup>1</sup>

Associate Professor of ENT, Department of ENT and Head & Neck Surgery, Mahatma Gandhi Medical College and Research Institute, Sri Balaji Vidyapeeth, Pillaiyarkuppam, Pondicherry, India



#### Medical image

A 21-year-old woman presented with gradually progressive dysphagia for 4 months. On examination she was pale and had glossitis, cheilitis and koilonychia. The Barium swallow revealed a 8mm web in the post cricoid region (Fig. 1) and blood smear showed microcytic hypochromic anemia with anisocytosis. Other values were Hemoglobin of 4 g/dL (12–14), MCV 63 fL (80–95), MCH 17 pg/dL (27–32), Serum Iron 20 µg/dL (50–140), Serum Ferritin 13 ng/mL (25–250), and total iron binding capacity 480 µg/dL (245–450). A provisional diagnosis of Paterson Brown Kelly syndrome was made and the patient was treated with dilatation of the web (Fig. 2). The anemia was corrected with 2 units of packed cell transfusion and oral hematinics and it improved to 10 g/dL. Paterson Brown Kelly Syndrome or Sideropenic dysphagia consists of a triad of dysphagia, iron deficiency anemia and esophageal webs. The exact etiology is unknown although nutritional deficiencies and some genetic factors have been implicated. It is more common in females and patients usually present with progressive dysphagia along with symptoms of iron deficiency anemia like easy fatigability. The prognosis is good however since it is thought to be a premalignant condition and regular surveillance with annual endoscopy should be done.

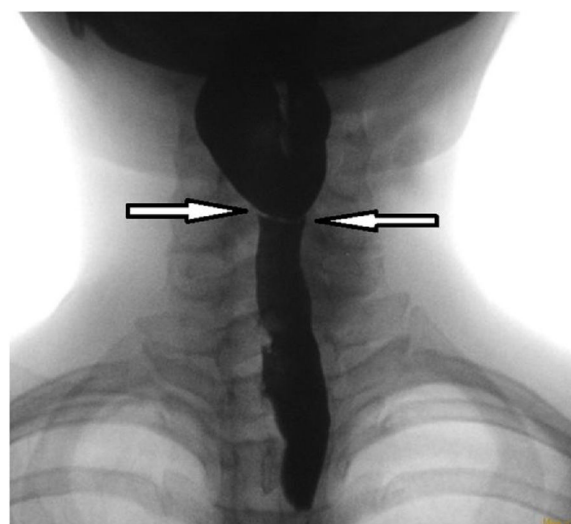
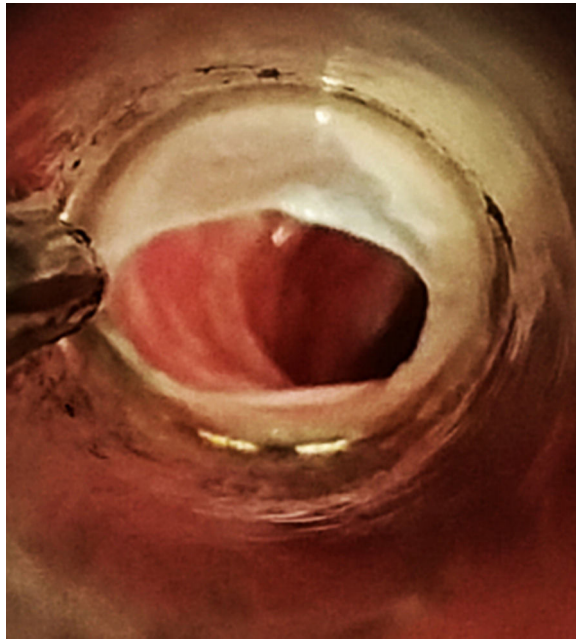


Figure 1 Barium swallow showing the post cricoid web.

E-mail address: [saty.bakshi@gmail.com](mailto:saty.bakshi@gmail.com)

<sup>1</sup> Institution where the work was done – MGMCRI.



**Figure 2** Endoscopic picture of the web.