



IMAGE OF THE MONTH

Gastric Burkitt's lymphoma: A rare entity[☆]

Linfoma de Burkitt gástrico: una entidad infrecuente

Soraya López López^{a,*}, Alfonso Elosua González^a, Marta Gómez Alonso^a,
Diego Requena López^b



^a Servicio de Aparato Digestivo, Complejo Hospitalario de Navarra, Pamplona, Navarra, Spain

^b Servicio de Anatomía Patológica, Complejo Hospitalario de Navarra, Pamplona, Navarra, Spain

Burkitt's lymphoma (BL) is a B-cell non-Hodgkin lymphoma (NHL) with a high rate of proliferation. In adults it is a rare entity and extranodal gastric location is uncommon.

We present the case of a 91-year-old man admitted due to progressive deterioration and anaemia. Gastroscopy showed an ulcerated lesion measuring 2 cm in the greater curvature, and similar smaller lesions in the gastric body (Fig. 1). Histology and immunohistochemistry, consistent with BL, are shown in Fig. 2. A CT scan showed peritoneal

carcinomatosis. He followed a torpid clinical course and died a few days later.

Sporadic BL in adults is uncommon (1–2% of cases of NHL). Its primary extranodal location is abdominal, particularly ileocecal, and its location is rarely gastric.

Endoscopy reveals ulcerated masses described as "doughnut-shaped". Its high rate of proliferation and excellent response to chemotherapy require early diagnosis and treatment to improve the prognosis for these patients.

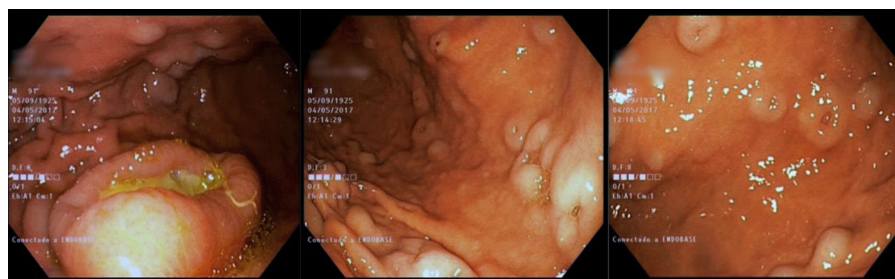


Figure 1 Endoscopy: multiple raised, umbilicated lesions with a "doughnut-shaped" appearance extend through the greater and lesser curvature. The largest, measuring 2 cm, shows a central depression and ulceration on its surface.

[☆] Please cite this article as: López López S, Elosua González A, Gómez Alonso M, Requena López D. Linfoma de Burkitt gástrico: una entidad infrecuente. Gastroenterol Hepatol. 2018;41:375–376.

* Corresponding author.

E-mail address: digestivosorayalopez@gmail.com (S. López López).

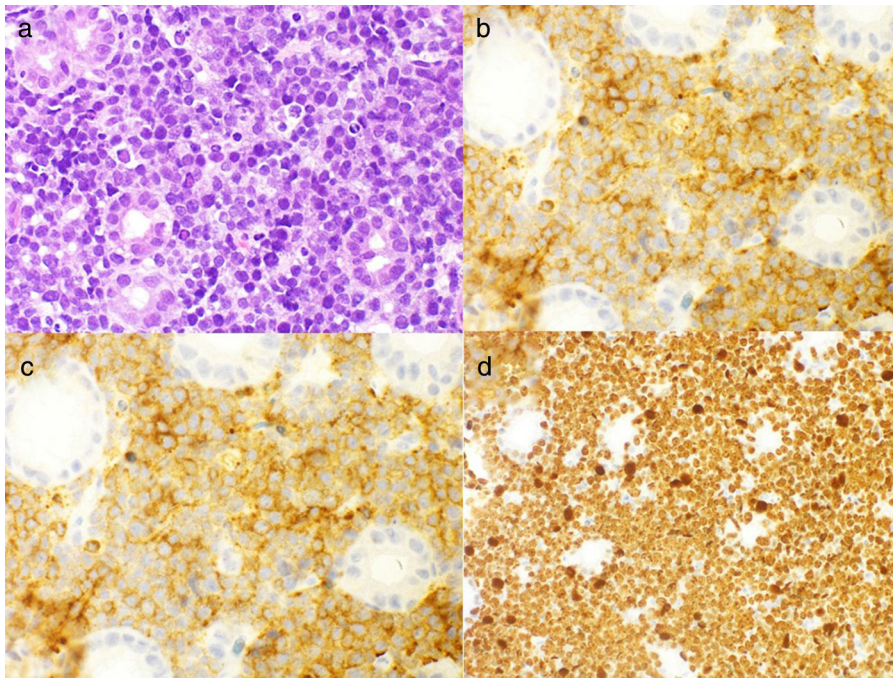


Figure 2 (a) Haematoxylin and eosin staining showing lymphoid infiltrate with a starry-sky pattern; (b) immunohistochemistry positive for CD20 (B-cell marker); (c) immunohistochemistry positive for CD10 (typical of BL); and (d) Ki-67 with a rate of proliferation close to 100%.