

improve clinical symptoms in most patients, but normalisation of intestinal mucosa is rarely achieved and in most cases a dependency on steroids is observed.^{3,9}

The spectrum of disorders related to gluten constitutes a collection of complex diseases with limits that are not always defined. In our case, after having ruled out other causes of non-responsive CD and assuming that the initial tTG had actually been negative, the differential diagnosis with RCD was suggested. However, given an initially positive tTG and the excellent response to corticosteroids and, above all, having presented no relapses after the discontinuation of the corticosteroids, a diagnosis of CC is more probable.

References

1. Ludvigsson JF, Bai JC, Biagi F, Card TR, Ciacci C, Ciclitira PJ, et al. Diagnosis and management of adult coeliac disease: guidelines from the British Society of Gastroenterology. *Gut*. 2014;63:1210–28.
2. Leffler DA, Dennis M, Hyett B, Kelly E, Shuppan D, Kelly CP, et al. Etiologies and predictors of diagnosis in nonresponsive celiac disease. *Clin Gastroenterol Hepatol*. 2007;5:445–50.
3. Rubio-Tapia A, Murray JA. Classification and management of refractory celiac disease. *Gut*. 2010;59:547–57.
4. Jamma S, Rubio-Tapia A, Kelly CP, Murray J, Najarian R, Sheth S, et al. Celiac crisis is a rare but serious complication of celiac disease in adults. *Clin Gastroenterol Hepatol*. 2010;8:587–90.
5. Mooney PD, Evans KE, Singh S, Sanders DS. Treatment failure in celiac disease: a practical guide to investigation and treatment of non-responsive and refractory coeliac disease. *J Gastrointest Liver Dis*. 2012;21:197–203.
6. Malamut G, Afchain P, Verkarre V, Lecomte T, Amiot A, Damotte D, et al. Presentation and long-term follow-up of refractory celiac disease comparison of type with type II. *Gastroenterology*. 2009;136:81–90.
7. Hopper AD, Hadjivassiliou M, Hurlstone DP, Lobo AJ, McAlindon ME, Egner W, et al. What is the role of serologic testing in celiac disease? A prospective, biopsy-confirmed study with economic analysis. *Clin Gastroenterol Hepatol*. 2008;6:314–20.
8. Mrad RA, Ghaddara HA, Green PH, El-Majzoub N, Barada KA. Celiac crisis in a 64-year-old woman: an unusual cause of severe diarrhea, acidosis, and malabsorption. *ACG Case Rep J*. 2015;2:95–7.
9. Nijeboer P, van Wanrooij RL, Tack GJ, Mulder CJ, Bouma G. Update on the diagnosis and management of refractory coeliac disease. *Gastroenterol Res Pract*. 2013;2013:518483.
10. Vaquero L, Arias L, Vivas S. Enfermedad celiaca refractaria. *Omnie Sci*. 2013;36:1–375.

Mayra Lindo Ricce*, Beatriz Rodriguez-Batllore Arán, Mirella Jiménez Gómez, Javier P. Gisbert, Cecilio Santander

Servicio de Aparato Digestivo, Hospital Universitario de La Princesa, Instituto de Investigación Sanitaria Princesa (IIS-IP), Madrid, Spain

* Corresponding author.

E-mail address: mayral86r@gmail.com (M. Lindo Ricce). 2444-3824/

© 2016 Elsevier España, S.L.U. All rights reserved.

Duodenal metastases from sarcomatoid renal cell carcinoma: Case report[☆]



Metástasis a duodeno de cáncer renal de células claras con patrón sarcomatoide: reporte de caso

Renal cell carcinoma constitutes 3% of all neoplasms. At the time of diagnosis, 25% of patients have metastasis, reaching 51% in patients with nephrectomy.¹ Metastasis presents in the gastrointestinal tract in 0.2–0.7%.² There are few cases reported with metastasis of renal cell carcinoma to the duodenum, with the minority in women. The most common histology (75–85%) of these neoplasms are clear cells, with the sarcomatoid type variant being associated with poor prognosis.³ There are no reported cases of duodenal metastasis of clear cell renal cell carcinoma (CCRCC) with sarcomatoid differentiation, with this being the first case in

a 48-year-old patient who came to the emergency department due to gastrointestinal tract bleeding.

A 48-year-old woman with a history of chronic exposure to wood smoke 200h/year, high blood pressure for the past seven years, and nephrectomy one year prior to her admission due to CCRCC carcinoma with sarcomatoid differentiation. She came in with symptoms of one-week evolution characterised by burning and sharp epigastric pain, haematemesis and melaena. At admission she had hypotension, tachycardia, and was febrile. Her admission analysis reported haemoglobin 6.5g/dl, thrombocytosis $797 \times 10^3/\text{mm}^3$, leukocytosis $14.7 \times 10^3/\text{mm}^3$ with neutrophilia of $12.9 \times 10^3/\text{mm}^3$ and elevated C reactive protein of 27.8 mg/l. An abdominal computed tomography (CT) was carried out, showing a mass in the second part of the duodenum, measuring 41 mm × 37 mm × 56 mm. An endoscopy was performed, showing a 10 cm tumour of neoplastic appearance in the second part of the duodenum, submucosal, with irregular and ulcerated surface with areas of haemorrhage, with 90% stenosis of the duodenal lumen (Fig. 1). The biopsy reported CCRCC with metastatic sarcomatoid differentiation (Fig. 2). The patient continued with gastrointestinal tract bleeding, requested voluntary discharge, and died one week later.

The most common metastasis locations for CCRCC are: lungs (75%), lymph nodes (36%), liver (18%), brain (8%) and skin (6%).⁴ It causes invasion in the gastrointestinal tract

[☆] Please cite this article as: Villela-Segura U, García-Leiva J, Nuñez Becerra PJ. Metástasis a duodeno de cáncer renal de células claras con patrón sarcomatoide: reporte de caso. *Gastroenterol Hepatol*. 2017;40:530–532.

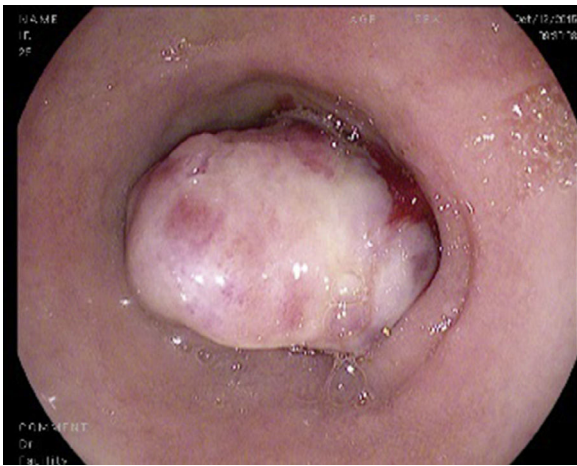


Figure 1 Tumour in the second part of the duodenum, of submucosal appearance, with an irregular and ulcerated surface.

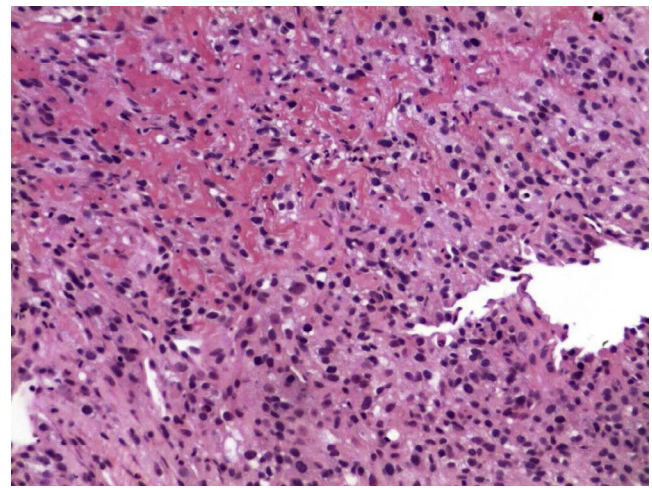


Figure 2 Biopsy of duodenal tumour consistent with metastasis of clear cell renal cell carcinoma with sarcomatoid differentiation of the primary tumour, characterised by grouping of fusiform cells with an interlinked and storiform pattern, with nuclear pleomorphism.

in less than 1%, and globally represents 7.1% of gastrointestinal tract metastases. Currently, only 30 cases have been reported in the medical literature on duodenal invasion.¹

The majority of metastatic CCRCC cases in the gastrointestinal tract are reported in men, with a 1.5:1 ratio to women. Its incidence increases with age, with a mean of 60.7 ± 14 years, with a high percentage of these occurring during the first year post nephrectomy as occurred in our patient, although there are reports of latency of up to 16 years.¹ This means that onset has an unpredictable evolution. The majority of cases manifest as episodes of bleeding in the gastrointestinal tract, characterised by the presence of melaena, haematemesis, anaemia and even occlusion. Its dissemination types are: a) peritoneal, b) direct spreading from the neoplasm, c) haematogenous, and d) lymphatic; associated with the presence of parathyroid hormone-related protein.⁵

At the endoscopic level it manifests as single or multiple ulcerated submucosal masses of various sizes; in this case the patient had a 10 cm diameter tumour with characteristics consistent with the above description.

CCRCC of the sarcomatoid type has been described as being associated with a poor prognosis, being described in this way in a series of cases that show the sarcomatoid type related to a decrease in survival and in the metastasis-free period, as well as to resistance to first-line treatment such as IL-2 in metastatic disease.³ This highlights the fact that the disease spreading on its own is ominous, even with the advent of new therapies, such as nivolumab.⁶ When there is duodenal invasion, the estimated survival time is less than one year. In the mentioned case, due to its complexity and the persistence of the bleeding, a surgical approach would have been difficult, although more conservative management such as an arteriogram with embolisation could have been done merely as a palliative measure due to the patient's poor prognosis.⁷

The importance of this case resides in it being the first reported case of CCRCC with sarcomatoid differentiation with metastasis to the duodenum. The majority of cases

of duodenal invasion by CCRCC occur in men, with only 6 recorded cases in women. Thus, this shows an exceptional case that helps aid knowledge about the unpredictable behaviour of CCRCC and where in this case in particular, due to the presence of the sarcomatoid differentiation, there was a poor prognosis from the beginning.

CCRCC is a neoplasm that has difficult-to-predict behaviour and evolution where, despite treatment, there may be recurrences that can arise years after treatment, which makes us consider that it should be monitored more aggressively. When it metastasises in the gastrointestinal tract, the short- and mid-term prognosis is poor. The sarcomatoid differentiation worsens the prognosis even more.

References

1. Geramizadeh B, Mostaghni A, Ranjbar Z, Moradian F, Heidari M, Khosravi MB, et al. An unusual case of metastatic renal cell carcinoma presenting as melena and duodenal ulcer, 16 years after nephrectomy; a case report and review of the literature. *Iran J Med Sci.* 2015;40:175–80.
2. Green LK. Hematogenous metastases to the stomach. A review of 67 cases. *Cancer.* 1990;65:1596–600.
3. Tirumani SH, Souza D, Krajewski KM, Jagannathan JP, Ramaiya NH, Shinagare AB. Impact of histologic subtype and sarcomatoid transformation on metastasis in renal cell carcinoma: a single institute experience in 149 patients. *Abdom Radiol (NY).* 2016;41:295–302.
4. Peris K, Fargnoli MC, Lunghi F, Chimenti S. Unusually large cutaneous metastases of renal cell carcinoma. *Acta Derm Venereol.* 2015;81:77–8.
5. Onak Kandemir N, Barut F, Yilmaz K, Tokgoz H, Hosnuter M, Ozdamar SO. Renal cell carcinoma presenting with cutaneous metastasis: a case report. *Case Rep Med.* 2010;2010, pii:913734.
6. Motzer RJ, Escudier B, McDermott DF, George S, Hammers HJ, Srinivas S, et al. Nivolumab versus everolimus in advanced renal-cell carcinoma. *N Engl J Med.* 2015;373:18013–21813.
7. Adamo R, Greaney PJ Jr, Witkiewicz A, Kennedy EP, Yeo CJ. Renal cell carcinoma metastatic to the duodenum: treatment by classic

pancreaticoduodenectomy and review of the literature. *J Gastrointest Surg.* 2008;12:1465–8.

Uriel Villela-Segura^{a,*}, Jorge García-Leiva^b,
Perla Judith Nuñez Becerra^a

^a *Servicio de Medicina Interna, Hospital Central Dr. Ignacio Morones Prieto, Universidad Autónoma de San Luis Potosí, San Luis Potosí, Mexico*

^b *Servicio de Gastroenterología, Hospital Central Dr. Ignacio Morones Prieto, Universidad Autónoma de San Luis Potosí, San Luis Potosí, Mexico*

* Corresponding author.

E-mail address: uvise08@gmail.com (U. Villela-Segura).
2444-3824/

© 2016 Elsevier España, S.L.U. All rights reserved.

Superior mesenteric artery pseudoaneurysm due to chronic pancreatitis[☆]



Pseudoaneurisma de arteria mesentérica superior por pancreatitis crónica

The formation of visceral artery pseudoaneurysms (VAPAs) as a vascular complication of pancreatitis is a very rare phenomenon. Even more exceptional is the formation of localised pseudoaneurysms in the superior mesenteric artery (SMA).

We report the case of a 58-year-old female patient with a history of chronic alcoholism, hypertension, diabetes mellitus, alcoholic liver cirrhosis, and chronic alcoholic pancreatitis with a 32 × 43 mm pancreatic pseudocyst, according to the last CT scan performed in May 2011. No surgical history.

The patient came to the emergency department due to 6 h of intense epigastric pain, which irradiated to both hypochondria and was accompanied by nausea and vomiting. No fever or accompanying symptoms were reported. An analysis was carried out showing hyperamylasaemia of 2215 U/l, AST/ALT 32/18 U/l, total bilirubin 2.7 mg/dl, leukocytes 21,910 mm³ (91%N, 4%L), Hb 15.1 g/dl, Hct 42.9% and INR 1.32. Initially, it was considered an exacerbation of chronic pancreatitis, and it was decided to admit her to the gastrointestinal department to start treatment and monitoring.

At 24 h after arrival, the patient remained haemodynamically stable, although the intense abdominal pain persisted. In the follow-up analysis, acute anaemisation was observed with Hb 10.7 g/dl and Hct 29.9%. A CTA was performed which showed signs of chronic pancreatitis, chronic liver disease, diffuse ascites (perihepatic, perisplenic, between bowel loops and in the pelvis) and a heterogeneous collection of blood in various stages of evolution with signs of recent bleeding encompassing SMA, which suggests a contained rupture of a pseudoaneurysm of the superior mesenteric artery (PSMA) (Fig. 1).

The case was consulted with the vascular surgery department, and it was decided to perform an arteriogram with

intention to treat with endovascular treatment (EVT) to exclude the PSMA.

Via a left humeral access, the SMA was catheterised using a multipurpose catheter (COOK[®]), and a 6F introducer was placed in the origin of the SMA. A selective arteriogram was performed, showing a large wide-neck pseudoaneurysm with an irregular true lumen of approximately 25 mm. Using a telescoping technique, the aneurysm sac was catheterised with a Progreat[®] (Terumo) microcatheter, which was inserted into the pseudoaneurysm. To prevent the coils from migrating to the SMA, a scaffolding technique was used on the sac, initially embolising it with two controlled-release 25 × 25 mm and 20 × 50 mm type DCS (COOK[®]) J microcoils creating a ‘‘cage’’ and then filling the ball-shaped sac with 15 × 8 mm and 10 × 8 mm DCS spiral microcoils. A control angiograph was performed, showing a contrast image remaining at the entrance to the aneurysm sac. It was assessed whether to continue with this technique, although due to the high risk of arterial lumen invasion by a coil, it was decided to leave the Progreat[®] microcatheter inside the pseudoaneurysm sac and place a coated 5 × 28 mm stent (BeGraft[®]) in the SMA. Then it was embolised with a new 10 × 8 mm DCS spiral coil to finish excluding the pseudoaneurysm.

In verifying the arteriogram, complete exclusion of the aneurysmal sac with SMA permeability was observed and with preserved collaterality except in the area where the stent was placed where there is no contrast of various jejunal branches (Fig. 2).

During her hospital stay, the patient had no complications related to vascular disease, and did not develop anaemia again. She was discharged 20 days after the EVT.

She was later monitored in outpatient consultations via CTA at one and three months after the intervention. No growth or effusions were observed in the aneurysm cavity, the stent remained permeable and there was no stenosis. The patient remained clinically asymptomatic.

In light of the previous case, we can highlight that the incidence of pseudoaneurysms as a complication after pancreatitis is low and not well established. Some reported case series establish a range of incidence of 1.2–14%,¹ with an incidence of 1–6% in acute pancreatitis and a higher incidence of 7–10% in chronic pancreatitis due to its frequent association with pancreatic pseudocysts.²

Different mechanisms have been suggested to explain the formation of pseudoaneurysms. The two most accepted theories are related to: the presence of a pseudocyst that erodes and weakens the wall of an artery adjacent to the pancreas, leading to the formation of a pseudoaneurysm,

[☆] Please cite this article as: Pantoja Peralta C, Moreno Gutiérrez Á, Gómez Moya B. Pseudoaneurisma de arteria mesentérica superior por pancreatitis crónica. *Gastroenterol Hepatol.* 2017;40: 532–534.