

4. Hsu JT, Yeh CN, Hung CF, Chen HM, Hwang TL, Jan YY, et al. Management and outcome of bleeding pseudoaneurysm associated with chronic pancreatitis. *BMC Gastroenterol.* 2006;6:3.
5. Vandy FC, Stanley JC. Gastroduodenal and pancreaticoduodenal artery aneurysms. In: *Current therapy in vascular and endovascular surgery.* Saunders; 2014. p. 749–52.
6. Izaki K, Yamaguchi M, Kawasaki R, Okada T, Sugimura K, Sugimoto K. N-butyl cyanoacrylate embolization for pseudoaneurysms complicating pancreatitis or pancreatectomy. *J Vasc Interv Radiol.* 2011;22:302–8.
7. El-Dosoky MM, Reeders JW, Dola J, Bienfait HP. Radiological diagnosis of gastroduodenal artery pseudoaneurysm in acute pancreatitis. *Eur J Radiol.* 1994;18:235–7.
8. Chiang KC, Chen TH, Hsu JT. Management of chronic pancreatitis complicated with a bleeding pseudoaneurysm. *World J Gastroenterol.* 2014;20:16132–7.
9. Udd M, Leppäniemi AK, Bidel S, Keto P, Roth WD, Haapiainen RK. Treatment of bleeding pseudoaneurysms in patients with chronic pancreatitis. *World J Surg.* 2007;31:504–10.

Cristina Pantoja Peralta, Ángela Moreno Gutiérrez*, Benet Gómez Moya

Servicio de Angiología y Cirugía Vasculay Endovascular, Hospital Universitari Joan XXII, Tarragona, Spain

* Corresponding author.

E-mail address: morenog.angela@gmail.com

(Á. Moreno Gutiérrez).

2444-3824/

© 2016 Elsevier España, S.L.U. All rights reserved.

Partial duodenectomy as a therapeutic option in multiple duodenal gastrointestinal stromal tumour associated with neurofibromatosis type 1[☆]



Duodenectomía parcial como opción terapéutica de un tumor del estroma gastrointestinal duodenal múltiple, asociado a neurofibromatosis tipo 1

The incidence of gastrointestinal stromal tumours (GIST) is 10–20/10⁶ inhabitants/year.¹ It is the most common tumour of mesenchymal origin in the digestive tract and constitutes 1–2% of gastrointestinal neoplasms.² The duodenal location is rare, corresponding to 5–7%, behind GISTs in a gastric (50–70%) and small intestinal (20–30%) location, and the association with neurofibromatosis type 1 is infrequent.² The most accepted treatment is surgical resection with free margins, along with imatinib therapy in metastatic cases or recurrent disease and as neoadjuvant therapy for large lesions or complex locations.³ The duodenal location of GISTs is the most complex with relation to surgical treatment, although there are different options based on the duodenal area where the lesion is located and the relationship to adjacent organs.⁴ There are few articles published on this topic, generally isolated cases or short series.^{3–6}

We present the case of a 40-year-old man with neurofibromatosis type 1 undergoing treatment for anaemia of 2 months evolution, and in the last full blood count he presented haemoglobin of 6 mg/dl. The patient was asymptomatic, with the exception of dark faeces. The upper gastrointestinal tract endoscopy (UGIE) of the third part

of the duodenum showed a 3–4 cm ulcerated tumour with a stable adhered clot. No biopsies were taken due to the risk of bleeding. A second UGIE was performed 4 days later, with a pathological anatomy outcome of duodenal ulcer with regenerative changes on the borders. After the abdominal CT scan, which identified a lesion in the third part of the duodenum, without being able to reach a conclusion about the nature thereof, a PET/CT scan was performed (Fig. 1A), diagnosing him with a 4 cm poorly-delimited hypermetabolic duodenal lesion, suggestive of a neoplastic lesion, with no other lesions (Fig. 1B). A surgical intervention was carried out, finding, via visual inspection and palpation, two lesions smaller than 1 cm of neoplastic appearance in the proximal jejunum together with two others (1 × 1 and 4 × 3 cm) on the non-pancreatic side of the third part of the duodenum, with the latter probably causing the symptoms of gastrointestinal bleeding. No other lesions were found in the intestine or stomach. Given the lack of a histological perioperative diagnosis of the lesion and with this being important for the surgical approach to follow, an intraoperative biopsy was performed, reporting a GIST. Since the lesion was located in the third part of the duodenum, it had to be ensured that the opening of the bile duct—located in the second part of the duodenum, next to the resection area—was not injured, therefore a cholecystectomy was performed along with identification of the ampulla of Vater by means of bile duct canalisation with a Fogarty probe via the cystic duct. After identification, a duodenectomy of the third and fourth parts of the duodenum was performed, including the lesions in the contiguous proximal jejunum (Fig. 2A). The intestinal tract was reconstructed via duodenal-jejunal termino-terminal anastomosis and placement of a TachoSil[®] patch (Fig. 2B). The post-operative period proceeded without complications, with discharge after 8 days. The pathological anatomy report showed the presence of a multiple stromal tumour (4 lesions) of low degree of malignancy (<4 cm and <5 mitotic figures per 50 HPF) and positive *c-kit*, receiving no adjuvant oncological treatment. Two months after the surgical intervention, a capsule endoscopy was performed, ruling out the existence of other lesions throughout the digestive tract that may not have been detected intra-operatively. The patient was asymptomatic and had no relapses at 15 months.

[☆] Please cite this article as: Palomeque Jiménez A, Rubio López J, Pérez Cabrera B, Jiménez Ríos JA. Duodenectomía parcial como opción terapéutica de un tumor del estroma gastrointestinal duodenal múltiple, asociado a neurofibromatosis tipo 1. *Gastroenterol Hepatol.* 2017;40:534–536.

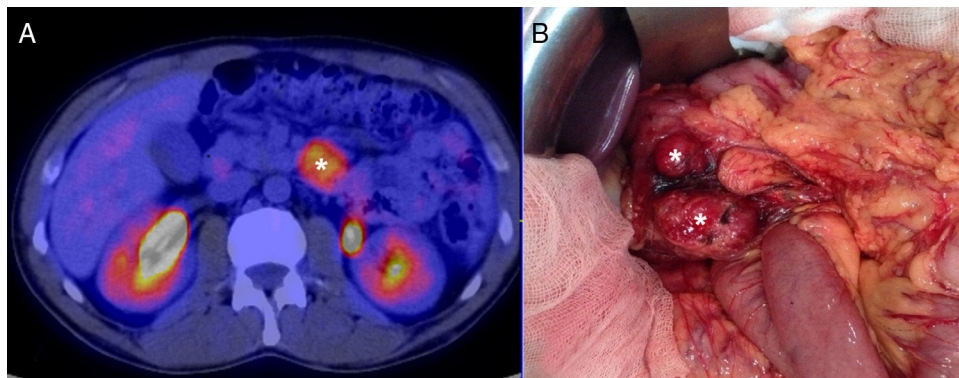


Figure 1 (A) PET/CT image showing the duodenal lesion, marked with (*). (B) Intra-operative image showing two tumours in the third and fourth parts of the duodenum, marked with (*).

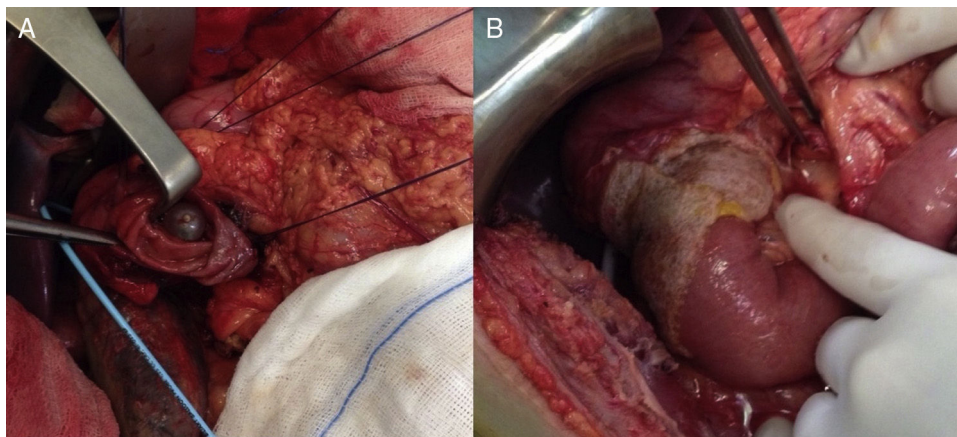


Figure 2 (A) Result after partial duodenectomy. (B) Reconstruction of the intestinal tract via duodenal-jejunal termino-terminal anastomosis and placement of a TachoSil® patch.

In 5–7% of cases, the GIST was located in the duodenum, and most caused symptoms related to gastrointestinal bleeding.^{2,7} Five per cent of cases occurred in the context of familial syndrome (Carney-Stratakis, Carney triad, familial GIST and neurofibromatosis), with neurofibromatosis type 1 being the most common, as in our case.^{2,5} The second part of the duodenum is most affected.^{4,7} GIST spreads haematogenously, with exceptional spreading via lymphatic and local infiltration. Therefore the objective of surgery is complete resection of the lesions with free margins, with lymphadenectomy not recommended.^{3,7-9}

A diagnosis of GIST is based on the UGIE and an abdominal CT or MRI scan, with a PET/CT scan being helpful in the event of any diagnostic doubt, as occurred in the described case.^{3,5,7,10}

The surgical options for duodenal GISTs are cephalic duodenopancreatectomy (CDP), complete duodenectomy with preservation of the pancreatic head, partial duodenectomy and wedge resection. The different locations in the duodenum, tumour size and the possibility of R0 resection qualify the type of surgery,^{1,7,8} although the ideal surgical approach is still not well established despite the different studies that

compare the oncological results with the different resection techniques.^{7,8,10}

For tumours located in the distal, third, and fourth parts of the duodenum, CDP seems to be an excessively aggressive option, while other options could be considered, such as local wedge resection or partial duodenectomy, as was done in our case, reserving CDP for large tumours and those located in the medial wall of the duodenum with involvement of the adjacent pancreas.^{1,3,7,8} The above conservative options could also be considered a surgical option in tumours located in the first and second parts of the duodenum, when the lesion is located in the lateral wall, it is small, and it is verified that there is no involvement of the papillary area, reserving CDP for the rest of cases or complete duodenectomy with preservation of the pancreatic head in select cases.^{1,3,7-9}

The tumour size and mitotic count are the determining factors of survival.^{1,4,9} Adjuvant or neoadjuvant therapy with imatinib is indicated in patients with GISTs that are very large, metastatic, recurrent or in complex locations, such as the duodenum.³ It was not suggested as neoadjuvant therapy in our case since there was no perioperative pathological anatomy diagnosis.

References

1. Buchs NC, Bucher P, Gervaz P, Ostermann S, Pugin F, Morel P. Segmental duodenectomy for gastrointestinal stromal tumor of the duodenum. *World J Gastroenterol.* 2010;16:2788–92.
2. Joensuu H. Gastrointestinal stromal tumor (GIST). *Ann Oncol.* 2006;17:280–1.
3. Beltrán MA, Valenzuela C, Díaz R, Haito Y, Larrain C. Tumores del estroma gastrointestinal del duodeno: revisión de la literatura científica actual con énfasis en el tratamiento. *Rev Colomb Cir.* 2014;29:140–54.
4. Beham A, Schaefer IM, Cameron S, von Hammerstein K, Füzesi L, Ramadori G, et al. Duodenal GIST: a single center experience. *Int J Colorectal Dis.* 2013;28:581–90.
5. Johnston FM, Kneuert PJ, Cameron JL, Sanford D, Fishers S, Turley R, et al. Presentation and management of gastrointestinal stromal tumors of the duodenum: a multi-institutional analysis. *Ann Surg Oncol.* 2012;19:3351–60.
6. Tien YW, Lee CY, Huang CC, Hu RH, Lee PH. Surgery for gastrointestinal stromal tumors of the duodenum. *Ann Surg Oncol.* 2010;17:109–14.
7. García-Molina FJ, Mateo-Vallejo F, Franco-Osorio JD, Esteban-Ramos JL, Rivero-Henández I. Surgical approach for tumours of the third and fourth part of the duodenum. Distal pancreas-sparing duodenectomy. *Int J Surg.* 2015;18:143–8.
8. Bourgouin S, Hornez E, Guiramand J, Barbier L, Delperio JR, Le Treut YP, et al. Duodenal gastrointestinal stromal tumors (GIST): arguments for conservative surgery. *J Gastrointest Surg.* 2013;17:482–7.
9. El-Gendi A, El-Gendi S, El-Gendi M. Feasibility and oncological outcomes of limited duodenal resection in patients with primary non metastatic duodenal GIST. *J Gastrointest Surg.* 2012;16:2197–202.
10. Marcelo A, Beltrán S. Tumores del estroma gastrointestinal (GIST) del duodeno: presentación clínica, estudio diagnóstico y tratamiento actual. *Rev Chil Cir.* 2014;66:381–93.

Antonio Palomeque Jiménez*, José Rubio López,
Beatriz Pérez Cabrera, José Antonio Jiménez Ríos

Servicio de Cirugía General y Aparato Digestivo, Complejo Hospitalario Universitario de Granada, Granada, Spain

* Corresponding author.

E-mail address: apalomeque2002@hotmail.com

(A. Palomeque Jiménez).

2444-3824/

© 2016 Elsevier España, S.L.U. All rights reserved.

Long-acting octreotide is effective in the treatment of portal hypertensive colopathy



El octreótido de larga duración es eficaz en el tratamiento de la colopatía portal hipertensiva

Portal hypertensive colopathy (PHC) is the colonic manifestation of portal hypertension. It refers to mucosal changes distributed along the colon: mucosal edema, erythema, granularity, friability, and vascular lesions such as angiodysplasia¹.

We report the case of a 77-year-old man with a long-course history of cirrhosis to alcohol and hepatitis C virus, Child–Pugh B (8 points), with a previous episode of esophageal variceal bleeding, diabetes mellitus type 2, and iron-deficiency anemia, medicated with propranolol 30 mg/day, furosemide 40 mg/day, metformin plus sitagliptin and oral iron who was referred to our Emergency Department for hematochezia.

For the investigation of the iron-deficiency anemia an endoscopic study had been conducted two months before, which included: an esophagogastroduodenoscopy (EGD), where small esophageal varices and mucosal changes compatible with mild portal hypertensive gastropathy were found; and a colonoscopy, where the colonic mucosa was diffusely altered by the presence of edema, erythema, angiectasia (Fig. 1) and varices (Fig. 2) and a diagnosis of PHC was established.

On admission the patient was conscious and hemodynamically stable and the blood analysis demonstrated an acute anemia with a hemoglobin of 8.3 g/dL, platelets of 75,000/ μ L and an INR of 1.3. A colonoscopy was performed

which showed hematochezia from the rectum to the transverse colon and the already known mucosal changes. It was assumed that the CPH was the cause of the lower gastrointestinal bleeding (LGIB). The patient was started on octreotide perfusion for 5 days, along with antibiotic prophylaxis with ceftriaxone. Two days later he showed another episode of LGIB, but this time with hemodynamic instability and a profound drop on hemoglobin to a minimum of 6.2 g/dL. To exclude an upper source of the hemorrhage he was submitted to an EGD, which was superimposable to the other one, with no blood. Thereafter the patient had an uneventful stay at the hospital and he was discharged with

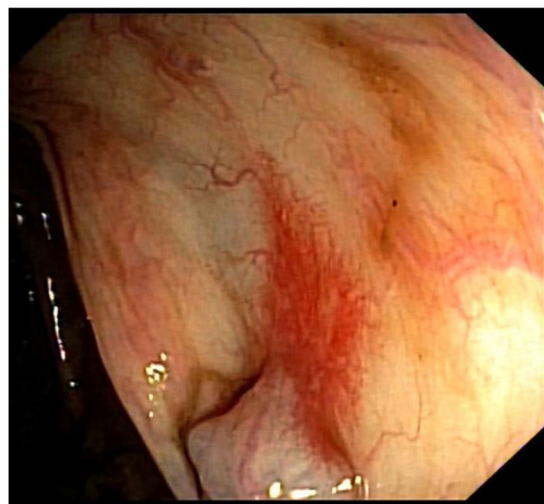


Figure 1 Colonoscopy showing typical findings of portal hypertensive colopathy: erythema and angiectasia.