



CIRUGÍA y CIRUJANOS

Órgano de difusión científica de la Academia Mexicana de Cirugía
Fundada en 1933

www.amc.org.mx www.elsevier.es/circir



LETTERS TO THE EDITOR

Pancreatic pseudoaneurysms: Forms of presentation and therapeutic options[☆]



Seudoaneurismas pancreáticos: formas de presentación y opciones terapéuticas

Dear Editor,

We read with great interest the article signed by Herrera-Fernández et al.¹ published in your prestigious journal, and since we have had the opportunity to treat 2 patients with pancreatic pseudoaneurysm with diametrically opposing forms of presentation and resolution,² we write to you to record our experience and put forward a series of considerations.

Our series covered the 2 most frequent forms of onset: the first being hypovolaemic shock due to vascular rupture (splenic artery), which can be diagnosed by mesenteric arteriography (Fig. 1), and the second being intense, recurring, and occasionally, shooting abdominal pain, discovered by means of computed axial angio-tomography scan (angio CAT).

We agree with the authors that this condition can be suspected if a patient presents with a history of alcoholic pancreatitis and severe, recurrent abdominal pain, and that the angio-CAT scan is the diagnostic tool of choice.

Although it used to be considered that the usual treatment was surgery, nowadays whenever possible, the therapy of choice is endovascular embolisation of the aneurysm via angiographic access, as our colleagues rightly note. This is effective in up to 80% of occasions, and surgery is reserved for when this technique cannot be undertaken due to the patient's haemodynamic instability or if the technique fails.³

Lastly, we wish to note that direct puncture and embolisation of the aneurysm via laparotomy have been

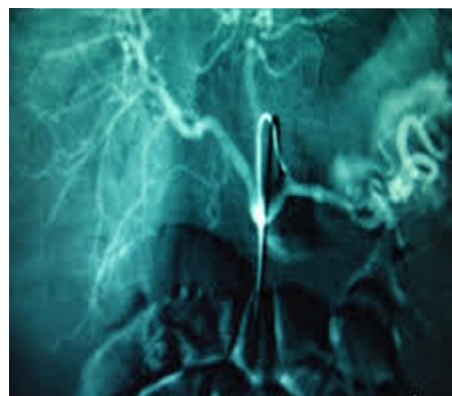


Figure 1 Vascular rupture (splenic artery), which can be diagnosed by mesenteric arteriography.

described,⁴ as well as percutaneous puncture and intra-aneurysmal thrombin injection.⁵

References

1. Herrera-Fernández FA, Palomeque-Jiménez A, Serrano-Puche F, Calzado-Baeza SF, Reyes-Moreno M. Ruptura de pseudoaneurisma de la arteria esplénica: una causa poco frecuente de hemorragia digestiva alta. *Cir Cir.* 2014;82:551–5.
2. Vázquez-Ruiz J, Mansilla-Molina D, Civera-Muñoz JF, Fernández-Moreno J, Pérez-Folqués JE, Guirao-Manzano J. Opciones terapéuticas en los pseudoaneurismas pancreáticos. *Rev Esp Enferm Dig.* 2012;104:502–3.
3. Pacheco-Jiménez M, Moreno-Sánchez T, Moreno-Rodríguez F, Guillen-Rico M. Seudoaneurisma de la cola pancreática: tratamiento percutáneo mediante inyección de trombina. *Radiología.* 2014;56:167–70.
4. García-Vila JH, Bordón F, Redondo M, Díaz C, Salvador JL. Tratamiento de seudoaneurisma pancreático por punción directa y embolización. *Radiología.* 2001;43:79–81.
5. Vujic I. Vascular complications of pancreatitis. *Radiol Clin N Am.* 1989;27:81–91.

[☆] Please cite this article as: Vázquez-Ruiz J, López-Flor V, Aguado-Pérez M, Fernández-Moreno J, Pérez-Folqués JE, Mansilla-Molina D. Seudoaneurismas pancreáticos: formas de presentación y opciones terapéuticas. *Cir Cir.* 2015;83:454–455.

José Vázquez-Ruiz*, Vicente López-Flor,
Marta Aguado-Pérez, José Fernández-Moreno,
José Eduardo Pérez-Folqués, Diego Mansilla-Molina

*Servicio de Cirugía General y del Aparato Digestivo,
Hospital Virgen del Castillo, Yecla, Murcia, Spain*

*Corresponding author at: Servicio de Cirugía General,
Hospital Virgen del Castillo, Avda. de la Feria, s/n, 30510
Yecla, Murcia, Spain. Tel.: +36 9687 19800/6095 90209;
fax: +36 9687 19806.
E-mail address: vasquesito@gmail.com (J. Vázquez-Ruiz).

Pancreatic pseudoaneurysms: Forms of presentation and therapeutic options[☆]



Respuesta a Carta l Editor: Pseudoaneurismas pancreáticos: formas de presentación y opciones terapéuticas

Dear Editor,

We are grateful for the comments from the authors in relation to our article which was recently published in *Cirugía y Cirujanos*, referring to the different forms of presentation and therapeutic options for pancreatic pseudoaneurysms.

Indeed, although in our case the form of presentation was hypovolaemic shock, with the peculiarity that it manifested as a high digestive haemorrhage, presentation in the form of varying intensity of abdominal pain is also possible, as the authors describe well in one of the cases of their series.

Whatever the form of presentation, imaging tests, essentially the angio-CT scan, provide a firm diagnosis.

Although our case was resolved using surgery due to the patient's instability, and the impossibility of performing arteriography in our hospital, the latter combined with embolisation is the therapeutic option of choice. Furthermore, as our colleagues mention, direct puncture techniques of the pseudoaneurysm via laparotomy or percutaneously, and the injection of embolising substances have been demonstrated to be equally effective. The latter being

more indicated for patients for whom surgery poses a high risk, where cannulation or identification via arteriography of the vessel supplying the pseudoaneurysm have failed. In these cases, percutaneous injection of human thrombin, guided by ultrasound or computed axial tomography, has achieved excellent results.¹

Reference

1. Barbiero G, Battistel M, Susac A, Miotto D. Percutaneous thrombin embolization of a pancreaticoduodenal artery pseudoaneurysm after falling of the endovascular treatment. *World J Radiol.* 2014;6:629–35.

Francisco Antonio Herrera-Fernández^a,
Antonio Palomeque-Jiménez^{a,*}, Félix Serrano-Puche^b,
Salvador Francisco Calzado-Baeza^a,
Montserrat Reyes-Moreno^a

^a *Servicio de Cirugía General y Digestiva, Hospital Santa Ana, Motril, Granada, Spain*

^b *Servicio de Radiología, Hospital Santa Ana, Motril, Granada, Spain*

*Corresponding author at: Plaza Ciudad de los Cármes,
Bloque 1, num. 3, 6F, 18013 Granada, Spain.
Tel.: +34 66 59 08 365.
E-mail address: apalomeque2002@hotmail.com
(A. Palomeque-Jiménez).

[☆] Please cite this article as: Herrera-Fernández FA, Palomeque-Jiménez A, Serrano-Puche F, Calzado-Baeza SF, Reyes-Moreno M. Respuesta a Carta l Editor: Pseudoaneurismas pancreáticos: formas de presentación y opciones terapéuticas. *Cir Cir.* 2015;83:455.