



Maxillary protraction through skeletal anchorage in growing patients. Literature review

Protracción maxilar mediante anclaje esquelético en pacientes clases III en crecimiento. Revisión bibliográfica

Irving Giovanni Huízar González,* Eliezer García López§

ABSTRACT

Early treatment of skeletal Class III patients is usually handled with the use of maxillary protraction face mask. The results of this orthopedic therapy are often accompanied by adverse dentoalveolar effects. An alternative treatment is skeletal anchorage comprised of temporary anchorage devices (TADs), which uses two titanium plates fixed with mini implants placed in the zygomatic process of the maxilla and two side plates between the lower canine and right and left and the use of intermaxillary elastics. This results in maxillary advancement and improvement of facial aesthetics while reducing dentoalveolar adverse effects.

Key words: Maxillary protraction, skeletal anchorage, skeletal class III.

Palabras clave: Protracción maxilar, anclaje esquelético, clase III esquelético.

RESUMEN

El tratamiento temprano de pacientes clases III esquelético generalmente se maneja con el uso de la máscara facial de protracción maxilar, en el cual los resultados de esta terapia ortopédica frecuentemente son acompañados de efectos dentoalveolares desfavorables. Una alternativa de tratamiento es el anclaje esquelético comprendido de dispositivos de anclaje temporal, el cual utiliza dos placas de titanio fijadas con mini-implantes colocadas en los procesos cigomáticos de los maxilares y dos placas entre el lateral y canino inferior derecho e izquierdo, además del uso de elásticos intermaxilares, obteniendo como resultado un avance maxilar y mejoramiento de la estética facial y disminuyendo los efectos dentoalveolares desfavorables.

INTRODUCTION

Maxillary protraction with the use of facemask at early ages is the treatment of choice for skeletal class III patients. Such treatment generates a positive overjet through the combination of dentoalveolar and skeletal movements, since the forces are applied mainly to the teeth 12 to 16 hours per day for 9 to 12 months, causing undesirable effects.¹

Short-term studies of maxillary protraction have shown only limited effects on mandibular advancement (2-3 mm on average) in addition to a posterior mandibular rotation and dentoalveolar changes (proclination of the maxillary incisors, mesialization and extrusion of maxillary molars and retroclination of mandibular incisors).² Long-term results of maxillary protraction indicate that there is a relapse rate of 25%-33% of patients which presented a negative overjet relapse. In this kind of treatment orthopaedic effects must be maximized since dentoalveolar changes are those that present the greatest relapse.³

However, a small number of patients with skeletal class III problems will ultimately require orthognathic

surgery, which is why any treatment that can eliminate or reduce the extent of the problem is of great help.⁴

Skeletal anchorage in growing patients

In recent years there has been an increase in the use of temporary anchorage devices (TADs), which are often used in orthognathic surgery and fracture fixation. Skeletal anchorage devices have been used successfully in orthodontics to achieve multiple movements such as dental intrusions, open bite correction, molar distalization, etc. and in recent studies they have been given applications in orthopaedic treatments.⁵

Kokich in 1985 introduced the use of absolute anchorage to achieve maxillary protraction. He used

* Resident of the Orthodontics Specialty.

§ Master in Science. Head of the Orthodontics Specialty.

University Center of Health Sciences, Guadalajara University.

This article can be read in its full version in the following page:
<http://www.medigraphic.com/ortodoncia>

protraction forces with the use of a facemask and intentionally used as anchorage anquilosed deciduous canines with the aim of treating a patient with maxillary deficiency.⁶ Afterwards, Smalley experimented with osseointegrated implants for the maxillary protraction in monkeys using a force of 600 g per side to stimulate circumaxillary sutures. An anterior displacement of 8 mm was obtained.⁷ Singer placed mini implants in the zygomatic processes of the maxillae implementing 400 g of force to a child with sequelae of cleft lip and palate (maxillary retrusion) thus obtaining as a result a maxillary advancement of 4 mm as well as a descent due to the vector of force application. Additionally, an improvement in the patient's profile was caused by a posterior mandibular rotation.⁸

Indications for skeletal anchorage

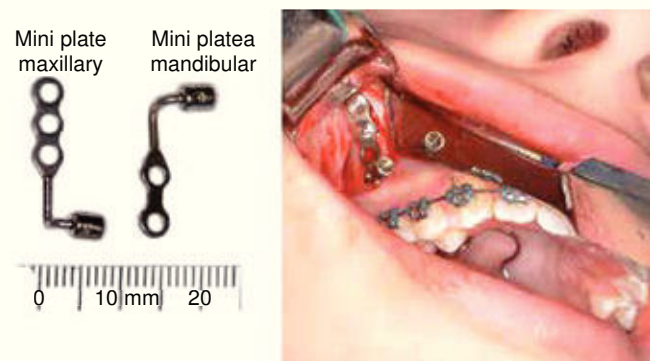
TADs as skeletal anchorage are used in skeletal class III patients with hypoplasia of the maxilla determined by cephalometric analysis and soft tissue profile evaluation, in addition to presenting molar class III and negative overjet. These patients must be between the ages of 9 to 14 years in a pre-pubertal period.⁹

The surgical procedure described by Dr. Hugo De Clerck consists in the placement of four mini plates placed in each one of the maxillary zygomatic processes. The mini plates are going to generate a force vector that passes through the nasomaxillary complex stimulating the circumaxillary sutures. In the lower arch one mini plate is placed on each side of the anterior region of the mandible between the right and left permanent lateral incisor and permanent canine. Fixation of the plates is achieved with three mini implants for the maxilla and two for the mandible. In order to perform a correct positioning of the lower plates it must be to certain that the canine has already erupted so as to prevent any damage when inserting the mini implant (*Figure 1*). One should wait 2 to 3 weeks for the process of tissue healing and afterwards, apply orthopedic forces.¹⁰

The orthopedic protocol mentions that after three weeks one must apply intermaxillary elastics on each side with a class III force vector, which will move the maxilla forward and downwards and the mandible backwards and upwards (*Figure 2*). The initial elastics must exert a force of 150 g on each side and after the first month it will increase to 250 grams with the same vector. To determine the force the patient must be at maximum intercuspation. The duration of orthopedic traction is 12.5 months with a range of 9 to 14 months of 24 hour use. An acrylic plate or placement of resin

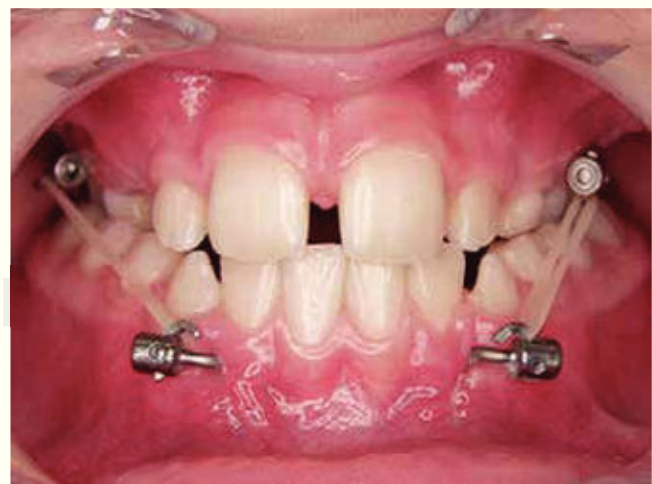stops to increase vertical dimension and achieve overjet might also be used. The orthodontist will determine the ideal time to remove the elastics, usually upon achieving a positive overjet.⁹

To perform an accurate positioning of the plates a cone beam CT scan (CBCT) must be used for detecting the most calcified areas of the zygomatic process of the maxilla for proper mechanical retention of the mini implants. The best plate stability is achieved in patients of at least 11 years of age. Additionally, the use of CBCT may be useful to assess maxillary advancement in this kind of treatment before (T1) and a year after setup of orthopedic mechanics (T2), with the aid of super impositions of three-dimensional



(Taken from: «Three-dimensional Analysis of Maxillary Protraction with Intermaxillary Elastics to Miniplates». Heymann, 2010).

Figure 1. Modification of temporary anchorage devices (TADs).



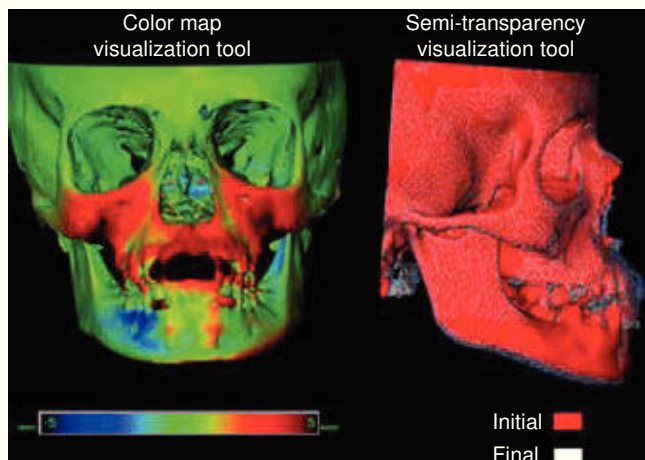
(Taken from: «Three-dimensional Analysis of Maxillary Protraction with Intermaxillary Elastics to Miniplates». Heymann, 2010).

Figure 2. Use of class III vector intermaxillary elastics.

images and evaluating the actual progress of maxillary protraction (*Figure 3*).

CBCT images must assess the following anatomical regions:

- 1) Anterior region of the maxilla (point A)
- 2) Zygomatic process of the maxilla
- 3) Most anterior region of the mandible (pogonion)
- 4) Anterior and posterior surface of the condyles



(Taken from: «Three-dimensional analysis of maxillary protraction with intermaxillary elastics to miniplates». Heymann, 2010).

Figure 3. CBCT superimposition at T1 and T2.

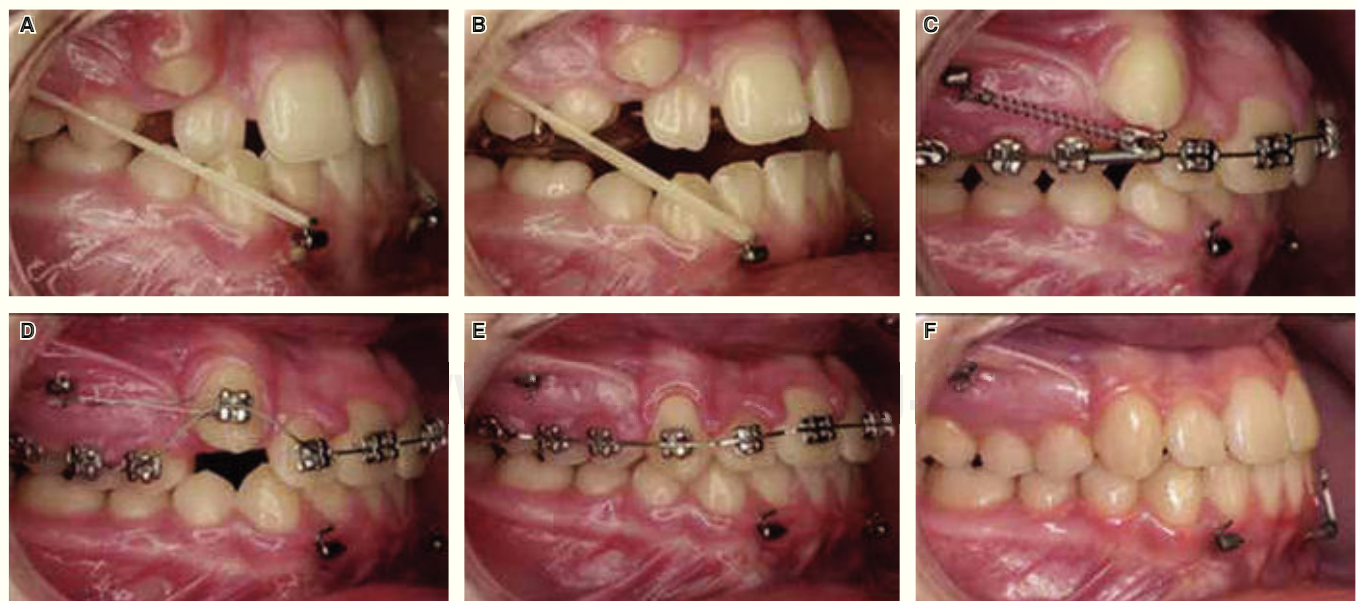
- 5) Lower ridge of the mandible
- 6) Glenoid fossa
- 7) Soft tissues¹¹

It has been clinically proven that the continuous forces exerted by the intraoral intermaxillary elastics over TADS in skeletal class III patients have better results than the use of intermittent forces of extraoral elastics with the facemask.¹²

Generally patients who are skeletal class III with an antero-posterior deficiency of the maxilla lack space for canine eruption, that is why once overjet is achieved molar and premolar distalization movements may be performed to obtain space and thus position the canines in the arch (*Figure 4*).

DISCUSSION

Orthopedic procedures with the use of skeletal anchorage in growing patients offers major advantages regarding aesthetics, function and long term stability. The use of intermaxillary elastics improves facial and skeletal relations in addition to diminishing the effects that cause dentoalveolar relapse. In some cases the implementation of this technique may be sufficient to avoid orthognathic surgery in the future or at least reduce the severity of the surgical correction after the patient has completed growth. Growing patients who undergo this procedure easily adapt to the



(Taken from: «Growth modification of the face: A current perspective with emphasis on class III treatment». De Clerk, 2015).

Figure 4. A. Class III intermaxillary elastics; B. bite plane to achieve overjet; C-E. distalization mechanics; F. post-treatment.

aesthetic changes that are gradually manifested unlike orthognathic surgery post-surgical changes which occur almost immediately.

REFERENCES

1. Enacar A, Giray B, Pehlivanoglu M, Iplikcioglu H. Facemask therapy with rigid anchorage in a patient with maxillary hypoplasia and severe oligodontia. *Am J Orthod Dentofacial Orthop.* 2003; 123 (5): 571-577.
2. Gallagher RW, Miranda F, Buschang PH. Maxillary protraction: treatment and posttreatment effects. *Am J Orthod Dentofacial Orthop.* 1998; 113 (6): 612-619.
3. Westwood PV, McNamara JA Jr, Baccetti T, Franchi L, Sarver DM. Long-term effects of Class III treatment with rapid maxillary expansion and facemask therapy followed by fixed appliances. *Am J Orthod Dentofacial Orthop.* 2003; 123: 306-320.
4. Wells AP, Sarver DM, Proffit WR. Long-term efficacy of reverse pull headgear therapy. *Angle Orthod.* 2006; 76: 915-922.
5. Cornelis MA, Scheffler NR, De Clerck HJ, Tulloch JF, Behets CN. Systematic review of the experimental use of temporary skeletal anchorage devices in orthodontics. *Am J Orthod Dentofacial Orthop.* 2007; 131: 52-58.
6. Kokich VG, Shapiro PA, Oswald RJ, Koskinen-Mottelt L, Clarren SK. Ankylosed teeth as abutments for maxillary protraction. A case report. *Am J Orthod.* 1985; 88: 303-307.
7. Smalley WM, Shapiro PA, Hohl TH, Kokich VG, Brånemark P. Osseointegrated titanium implants for maxillofacial protraction in monkeys. *Am J Orthod Dentofacial Orthop.* 1988; 94: 285-295.
8. Singer SL, Henry PJ, Rosenberg I. Osseointegrated implants as an adjunct to face mask therapy: a case report. *Angle Orthod.* 2000; 70: 253-262.
9. De Clerck HJ, Proffit WR. Growth modification of the face: A current perspective with emphasis on Class III treatment. *Am J Orthod Dentofacial Orthop.* 2015; 148 (1): 37-46.
10. Cornelis MA, Scheffler NR, Mahy P, Siciliano S, De Clerck HJ, Tulloch JF. Modified miniplates for temporary skeletal anchorage in orthodontics: placement and removal surgeries. *J Oral Maxillofac Surg.* 2008; 66: 1439-1445.
11. Heymann GC, Cevidanes L, Cornelis M, De Clerck HJ, Tulloch JF. Three-dimensional analysis of maxillary protraction with intermaxillary elastics to miniplates. *Am J Orthod Dentofacial Orthop.* 2010; 137 (2): 274-284.
12. Liu SS, Kyung HM, Buschang PH. Continuous forces are more effective than intermittent forces in expanding sutures. *Eur J Orthod.* 2010; 32: 371-380.

Mailing address:

Irving Giovanni Huizar González

E-mail: giov_irving@hotmail.com