



Class II division 1 correction with maxillary second premolar extractions. Case report

Corrección de clase II división 1 con extracciones de segundos premolares maxilares. Reporte de un caso

Diana Graciela Dávila Garza, Andrés Vázquez Landaverde,
Mónica Ortiz Villagómez, Alba Patricia Campos Ramírez

ABSTRACT

Introduction: Class II-1 can be the result of a retrognathic mandible, a prognathic maxillary or both. Nowadays, there are several ways for class II treatment: maxillary first bicuspid extractions that can also include the extraction of one lower incisor or the first or second mandibular bicuspid, depending the case, or even the extraction of the second maxillary bicuspid as well. **Objectives:** To achieve canine class I, correct the midline discrepancy, the excessive overjet and to improve the patient's aesthetics. **Case report:** Female patient of 32.6 years of age who had a previous orthodontic treatment with extractions of the first maxillary and mandibular bicuspid presents absence of the maxillary second bicuspid, generalized mild chronic periodontitis and previous mental foramen fracture with mentoplasty. **Conclusions:** The 2nd bicuspid extraction was the best alternative to avoid another surgery, with a significant change in the patient's profile, improving her expectations and self-esteem.

Key words: Class II-1, second maxillary bicuspid extractions.

Palabras clave: Clase II-1, segundos premolares maxilares.

RESUMEN

Introducción: La clase II-1 puede ser resultado de una mandíbula retrognata, de un maxilar prognato o de una combinación de ambas. Actualmente existen alternativas de tratamiento, como las extracciones de primeros premolares que en ocasiones se pueden acompañar de una extracción de incisivo central inferior o de segundos premolares inferiores, e incluso la extracción de los segundos premolares superiores, según sea el caso. **Objetivos:** Establecer clase I canina, corregir la línea media dental y el traslape horizontal, así como mejorar el perfil de los tejidos blandos. **Reporte del caso:** Paciente del sexo femenino de 32.6 años de edad. Presenta tratamiento ortodóncico previo con extracciones de primeros premolares superiores e inferiores, ausencia del segundo premolar superior izquierdo, periodontitis crónica leve generalizada y antecedentes de fractura en la sínfisis mentoniana con reconstrucción (mentoplastia). **Conclusiones:** La extracción del segundo premolar maxilar fue la alternativa viable para evitar otra cirugía con un cambio significativo en el perfil, mejorando las expectativas y, especialmente, la autoestima de la paciente.

INTRODUCTION

Class II division 1 is characterized because the buccal groove of the permanent lower molar is located distal to the mesiobuccal cusp of the upper first molar with protrusive incisors and increased overjet. It may be the result of a retrognathic mandible, a protrusive maxilla or a combination of both.¹ Since time immemorial, biprotrusions were mentioned as an etiology for trying to correct the Class II through extractions thus improving facial aesthetics.²

Among the treatment options for class II-1 correction, the most frequent is the extraction of the four first premolars since they are located in the anterior segments of the dental arches which allows direct access to crowding and severe dentoalveolar

protrusions correction. Another alternative is the removal of the first maxillary premolars and the second mandibular premolars. It is used in cases of dental and skeletal class II division 1 with severe upper anterior crowding or mild to moderate dentoalveolar protrusion and with a mandibular arch without many anterior problems. Extractions have an influence over the anterior lower facial height and they diminish vertical dimension.³ Through several studies it has been found that due to the light and controlled forces of current

* Universidad Autónoma de Querétaro.

This article can be read in its full version in the following page:
<http://www.medigraphic.com/ortodoncia>

therapies, the retraction of six, eight and even ten teeth is possible when performing extractions.⁴ In some patients, the solution is orthognathic surgery, however, due to different causes this treatment is not viable and permanent bicuspid and/or molar extractions have to be performed as orthodontic camouflage.^{5,6}

CASE REPORT

Female patient of 32.6 years of age that attends the Orthodontics Clinic at the Faculty of Medicine of the Autonomous University of Querétaro with the following chief complaint: «improve my smile because my teeth stick out too much» (*Figure 1*).

Clinical examination

The patient presents a mesofacial pattern, straight profile with slight lower lip proclia and lip incompetence. At the intraoral clinic examination, the patient presented two fixed prostheses of 3 metal ceramic units, one in the upper arch from canine to upper left first molar (pontic of second premolar); and in the lower dental arch, from first to second molar premolar on the left (a one unit pontic covering the second premolar and first molar); molar and canine class II on both sides, 7 mm overjet, and 1 mm overbite, upper dental midline deviation to the left and mild generalized chronic periodontitis (*Figure 2*).

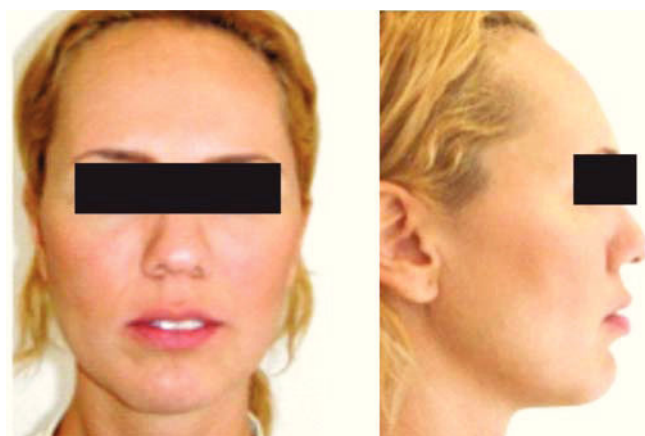

Figure 1. Pretreatment facial photographs.

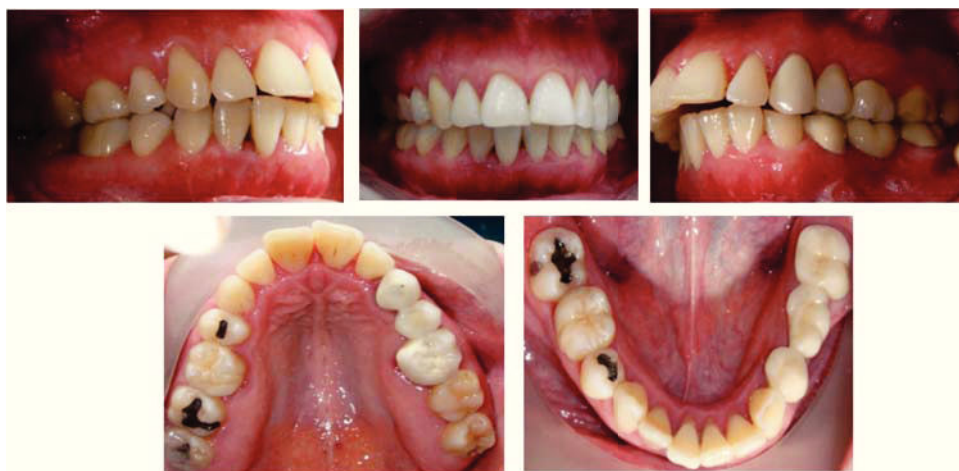

Figure 2.

Pretreatment intraoral photographs.

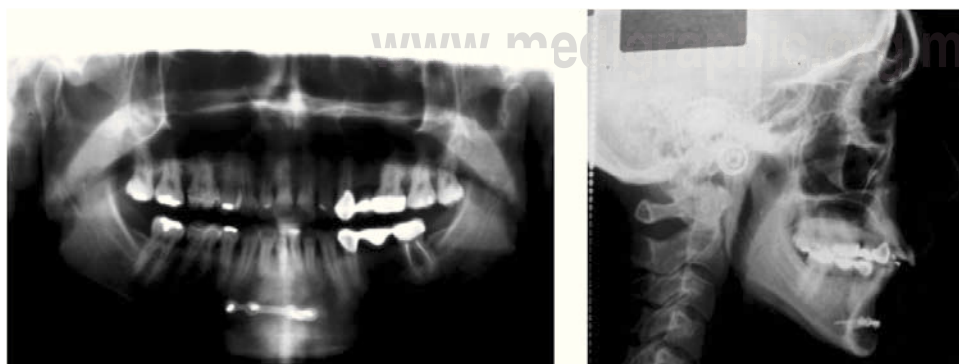


Figure 3.

Initial panoramic radiograph and lateral headfilm.

Radiographic examination

The panoramic X-ray shows history of fracture in the symphysis menti with reconstruction (mentoplasty) and a previous orthodontic treatment with extractions of first premolars and lower second premolars, and absences of the upper left second premolar, lower left first molar and lower third molars.

The cephalometric analysis revealed a class II-1 by retrognathism, neutral growth, upper and lower incisor proclination and dentoalveolar protrusion with a tendency towards open bite (*Figure 3*).

Diagnosis

- Female patient of 32.6 years of age.
- Skeletal class I.
- Straight profile with lip incompetence.
- Neutral growth.
- Molar and canine class II.
- 1 mm overbite and 7 mm overjet (*Figure 4*).
- Upper dental midline deviated to the left.
- Upper and lower incisor proclination and protrusion.

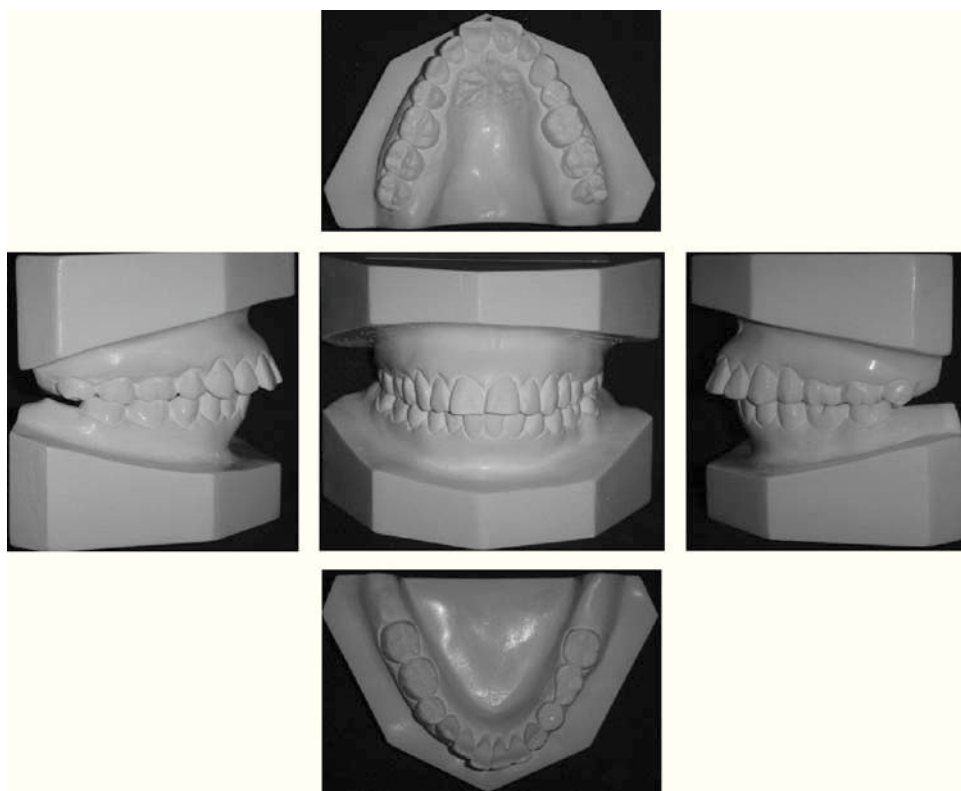


Figure 4.

Initial study models.

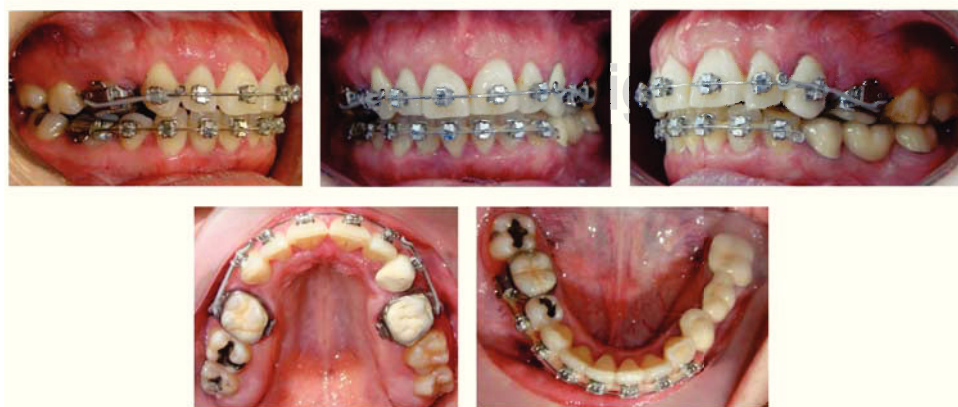

Figure 5.

Intraoral treatment photographs: right side, frontal view, left side and upper and lower occlusal photographs.

Specific objectives

- To achieve canine class I.
- To correct dental midline.
- To correct the overjet.
- To obtain lip competence.
- To improve the soft tissue profile.

Treatment plan

- Segment the lower porcelain bridge respecting the porcelain crowns of the pillar teeth.
- Extraction of the upper right second bicuspid.
- Place Tip-Edge appliances.

TREATMENT

The patient is referred to the Prosthetics Department for sectioning the porcelain bridge and eliminate the pontic of the upper left second premolar while

respecting the porcelain crowns of the pillar teeth and to extract the upper right second premolar.

Phase I: Tip-Edge bracket and bands placement (except in the lower left second molar) with 0.016" NiTi upper and lower arches. Six weeks later, it was changed for a 0.016" Australian arch with an helix mesial to the canines and a tip-back bend 3 mm mesial to the gingival tubes and with the use of 5/16" 2 oz Class II elastics.

Phase II: 0.020" Australian upper and lower arches were placed with a helix mesial to the canines and began with the use of E-links for space closure (*Figure 5*).

Phase III: 0.021" x 0.025" archwires with Side Winder attachments for root uprighting and torque expression with the characteristics of a straight archwire system (*Figure 6*). Final detailing and settling of the occlusion. The appliances were removed and removable retainers were placed in the upper and lower arches.

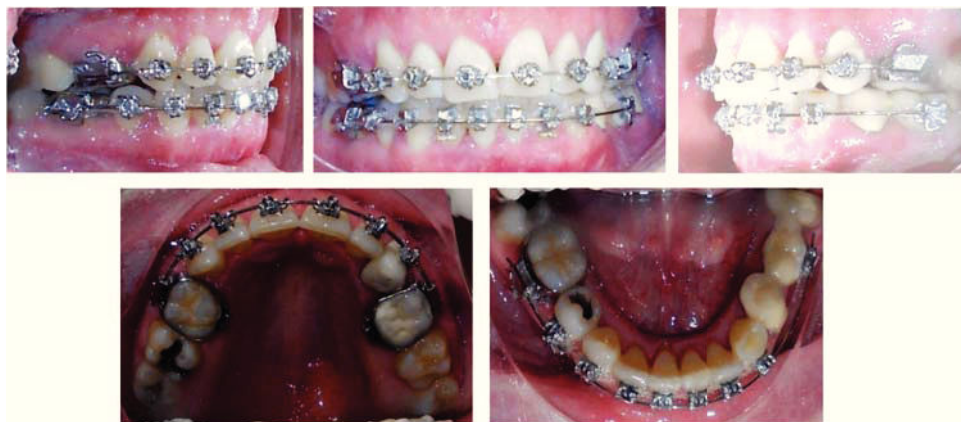

Figure 6.

Transoperative intraoral photographs right side, frontal view left side and upper and lower occlusal photographs.

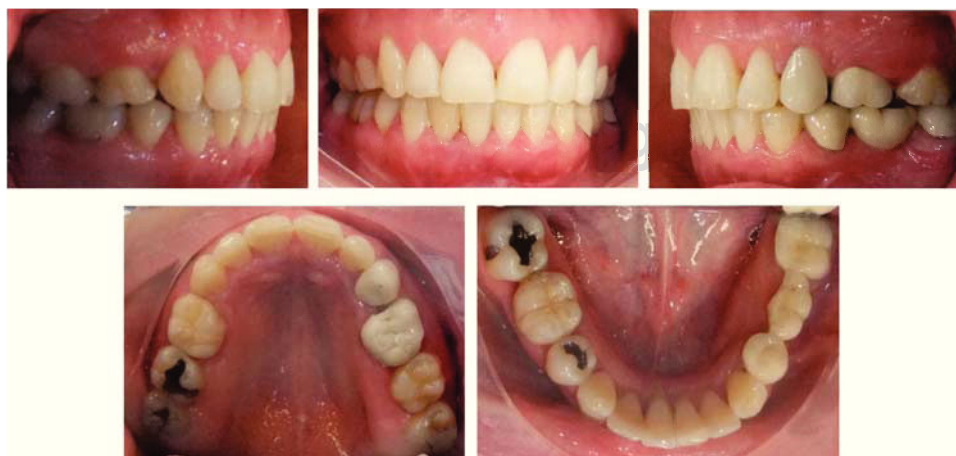

Figure 7.

Final intraoral photographs.

RESULTS

With this treatment, a canine class I was achieved, the midline was centered, an adequate overjet and overbite were obtained along with functional guides, periodontal health and improvement of the patient's profile by achieving lip competence (Figures 7 to 9).

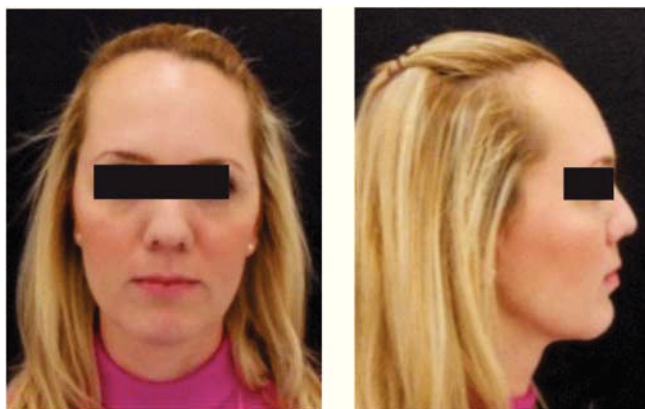

Figure 8. Final facial frontal and right profile photographs.

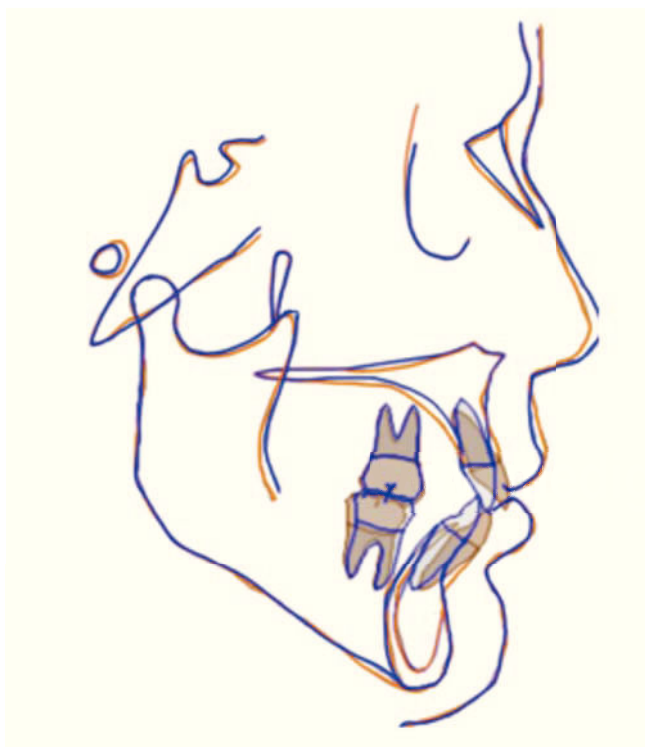


Figure 9. Pre and post-treatment superimposition.

DISCUSSION

According to the studies of Raleigh and Kesling, the decision to perform extractions depends on the position of the lower incisor with the A-Po line or the denial of the patient for orthognathic surgery.⁷ Oynick mentions that in biprotrusive patients, the result perception improves when treated with extractions.⁸ Proffit mentions that the treatments can be performed with or without extractions when the aesthetics is affected, due to the great influence of inheritance in the etiology of the malocclusions.⁹

CONCLUSIONS

Nowadays the need for extractions in patients with partial anodontia might be controversial because of the existing surgical techniques or implants. When extractions are required, the orthodontist must take very careful decisions in treatment planning and in biomechanics and be alert especially with molar control.

The case presented hereby presented was diagnosed as a surgical treatment and the decision was made to perform treatment with the extraction of the remnant premolar, moving the anterior teeth to a more harmonious position with the AP line and the facial profile, being a less radical alternative than surgery with a significant change in the profile and in doing so, improving the expectations and especially the self-esteem of the patient.

REFERENCES

1. Gregoret J et al. *Ortodoncia y cirugía ortognática: diagnóstico y planificación*. Barcelona: Ed. Espaxs, S.A. Publicaciones Médicas; 1997.
2. Case CS. The question of extraction in orthodontia (reprint). *Am J Orthod*. 1964; 50: 660-691.
3. Uribe-Restrepo G. *Ortodoncia. Teoría y Clínica*. Colombia: Corporación para Investigaciones Biológicas; 2004.
4. Rodríguez E. *Ortodoncia contemporánea diagnóstico y tratamiento*. México: Ed. Amolca; 2004. pp. 117-129.
5. Raleigh-Williams. The diagnostic line. *Am J Orthod Dentofacial Orthop*. 1969; 55 (Issue 5): 458-476.
6. Rocke T. Empleando los brackets Tip-Edge en los caninos para simplificar la mecánica de arco recto. *Am J Orthod Dentofacial Orthop*. 2004; 106: 341-350.
7. Kesling P, Rocke T, Kesling C. Tratamiento con brackets Tip-Edge y movimiento dental diferencial. *Am J Orthod Dentofacial Orthop*. 1994; 99: 387-401.
8. Oynick CA. The impact of orthodontic treatment on perceived facial esthetics [thesis]. St. Louis, Mo: Saint Louis University; 1998.
9. Proffit W. *Ortodoncia. Teoría y práctica*. 2a. ed. Madrid, España: Ed. Mosby/Doyma Libros; 1994.

RECOMMENDED READINGS

- Muñoz-Morente RJ, Ferrer-Molina M. Efectos de las extracciones de premolares en la anchura de arcada. *Revista Española de Ortodoncia*. 2004; 34 (3): 219-224.
- Castillo R, Grau R, Caravia F. Relaciones entre las maloclusiones y los desórdenes craneomandibulares. *Revista Cubana de Ortodoncia*. 1995.
- Muñoz-Morente RJ, Ferrer-Molina M. Extracción frente a no extracción: efecto en la estética del perfil. *Revista Española de Ortodoncia*. 2004; 44 (4): 3-13.
- Bishara S, Cummins D, Zaher A. Treatment and posttreatment changes in patients with class II division 1 malocclusion after extraction and nonextraction treatment. *Am J Orthod Dentofacial Orthop*. 1997; 111 (1): 18-27.
- Janson G, Da Costa A, Castanha J, De Freitas M, Santos L. Class II treatment success rate in 2 and 4 premolar extraction protocols. *Am J Orthod Dentofacial Orthop*. 2004; 125 (4): 472-479.
- Basciftci F, Usumez S. Effects of extraction and nonextraction treatment on class I and class II subjects. *Angle Orthod*. 2003; 73 (1): 36-42.
- Tadic N, Woods M. Incisal and soft tissue effects of maxillary premolar extraction in class II treatment. *The Angle Orthodontist*. 2007; 77 (5): 808-816.
- Bishara S, Bayati P, Zaher A, Jakobsen J. Comparisons of the dental arch changes in patients with Class II, division 1 malocclusions: extraction versus nonextraction treatments. *The Angle Orthodontist*. 1994; 64 (5): 351-358.
- Zierhut E, Joondeph D, Artun J, Little R. Long-term profile changes associated with successfully treated extraction and nonextraction class II division 1 malocclusions. *The Angle Orthodontist*. 2000; 70 (3): 208-219.
- Janson G, Alvares E, Castanha J, De Freitas M, Rodríguez K. Class II subdivision treatment success rate with symmetric and asymmetric extraction protocols. *Am J Orthod Dentofacial Orthop*. 2003; 124 (3): 257-264.
- Chung K, Cho J, Kim S, Kook Y, Cozzani M. Unusual extraction treatment in class II division 1 using C-orthodontic mini-implants. *The Angle Orthodontist*. 2007; 77 (1): 155-166.
- Kinzinger G, Frye L, Diedrich P. Class II treatment in adults: comparing camouflage orthodontics, dentofacial orthopedics and orthognathic surgery – a cephalometric study to evaluate various therapeutic effects. *Journal of Orofacial Orthopedics*. 2008; 69: 63-91.

Mailing address:

Mónica Ortiz Villagómez

E-mail: orto@vaq.mx