



Pre-surgical orthopedics in newborn patients with cleft lip and palate

Ortopedia prequirúrgica en pacientes recién nacidos con labio y paladar hendido

Nataly Lopera Restrepo,* José Ramón Hernández Carvallos§

ABSTRACT

Introduction: Cleft lip and palate is the most common craniofacial malformation of the world's population, causing a great impact on society since it compromises both aesthetics and function. Presurgical orthopedic treatment at an early age limits the consequences of this anomaly. **Objective:** To describe two cases of male newborn patients diagnosed with unilateral and bilateral cleft lip and palate that underwent early pre-surgical orthopedic treatment. **Methods:** Initially Friedman's stimulation plate was used to confront the alveolar ridges less than 5 mm to continue subsequently with the formation of the nasal wings which were depressed. **Results:** The alveolar fissures were closed completely in both cases in addition to lengthening the columella, increasing the size of the depressed nostril, as well as improving the perioral muscle tone thus enhancing the results of the cheiloplasty. **Conclusions:** Early preoperative treatment in infant patients with cleft lip and palate is a successful alternative for achieving closure of lip-alveolar-palatal clefts, with the aid of a skilled operator and committed to treatment parents.

RESUMEN

Introducción: El labio y paladar hendidos es la malformación craneofacial más común en la población mundial, causando un gran impacto en la sociedad porque compromete tanto la parte estética como funcional. La ortopedia prequirúrgica es un tratamiento que interviene en edades tempranas para la disminución de las secuelas de esta anomalía. **Objetivo:** Describir dos casos de pacientes género masculino recién nacidos con diagnóstico de labio y paladar hendidos unilateral y bilateral completo a quienes se les realizó tratamiento temprano con ortopedia prequirúrgica. **Métodos:** Se utilizó inicialmente placa estimuladora de Friedman para afrontar los procesos alveolares a menos de 5 mm, para continuar posteriormente con la conformación de las alas nasales que se encontraron deprimidas. **Resultados:** Se cerraron las fisuras alveolares completamente en ambos casos, se estimuló el cierre de la fisura del paladar, además de elongar la columela, aumentar el tamaño de la ventana de la nariz que se encontró deprimida y se logró la tonicidad muscular perioral adecuada para mejorar los resultados de la queiloplastia. **Conclusiones:** El tratamiento temprano prequirúrgico en los pacientes recién nacidos con labio y paladar hendidos, es una alternativa exitosa en el cierre de la fisura labio alveolopalatina, con la ayuda de un operador habilidoso y unos padres comprometidos con el tratamiento.

Key words: Cleft lip and palate, pre-surgical orthopedic treatment, nasoalveolar molding.

Palabras clave: Labio y paladar hendidos, ortopedia prequirúrgica, conformación nasal.

INTRODUCTION

Cleft lip and palate is the craniofacial anomaly with the highest incidence; it represents approximately 1:500 of global population and in Mexico, 1:700 alive newborns,^{1,2} depending on racial and geographic conditions. These malformations are defects that compromise both the anatomical and functional part with great aesthetic involvement. Additionally, the psychological component influences the family and social environment. The etiological basis of this disorder includes the interaction of several factors such as: drug ingestion in the first trimester of pregnancy (anticonvulsants, benzodiazepines, salicylates); infectious factors such as viral and bacterial diseases; nutritional deficits and irradiation which has demonstrated its teratogenic effect.

Pre-surgical orthopedics has evolved and improved with the passage of time. According to clinical results in the long term, interdisciplinary work has brought a significant reduction in the sequelae of the LPH because orthopedics diminishes the aesthetic and functional complications that these patients suffer from.

* Graduated from the Orthodontics Specialty.

§ Coordinator and professor of the Orthodontics Specialty.

Medical Specialties Center of Veracruz «Dr. Rafael Lucio» CEME V

This article can be read in its full version in the following page:
<http://www.medigraphic.com/ortodoncia>

METHODS

Case 1

Diagnosis

Male patient diagnosed with unilateral cleft lip and palate, who was brought in for consultation to the Clinic of Craniofacial Anomalies of the Center of Medical Specialties of the State of Veracruz «Dr. Rafael Lucio» (CEMEV). Upon clinical examination a 15 mm complete alveolar-palatal-lip cleft, depression of the wing of the nose on the left side, a short and asymmetrical columnella and cleft palate with exposure of the vomer bone was observed (*Figures 1-3*).

Treatment goals

To shape the alveolar process and nostril, to move the concha major is towards the concha minor, to decrease the size of the alveolo-palatal fissure, to decrease complications during cheiloplasty and to improve the perioral musculature tone.

Treatment plan

The patient's parents signed an informed consent where the diagnosis, treatment plan and possible complications were specified. The treatment plan consisted in obtaining an impression with condensation silicone in order to manufacture a Friedman obturator that would be used until the fissure decreased to less than 5 mm. Then, treatment would continue in 2 months with the use of a nasal shaper joined to this

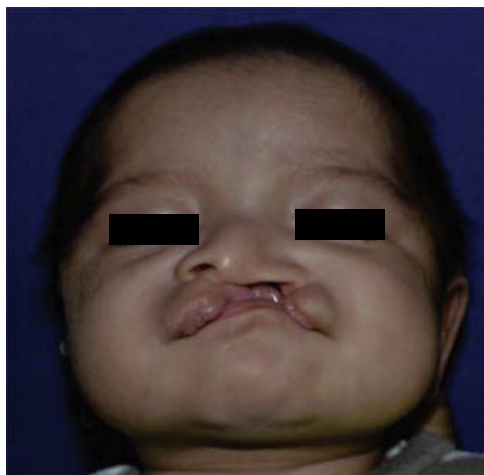

Figure 1. Initial extraoral photography.

plate. Appointments were scheduled every week to perform activations and changes according to the needs of the patient (*Figures 4-7*).

Case 2

Diagnosis

Male patient, two months of age, who was admitted in the orthodontics service for assessment and treatment with pre-surgical orthopedics. Upon clinical examination a bilateral, complete cleft lip and palate was observed along with premaxillary protrusion, a short columnella, asymmetric and depressed nostrils (*Figures 8 y 9*).

Treatment goals

To retract and align the premaxilla and shape adequately the alveolar process in addition to form the depressed nasal wings and stimulate closure of the

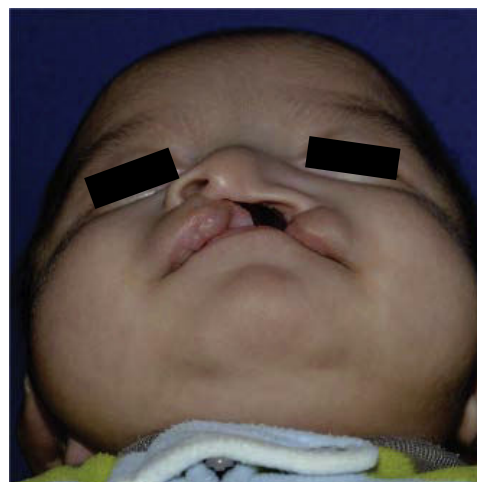

Figure 2. Initial submentovertex view.

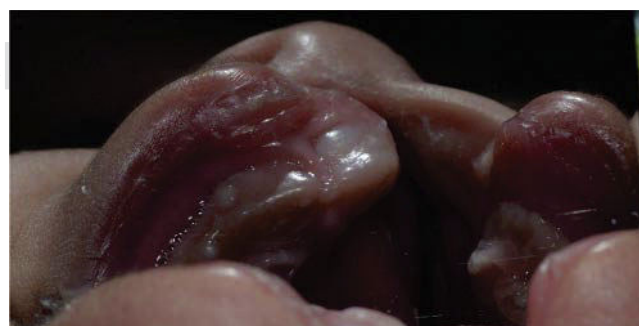

Figure 3. Initial intraoral photography.

palatal processes as well as to obtain better surgical outcomes.

Treatment plan

The patient's mother signed an informed consent where the diagnosis, treatment plan and possible complications were specified. Treatment plan consisted in obtaining an impression with condensation silicone to make a Friedman obturator that would align and retrude the premaxilla using as auxiliary extraorally attached tapes placed at 45° so that they would exert a force direction and intensity suitable for that purpose.

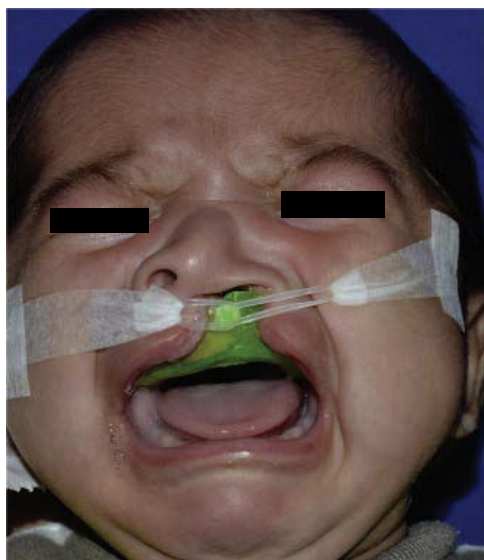

Figure 4. Intermediate photography.

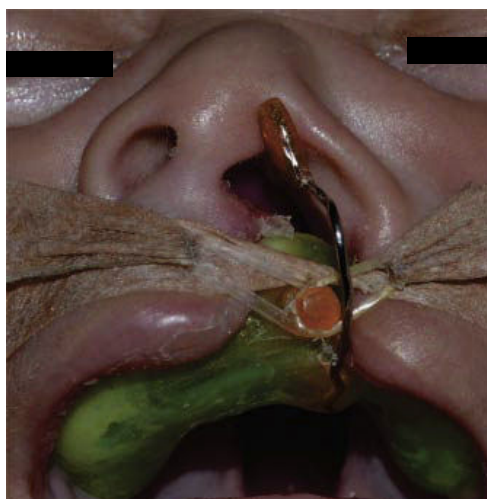


Figure 5. Intermediate photography with nasal shaper.

Once this goal was achieved, conformation of the nasal wings was continued (*Figures 10 and 11*).

RESULTS

Duration of treatment with pre-surgical orthopedics in the first case was eight weeks (*Figures 12-14*) and in the second case, 16 weeks (*Figures 15 and 16*). Adequate formation of the alveolar process, elongation and improved symmetry in the columella, stimulus for cleft palate closure was achieved as well as a better tone of the perioral muscles thus favoring a good surgical tissue management and achieving lip closure without tension with good functional and aesthetic results.

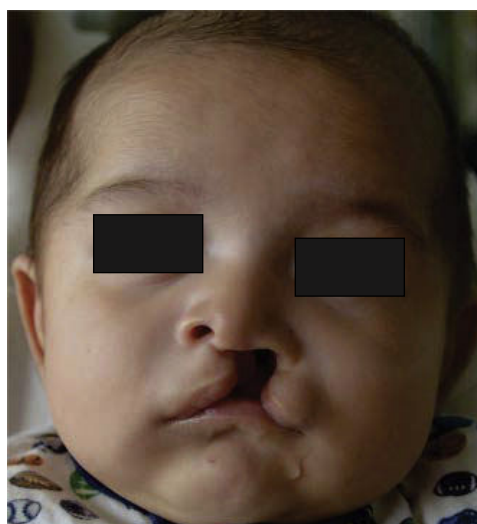

Figure 6. Patient before cheiloplasty.

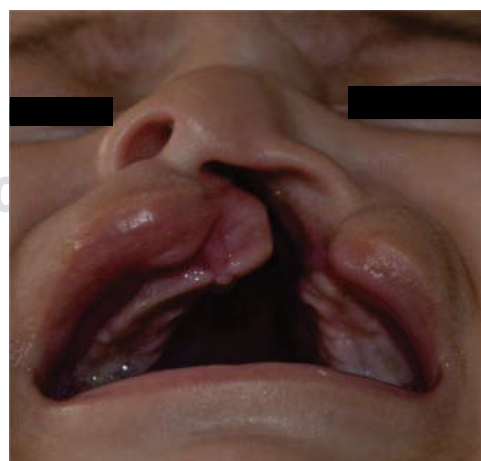

Figure 7. Intraoral photography.

DISCUSSION

The concept of early pre-surgical orthopedics for children who suffer from CLP was initially developed by Mc Niel³ and Burston⁴ in the 50's decade in England, although it was not consolidated as a technique until several years later. In 1984 Matsuo et al⁵⁻⁷ used cartilage molding techniques in the neonatal period to effectively correct congenital deformities of the cleft lip and nostrils. Later, in 1990 Nakajima et al,⁸ described a device fitted to the contour of the nasal wing to maintain what had been achieved with the surgical correction of the lip and nose. But in 1999 Yeow et al,⁹ added that it should be used for at least 6 months after the correction of the lip.

It was not until 1999 that Grayson^{10,11} described the nasoalveolar molding technique which was very

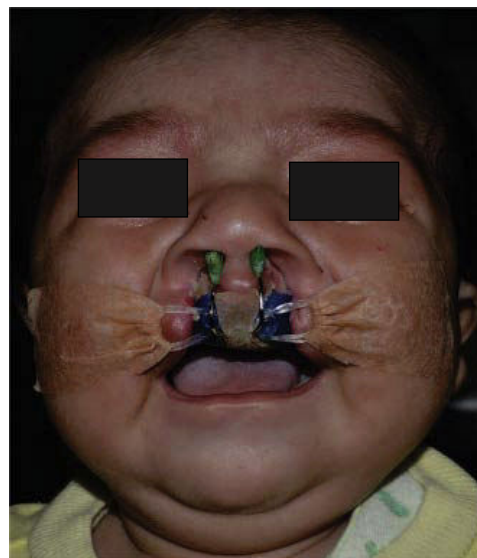

Figure 10. Intermediate photography.

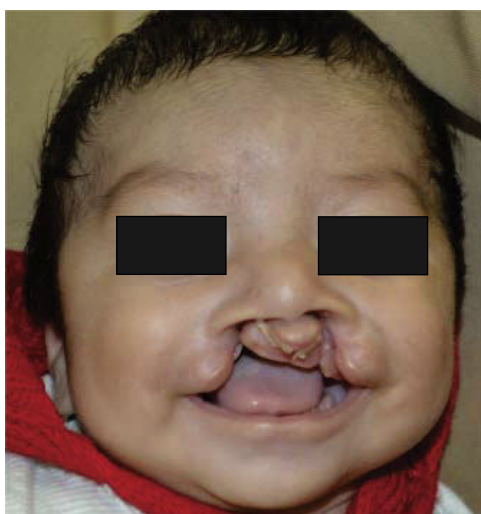

Figure 8. Initial extraoral photography.



Figure 11. Nasal shaper.

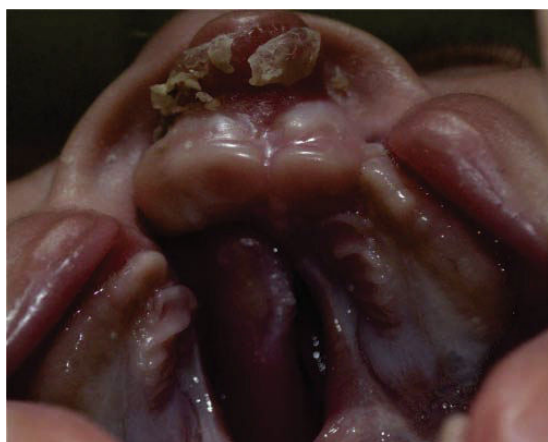

Figure 9. Initial intraoral photography.

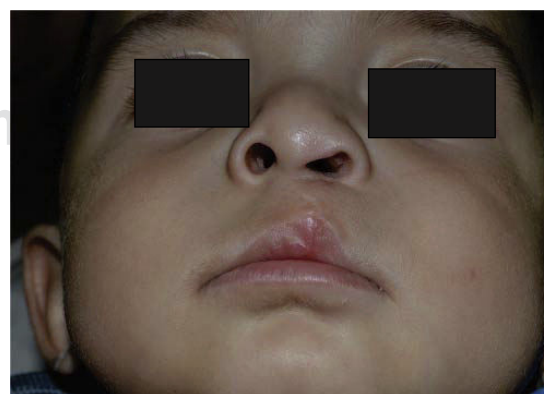

Figure 12. Nasal domes view.

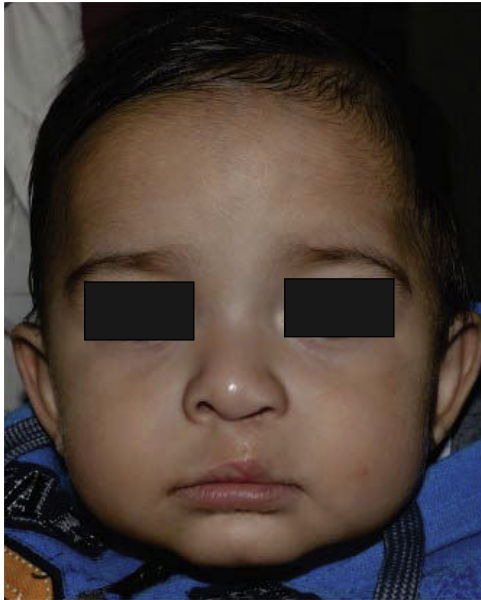

Figure 13. Final photograph.

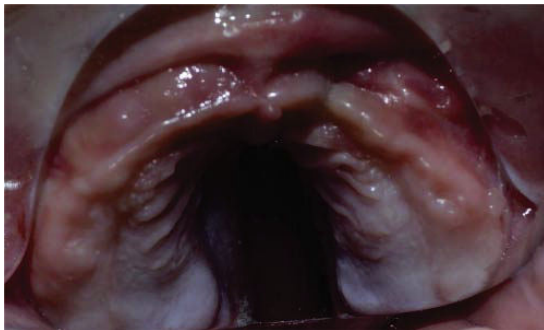

Figure 14. Final intraoral photograph.

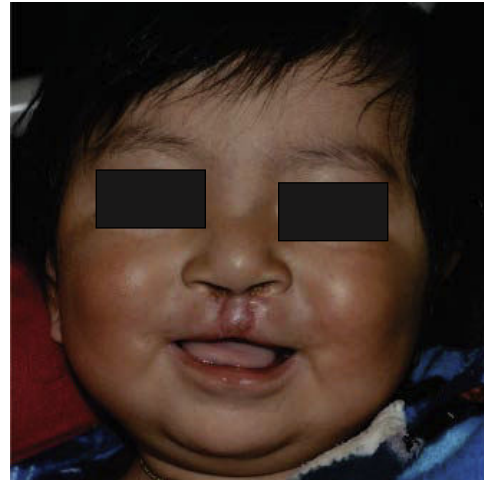

Figure 15. Final photograph.

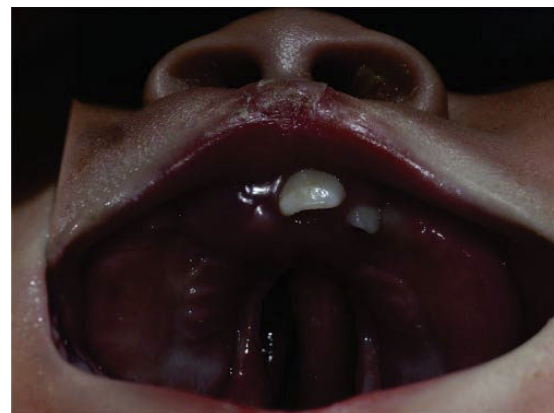

Figure 16. Final intraoral photograph.

well accepted since it offered a new alternative for patients in the neonatal period, prior to the execution of the first surgery of the lip and nose. In the literature, several successful results are reported since it shapes adequately the wing of the nose and provides a more aesthetic and functional way of shaping and changing the position of the immature and malleable nasal cartilage thus lengthening the columella.^{12,13}

Nasal molders are accessories that were created with a biological basis supported on the theory of Roux¹⁴ which supports that there is an intimate relationship between shape, structure and function. Afterwards, Dr. Moss in the 60's promoted his theory under the concepts of a periostic and capsular functional matrix.¹⁵ That is the reason why before cheiloplasty, nasal molders modify the depression of the wing of the nose caused by the fissure therefore

improving the projection of the tip of the nose and slightly lengthening the columella if used in early stages. Nasal molders are also used in after the primary rhinoplasty helping to prevent relapse of the conformed nasal wing, maintaining an open airway and limiting surgical adhesion that result from nasal secretions and scarring.¹⁶

Early orthopedics must be handled in three dimensions; vertical, sagittal and transverse. The nasal molder must be inserted into the obturator which stimulates the palatal processes and approaches them by presence of acrylic along with muscular forces. As a result, the nose is shaped and the deformation of the nasal wall is reduced as it stimulates and repositions soft tissues and nasal cartilage.¹⁷

Once the patient has been selected for the use of this technique, a protocol for the PNAM (presurgical

nasoalveolar moulding) fabrication is followed. A silicone impression is obtained and pre-surgical treatment is begun preferably in the first ten days after birth and the design and inserting the PNAM is performed for molding the alar cartilage with a maximum duration of six months.^{10,18}

These devices have other advantages: they approach the palatal processes improving archshape, the tongue is better positioned, there is a balance of the intraoral pressure and also facilitates the modification of the nasal tissues to improve the results in the first surgical procedure. Also, when used after the secondary rhinoplasty, they maintain the shape and position achieved, diminish the nasal stenosis of the nostrils, prevent the collapse of the nose, favors airway permeability and reduces surgical adhesions due to nasal secretions. But in order to achieve all this the parents cooperation is required as well as a correct manufacture and fitting of the appliance.¹⁸

CONCLUSIONS

Presurgical orthopedics is an effective treatment in patients with CLP and when performed early favorable results may be achieved thus improving the quality of life of these patients.

REFERENCES

1. Morales HC. Prevalencia de hendiduras labiopalatinas. *Acta Odontol Venez.* 1992; 30 (1/2): 35-40.
2. Trigos MI, Guzmán M. Análisis de la incidencia, prevalencia y atención del labio y paladar hendido en México. *Cir Plast.* 2003; 13: 35-39.
3. McNeil CK. Orthodontic procedures in the treatment of congenital cleft palate. *Dent Rec (London).* 1950; 70 (5): 126-132.
4. Burston WR. The early treatment of cleft palate conditions. *Dent Pract.* 1958; 9: 41-56.
5. Matsuo K, Hirose T, Tomono T. Non surgical correction of congenital auricular deformities in the early neonate: a preliminary report. *Plast Reconstr Surg.* 1984; 73 (1): 38-51.
6. Matsuo K, Hirose T, Otagiri T, Norose N. Repair of cleft lip with nonsurgical correction of nasal deformity in the early neonatal period. *Plast Reconstr Surg.* 1989; 83 (1): 25-31.
7. Matsuo K, Hirose T. Preoperative non-surgical over-correction of cleft lip nasal deformity. *Br J Plast Surg.* 1991; 44 (1): 5-11.
8. Nakajima T, Yoshimura Y, Sakakibara A. Argumentation of the nostril splint for retaining the corrected contour of the cleft lip nose. *Plast Reconstr Surg.* 1990; 85: 182-186.
9. Yeow VK, Chen PK, Chen YR, Noordhoff SM. The use of nasal splints in the primary management of unilateral cleft nasal deformity. *Plast Reconstr Surg.* 1999; 103 (5): 1347-1354.
10. Grayson B, Santiago P, Brecht L, Cutting C. Presurgical nasoalveolar molding in patients with cleft lip and palate. *Cleft Palate Craniofac J.* 1999; 36: 486-498.
11. Maull DJ, Grayson BH, Cutting CB, Brecht LL, Bookstein FL, Khorrambadi D et al. Long-term effects of nasoalveolar molding on three-dimensional nasal shape in unilateral clefts. *Cleft Palate Craniofac J.* 1999; 36 (5): 391-397.
12. Ömer S, Sament V. A novel nostril retainer designed by a patient. *Aesth Plast Surg.* 2009; 33: 789-790.
13. Mishra B, Sing AK, Zaidi J, Singh G, Agrawal R, Kumar V. Presurgical nasoalveolar molding for correction of cleft lip nasal deformity: experience from northern India. *Eplasty.* 2010; 10: pii: e55.
14. Frankel R. Revista electrónica consultada el día 30 enero de 2013. Disponible en: <http://www.amom.com.mx/amominfo1.htm>
15. Moss MM. The primary role of functional matrices in facial growth. *Am J Orthod.* 1969; 55: 566-577.
16. Pai BCB, Ko EW, Huang CS, Liou EJ. Symetry of the nose after presurgical nasoalveolar molding in infants with unilateral cleft lip and palate: a preliminary study. *Cleft Palate Craniofac J.* 2005; 42 (6): 658-663.
17. Muñoz A, Castro L. Ortopedia tridimensional y manejo preoperatorio de tejidos blandos en labio paladar hendidos. *Cir Plast.* 2008; 1: 6-12.
18. Proffit W. Ortodoncia contemporánea. 4 edición. España: Elsevier/Mosby; 2008. pp. 321-327.

Mailing address:

Nataly Lopera Restrepo

E-mail: elniloazul@hotmail.com