



ENDOSCOPIC SNAPSHOT

Small Bowel Obstruction Seven Years After Video Capsule Retention



Oclusão Intestinal Após Sete Anos de Retenção de Cápsula Endoscópica

Cátia Leitão*, Ana Caldeira, António Banhudo

Gastroenterology Department, Hospital Amato Lusitano, Unidade Local de Saúde de Castelo Branco, Castelo Branco, Portugal

Received 11 February 2016; accepted 3 April 2016

Available online 22 June 2016

KEYWORDS

Capsule Endoscopes/adverse effects;
Foreign Bodies;
Intestinal Obstruction;
Small Intestine

PALAVRAS-CHAVE

Cápsula Endoscópica/efeitos adversos;
Corpos Estranhos;
Obstrução Intestinal;
Intestino Delgado

Capsule retention is one of the known complications of capsule endoscopy.¹ The risk of retention is high in patients with prolonged nonsteroidal anti-inflammatory drug use, extensive Crohn's Disease and previous major abdominal surgery.² Most cases of capsule retention are asymptomatic and should be managed conservatively whenever possible. Some can be naturally excreted and other are amenable to medical therapy or endoscopic removal. Surgery is

considered if the patient develops acute small bowel obstruction symptoms or the origin is a malignant lesion.³

A 69-year-old man, hypertensive, was referred to the Gastroenterology Department to perform an upper endoscopy on November of 2012 because of diffuse abdominal pain and dark colored emesis. Blood workup was unremarkable, except for leukocytosis. The abdominal X-ray and computed tomography scan demonstrated small bowel distension and revealed a metallic foreign body of 20mm localized in the lumen (Fig. 1). Due to acute occlusive syndrome, patient was submitted to an exploratory laparotomy with resection of one segment of jejunum with 35 cm and 4 inflammatory stenotic regions, one of them occluded by a cylindrical, black colored foreign body – an endoscopic capsule (Fig. 2)! The histologic result of the surgical specimen confirmed a small bowel diverticula and inflammatory strictures related to diverticulitis. During the review of patient's medical history we confirmed that he did not mention any digestive symptoms and he had a capsule endoscopy 7 years (on July of 2005) before during the workup of microcytic hypochromic anemia. The report of the capsule endoscopy did not mention blood in the lumen or mucosal changes, stressing that the capsule did not reach the cecum during the recorded time. However, there were not any signs/symptoms or past medical history at presentation (pre-capsule endoscopy) associated with a higher risk of capsule retention that could have advised the use of small bowel imaging or patency capsule in this patient.

* Corresponding author.

E-mail address: catia.f.leitao@gmail.com (C. Leitão).

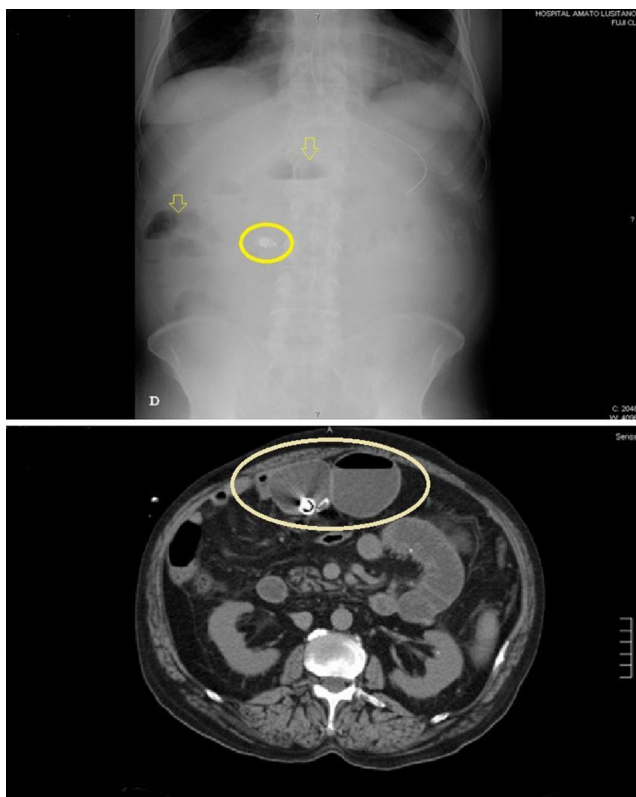


Figure 1 The abdominal X-ray and computed tomography showing air fluid levels, small bowel loops distention and a foreign body.

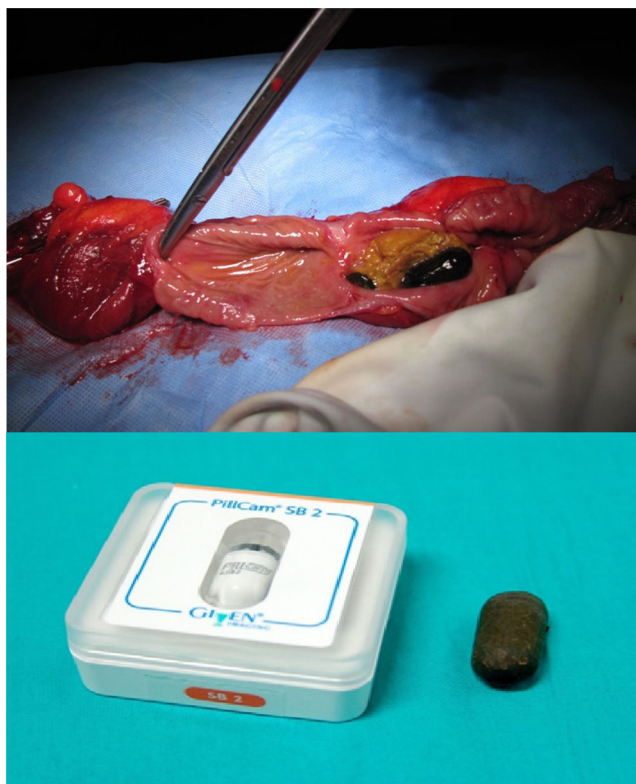

Figure 2 Segment of the resected small bowel containing the retained capsule.

The authors also reviewed the capsule study confirming that no stenosis was identified. Interestingly, the patient did not remember any abdominal symptoms during the 7 years of capsule retention.

As far as we are aware this is the longest reported case of capsule retention,⁴ an unusual case of retained endoscopic capsule in a patient without any suspicion of stenosis of the intestine and which remained asymptomatic over 7 years.

Ethical disclosures

Protection of human and animal subjects. The authors declare that no experiments were performed on humans or animals for this study.

Confidentiality of data. The authors declare that no patient data appear in this article.

Right to privacy and informed consent. The authors declare that no patient data appear in this article.

Conflicts of interest

The authors have no conflicts of interest to declare.

References

1. Liao Z, Gao R, Xu C, Li ZS. Indications and detection, completion, and retention rates of small bowel capsule endoscopy: a systematic review. *Gastrointest Endosc.* 2010;71: 286-280.
2. Li F, Gurudu SR, De Petris G, Sharma VK, Shiff AD, Heigh RI, et al. Retention of the capsule endoscope: a single-center experience of 1000 capsule endoscopy procedures. *Gastrointest Endosc.* 2008;68:174-80.
3. Fernández-Urien I, Carretero C, González B, Pons V, Caunedo A, Valle J, et al. Incidence, clinical outcomes, and therapeutic approaches of capsule endoscopy-related adverse events in a large study population. *Rev Esp Enferm Dig.* 2015;12:745-52.
4. Harrington C, Rodgers C. The longest duration of retention of a video capsule. *BMJ Case Rep.* 2014;8:2014.