



ENDOSCOPIC SNAPSHOT

Anal Pain and Constipation – Beyond the Obvious



Proctalgia e Obstipação – Para Além do Óbvio

Sandra Barbeiro*, Catarina Atalaia Martins, Pedro Marcos, Cláudia Gonçalves, Bruno Arroja, Manuela Canhoto, Liliana Eliseu, Filipe Silva, Isabel Cotrim, Helena Vasconcelos

Gastroenterology Department, Centro Hospitalar de Leiria, Leiria, Portugal

Received 28 February 2015; accepted 30 March 2015

Available online 27 June 2015

KEYWORDS

Anal Canal;
Constipation;
Foreign Bodies;
Pain

PALAVRAS-CHAVE

Canal Anal;
Corpos Estranhos;
Dor;
Obstipação

1. Case report

An 85-year-old male developed constipation after orthopaedic surgery and was treated with oral laxatives and enemas. After starting the medication he complained of anal pain and rectal bleeding. The primary care physician diagnosed an anal fissure and prescribed anal ointments.

* Corresponding author.

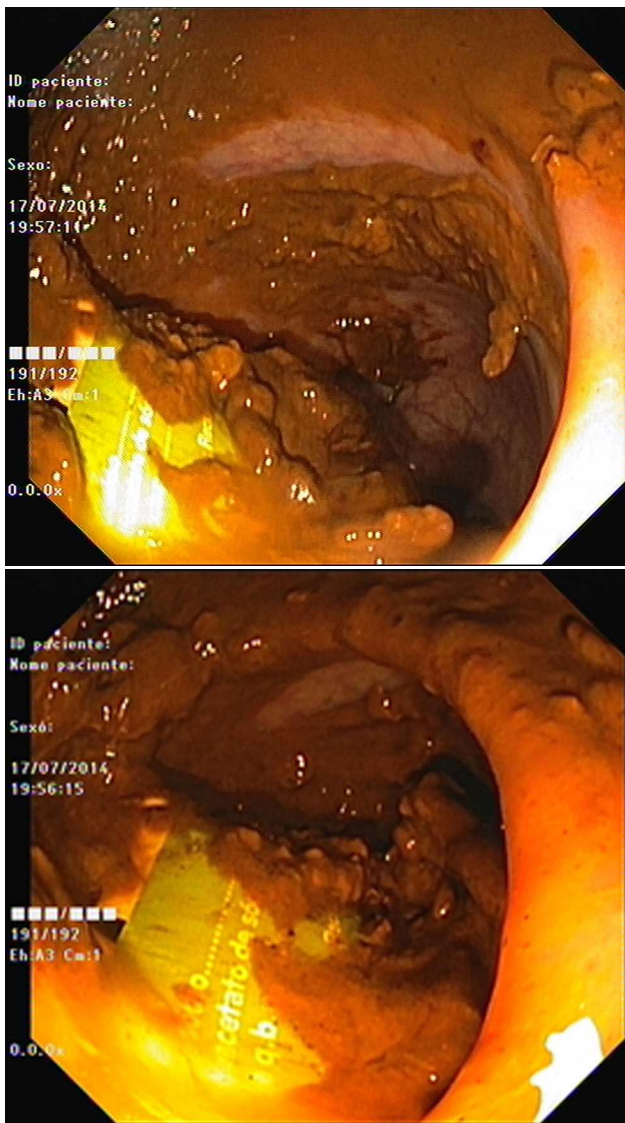
E-mail address: sandrabarbeiro@gmail.com (S. Barbeiro).

As pain became more severe he came to our hospital for observation. When asked, the patient admitted a single use of rectal microenema one month before and digital rectal examination revealed a foreign body within the rectal ampulla. Endoscopic examination of the rectum identified a microenema device (Figs. 1 and 2), which was removed with an anoscopy and a foreign body forceps with addition of a Valsalva manouever by the patient (Fig. 3). No sedation was needed because of the distal localization of the object and good tolerability to the procedure. No complications were registered and the patient was rapidly symptoms free.

2. Discussion

Most rectal foreign bodies are introduced consciously by persons seeking sexual stimulation.^{1,2} In our case the patient incorrectly applied the microenema and did not give that information to the physicians as he believed he had used it properly. We point out the fact that the foreign body remained in the rectum for a month before it was brought to attention to health care providers.

Most objects can be removed transanally.³ In clinically stable patients without evidence of perforation or peritonitis, the rectal foreign body can be removed in the emergency department.^{3,4} The management depends on the texture, size, shape and location of the object.⁴ If the foreign body can be easily palpated, it is possible to be extracted transanally using one of many clamps and instruments, with or without direct visualization through a rigid



Figures 1 and 2 Endoscopic view of the microenema device in the rectum.

or flexible endoscope.³⁻⁵ Open surgery should be reserved only for patients with perforation, peritonitis or impaction of the foreign body.^{4,5}

Conflicts of interest

The authors have no conflicts of interest to declare.



Figure 3 Extracted microenema device.

Ethical disclosures

Protection of human and animal subjects. The authors declare that no experiments were performed on humans or animals for this study.

Confidentiality of data. The authors declare that no patient data appear in this article.

Right to privacy and informed consent. The authors declare that no patient data appear in this article.

References

1. Yildiz SY, Kendirci M, Akbulut S, Ciftci A, Turgut HT, Hengirmen S. Colorectal emergencies associated with penetrating or retained foreign bodies. *World J Emerg Surg.* 2013;8:25.
2. Desai B. Visual diagnosis: Rectal foreign body: a primer for emergency physicians. *Int J Emerg Med.* 2011;4:73.
3. Goldberg JE, Steele SR. Rectal foreign bodies. *Surg Clin N Am.* 2010;90:173–84.
4. Coskun A, Erkan N, Yakan S, Yildirim M, Cengiz F. Management of rectal foreign bodies. *World J Emerg Surg.* 2013;8:11.
5. Cologne KG, Ault GT. Rectal foreign bodies: what is the current standard. *Clin Colon Rectal Surg.* 2012;25:214–8.