

supported by the fact that the patient observed home isolation for 21 days before neurological symptom onset, as well as the negative results for antitanglioside antibodies. However, the postinfectious onset, acute clinical course, and typical neurophysiological findings of GBS (mixed-type polyneuropathy of motor and sensory fibres), together with the absence of history of autoimmune, neoplastic, or neurological disease, suggest postinfectious aetiology. A significant limitation is the lack of availability of SARS-CoV-2 serology tests and CSF PCR tests at our centre.

While our case is suggestive of a possible association between GBS and SARS-CoV-2 infection, further case reports with epidemiological data are needed to demonstrate a causal relationship. This case also underscores the need to consider possible neurological symptoms of SARS-CoV-2 infection.

The authors agree that there is a need for careful observation of neurological complications of SARS-CoV-2 infection.

The Spanish Society of Neurology is currently conducting a national observational study on neurological presentations and manifestations of COVID-19.

## References

1. Velayos-Galán A, Saucedo PDS, Postigo FP, Botia-Paniagua E. Síndrome de Guillain-Barré asociado a infección por SARS-CoV-2. *Neurología*. 2020, pii: S0213-4853(20)30072-30074.
2. Alberti P, Beretta S, Patti M, Karantzoulis M, Pratti ML, Santoro P, et al. Guillain-Barré syndrome related to COVID-19 infection. *Neural Neuroimmunol Neuroinflamm*. 2020;7:e741, <http://dx.doi.org/10.1212/NXI.0000000000000741>.
3. Zhao H, Shen D, Zhou H, Liu J, Chen S. Guillain-Barré syndrome associated with SARS-CoV-2 infection: causality or coincidence? *Lancet Neurol*. 2020.
4. Padroni M, Mastrangelo V, Asioli GM, Pavolucci L, Abu-Rummeleh S, Grazia Piscaglia M, et al. Guillain-Barré syndrome following COVID-19: new infection, old complication? *J Neurol*. 2020;1–3, <http://dx.doi.org/10.1007/s00415-020-09849-6>.
5. Scheidl E, Diez Canseco D, Hadji-Naumov A, Bereznai B. Guillain-Barre syndrome during SARS-CoV-2 pandemic: a case report and review of recent literature. *Case reports: J Peripher Nerv Syst*. 2020, <http://dx.doi.org/10.1111/jns.12382>.
6. Utmami H, Moutawakil B, Rafai M, Benna N, Kettani C, Soussi M, et al. Covid-19 and Guillain-Barré syndrome: more than a coincidence? *Rev Neurol (Paris)*. 2020, <http://dx.doi.org/10.1016/j.neurol.2020.04.007>.
7. Coen M, Grégoire Jeanson G, Culebras Almeida A, Hübers A, Florian Sterlin F, Najjar J, et al. Guillain-Barré syndrome as a complication of SARS-CoV-2 infection. *Brain Behav Immun*. 2020, <http://dx.doi.org/10.1016/j.bbi.2020.04.074>.
8. Marta-Enguita J, Rubio-Baies J, Gastón-Zubimendi I. Fatal Guillain-Barre syndrome after infection with SARS-CoV-2. *Neurología*. 2020, <http://dx.doi.org/10.1016/j.neu.2020.04.004>.
9. Virani A, Rabold E, Hanson T, Haag A, Etrufay R, Cheema T, Balaan M, Bhanot N. Guillain-Barré syndrome associated with SARS-CoV-2 infection. *IDCases*. 2020;20:e00771, <http://dx.doi.org/10.1016/j.idcr.2020.e00771>.
10. Camdessanche JP, Morel J, Pozzetto B, Paul S, Tholance Y, Botelho-Nevers E, et al. COVID-19 may induce Guillain-Barré syndrome. *Rev Neurol (Paris)*. 2020, <http://dx.doi.org/10.1016/j.neurol.2020.04.003>.
11. Sedaghat Z, Karimi N. Guillain Barre syndrome associated with COVID-19 infection: a case report. *J Clin Neurosci*. 2020, <http://dx.doi.org/10.1016/j.jocn.2020.04.062>.
12. Toscano G, Palmerini F, Ravaglia S, Ruiz L, Invernizzi P, Giovanna Cuzzoni M, et al. Guillain-Barré syndrome associated with SARS-CoV-2. *N Engl J Med*. 2020. <https://doi.org/10.1056/NEJMC2009191>.
13. C. Gujjarro-Castro <sup>a,b,c,\*</sup>, M. Rosón-González <sup>a</sup>, A. Abreu <sup>a</sup>, A. García-Arratibel <sup>a,d</sup>, M. Ochoa-Mulas <sup>a,d</sup>  
<sup>a</sup> *Servicio de Neurología, CINAC Puerta del Sur, Mostoles, Madrid, Spain*  
<sup>b</sup> *Coordinadora del Grupo de Estudio de Humanidades e Historia de la Neurología de la SEN, Spain*  
<sup>c</sup> *Facultad de Medicina, UEM, Madrid, Spain*  
<sup>d</sup> *Facultad de Medicina, CEU, Madrid, Spain*

\*Corresponding author.

E-mail address: [crisxqguig@gmail.com](mailto:crisxqguig@gmail.com) (C. Gujjarro-Castro).

<https://doi.org/10.1016/j.nrleng.2020.06.002>

2173-5808/

© 2020 Sociedad Española de Neurología. Published by Elsevier España, S.L.U. This is an open access article under the CC BY-NC-ND license (<http://creativecommons.org/licenses/by-nc-nd/4.0/>).

## Emergency implementation of a teleneurology service at the neuromuscular diseases unit of Hospital Regional de Málaga during the SARS-CoV-2 pandemic<sup>☆</sup>



### Implantación emergente de un servicio de Teleneurología en la Unidad de Neuromuscular del Hospital Regional de Málaga durante la pandemia por SARS-CoV-2

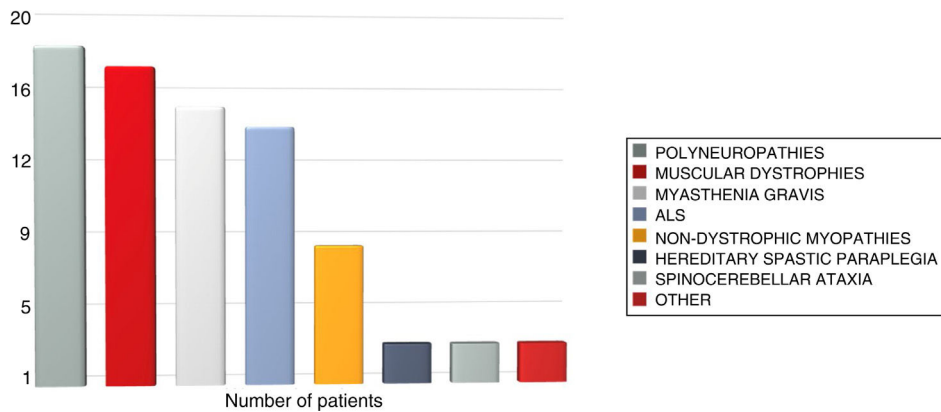
*Dear Editor:*

Teleneurology was initially developed to provide care for complex, acute disorders in patients living in remote places,

as was the case with telestroke.<sup>1</sup> However, in recent years its use has been expanded to treat other neurological diseases, and teleneurology has been gradually incorporated into routine outpatient follow-up.<sup>2</sup> Benefits include a reduction in time and travel costs for patients, improved access from remote areas, and perceived satisfaction among professionals and patients and their family members. Its limitations include the loss of traditional in-person relationships, the inability to perform a complete neurological examination, and neurologists' concerns about a possible loss of diagnostic accuracy.<sup>3</sup> We may distinguish 3 means of communication between neurologists and patients in teleneurology: telephone, audiovisual systems, and written consultation.<sup>4</sup> We propose the abbreviations t-consultation for telephone consultations, v-consultation for video consultations, and e-consultation<sup>5</sup> for written consultations.

Since the publication in Spain of Royal Decree 463/2020,<sup>6</sup> declaring the state of alarm that transferred management of the healthcare crisis caused by the SARS-CoV-2 coronavirus

<sup>☆</sup> Please cite this article as: Romero-Imbroda J, Reyes-Garrido V, Ciano-Petersen NL, Serrano-Castro PJ. Implantación emergente de un servicio de Teleneurología en la Unidad de Neuromuscular del Hospital Regional de Málaga durante la pandemia por SARS-CoV-2. *Neurología*. 2020;35:415–417.



**Figure 1** Patient distribution by clinical diagnosis. ALS: amyotrophic lateral sclerosis.

(COVID-19 disease) to the central government,<sup>7</sup> reorganising habitual clinical care in different areas of knowledge<sup>8</sup> has been essential in promoting the development of strategies to avoid contact between neurologists and patients.<sup>9</sup> While no information is currently available on the virulence of this disease in patients with neuromuscular diseases, they should generally be considered a high-risk population.<sup>10</sup>

We report the experience with teleneurology at our neuromuscular diseases unit through an observational, prospective study conducted from 14 March 2020 (beginning of the state of alarm) to 24 April 2020. We included 88 consecutive patients in the sample, and collected demographic and clinical variables (age, sex, diagnosis, and screening for COVID-19 symptoms); and variables related to communication: person interviewed (patient or carer), type of electronic consultation (t-consultation, v-consultation, or e-consultation), distance from hospital to the place of the interview as measured with the Google Maps application, and estimated fuel savings. The cost of travel was estimated considering current price of unleaded 95 petrol (€1.30/L) and assumed the average fuel consumption of a sedan vehicle with 2 occupants, 8L/100 km. These data were compared against data from the same period in 2019.

A total of 86 of the 88 patients or carers used electronic consultation (97.7%). All individuals initially agreed to use t-consultation and 8 patients (9.3%) were reassessed by v-consultation (4 patients with myasthenia gravis, 2 with muscular dystrophy, and 2 with other conditions) due to poor symptom control or unexpected symptom progression. Two patients reassessed by v-consultation (2.3% of the total) used e-consultation to report events during subsequent progression. None required emergency hospital care after electronic consultation. Mean age of the patients was 52.6 years; men accounted for 56.9% of the sample. In 13.9% of cases, patients needed the help of their carer to contact their neurologist. The total travel distance saved was 5591.7 km (63.68 km per patient). The estimated total fuel saving amounted to €684.4, with a mean expenditure per consultation of €7.6.

**Fig. 1** shows the distribution of neuromuscular diseases attended.

None of the patients presented symptoms compatible with COVID-19. The percentage of patients attended at the unit in the same period in 2019 was 88.7% (79 of the 89 scheduled consultations), 9% less than in 2020.

The emergency move from in-person consultations at our neuromuscular diseases unit to a teleneurology system during the COVID-19 pandemic improved access and decreased the ratio of non-attendance with regard to the previous year. The participation of carers was required for effective communication with some patients. This type of care avoided the need for travel for patients whose main symptom is muscle weakness, which impairs mobility, and led to fuel savings. Implementation of teleneurology at our unit has enabled continuity of care. The lockdown of patients included in this study appears to have been a safe and effective method of preventing new cases of COVID-19.

Once the COVID-19 pandemic is over, teleneurology strategies should be developed to coexist with in-person neurological care for patients with neuromuscular diseases under routine outpatient follow-up. We believe that abbreviations t-consultation, v-consultation, and e-consultation simplify discussion of the type of communication used with each patient.

### Author contributions

All authors have participated in patient assessment, statistical analysis, and drafting of the article.

### References

1. Rubin MR, Wellik KE, Channer DD, Demaerschalk M. Role of telemedicine in providing tertiary neurological care. *Curr Treat Options Neurol.* 2013;15:567–82. <http://dx.doi.org/10.1007/s11940-013-0247-4>.

2. Agarwal S, Warburton EA. Teleneurology: is it really at a distance? *J Neurol*. 2011;258:971–81, <http://dx.doi.org/10.1007/s00415-011-5920-5>.
3. Rubin MN, Wellik KE, Channer DD, Demaerschalk M. Systematic review of teleneurology: methodology. *Front Neurol*. 2012;3:156, <http://dx.doi.org/10.3389/fneur.2012.00156>.
4. Wechsler LR, Tsao JW, Levine SR, Swain-Eng RJ, Adams RJ, Demaerschalk M, et al. Teleneurology applications. Report of the Telemedicine Work Group of the American Academy of Neurology. *Neurology*. 2013;80:670–6, <http://dx.doi.org/10.1212/WNL.0b013e3182823361>.
5. Romero-Imbroda J, Del Canto-Pérez C, Sagrario-Fustero T. Teleneurología y e-consulta aplicada a Neurología general. *Rev Neurol*. 2017;64:227–34.
6. Boletín Oficial del Estado (67): 25390-25400. 14 de marzo de 2020.
7. Guan WJ, Zhong NS, Hu Y, Liang WH, Ou CQ, He JX, et al. Clinical Characteristics of coronavirus disease 2019 in China. *N Engl J Med*. 2020;382:1708–3821720, <http://dx.doi.org/10.1056/NEJMoa2002032>.
8. Matias-Guiu J, Porta-Etessam J, López-Valdes E, García Morales I, Guerrero-Solá A, Matias-Guiu JA. La gestión de la asistencia neurológica en tiempos de la pandemia de Covid-19. *Neurología*. 2020, <http://dx.doi.org/10.1016/j.nrl.2020.04.001>.
9. Klein BC, Busis NA. COVID-19 is catalyzing the adoption of teleneurology. *Neurology*. 2020;1:10, <http://dx.doi.org/10.1212/WNL.0000000000009494>.
10. Documento elaborado por el Grupo de estudio de Enfermedades Neuromusculares. Sociedad Española de Neurología. Marzo 2020 [Accessed 19 March 2020]. Available from: <http://www.sen.es/attachments/article/2662/Consejos%20para%20pacientes%20con%20Enfermedades%20Neuromusculares.pdf>.

J. Romero-Imbroda<sup>a,b,\*</sup>, V. Reyes-Garrido<sup>a,b</sup>, N.L. Ciano-Petersen<sup>a</sup>, P.J. Serrano-Castro<sup>a,b</sup>

<sup>a</sup> Servicio de Neurología, Hospital Regional Universitario de Málaga, Málaga, Spain

<sup>b</sup> Instituto de Investigación Biomédica de Málaga (IBIMA), Málaga, Spain

\* Corresponding author.

E-mail address: [jesusromeroimbroda@gmail.com](mailto:jesusromeroimbroda@gmail.com) (J. Romero-Imbroda).

<https://doi.org/10.1016/j.nrleng.2020.05.014>  
2173-5808/

© 2020 Sociedad Española de Neurología. Published by Elsevier España, S.L.U. This is an open access article under the CC BY-NC-ND license (<http://creativecommons.org/licenses/by-nc-nd/4.0/>).

## Occipital condyle syndrome as the first manifestation of a rectal tumour<sup>☆</sup>



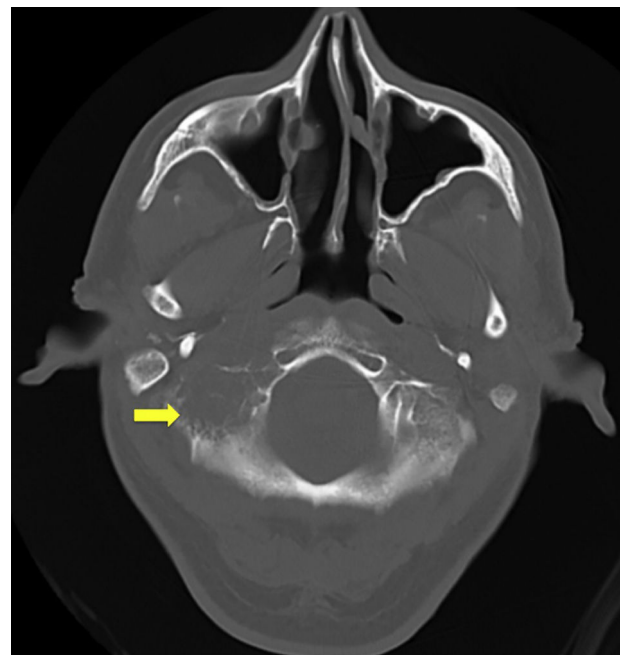
## Síndrome del cóndilo occipital como manifestación primera de una neoplasia de recto

Dear Editor:

Occipital condyle syndrome (OCS) is a rare condition first identified by Greenberg in 1981, in a series of patients with brain metastases.<sup>1</sup> The syndrome is characterised by paralysis of the ipsilateral hypoglossal nerve and persistent occipital pain that usually radiates to the mastoid process, is exacerbated by inclination of the head to the contralateral side, and is associated with increased sensitivity of the scalp.

It is often caused by tumour metastasis, usually originating from breast or prostate cancer.<sup>2</sup> In the most recent case series,<sup>2</sup> OCS was the first manifestation of the neoplasia in more than half of patients.

A literature search on PubMed (keywords: “occipital condyle syndrome” and “colorectal cancer”) identified no cases of the syndrome as the initial manifestation of a rectal



**Figure 1** Head CT bone window study without intravenous contrast; axial plane. A spiculated, destructive lytic lesion (arrow) is observed on the right occipital squama and condyle, projecting toward the skull base.

<sup>☆</sup> Please cite this article as: Martín Asenjo M, Martín Guerra JM, Galvan Fernández J, Martín-Luquero Ibañez M, Prieto de Paula JM. Síndrome del cóndilo occipital como manifestación primera de una neoplasia de recto. *Neurología*. 2020;35:417–419.