



ORIGINAL ARTICLE

Utility of ultrasound-guided injection of botulinum toxin type A for muscle imbalance in children with obstetric brachial plexus palsy: description of the procedure and action protocol[☆]



A. García Ron^{a,*}, R. Gallardo^b, B. Huete Hernani^c

^a Unidad de Neuropediatría, Instituto del Niño y del Adolescente, Hospital Clínico San Carlos, Madrid, Spain

^b Residente de Neuropediatría, H.U. Infanta Cristina, Parla, Madrid, Spain

^c Servicio de Pediatría, Unidad de Neuropediatría, H.U. Infanta Cristina, Parla, Madrid, Spain

Received 12 September 2016; accepted 20 December 2016

Available online 19 December 2018

KEYWORDS

Obstetric brachial plexus palsy;
Brachial plexus;
Neonatal neuropathy;
Botulinum toxin A;
Shoulder dystocia;
Ultrasound

Abstract

Introduction: Obstetric brachial plexus palsy (OBPP) usually has a favourable prognosis. However, nearly one third of all severe cases have permanent sequelae causing a high level of disability. In this study, we explore the effectiveness of ultrasound-guided injection of botulinum toxin A (BoNT-A) and describe the procedure.

Patients and methods: We designed a prospective, descriptive study including patients with moderate to severe OBPP who were treated between January 2010 and December 2014. We gathered demographic data, type of OBPP, and progression. Treatment effectiveness was assessed with the Active Movement Scale (AMS), the Mallet classification, and video recordings.

Results: We gathered a total of 14 133 newborns, 15 of whom had OBPP (1.6 per 1000 live births). Forty percent of the cases had severe OBPP (0.4/1000), a dystocic delivery, and APGAR scores < 5; mean weight was 4038 g. Mean age at treatment onset was 11.5 months. The muscles most frequently receiving BoNT-A injections were the pronator teres, subscapularis, teres major, latissimus dorsi, and pectoralis major. All the patients who completed the follow-up period (83%) experienced progressive improvements: up to 3 points on the AMS and a mean score of 19.5 points out of 25 on the Mallet classification at 2 years. Treatment improved muscle function and abnormal posture in all cases. Surgery was avoided in 3 patients and delayed in one. Adverse events were mild and self-limited.

[☆] Please cite this article as: García Ron A, Gallardo R, Huete Hernani B. Utilidad del tratamiento con infiltraciones ecoguiadas de toxina botulínica A en el desequilibrio muscular de niños con parálisis obstétrica del plexo braquial. Descripción del procedimiento y protocolo de actuación. Neurología. 2019;34:215–223.

* Corresponding author.

E-mail address: adrian.garcia@salud.madrid.org (A. García Ron).

PALABRAS CLAVE

Parálisis braquial
obstétrica;
Plexo braquial;
Neuropatía neonata;
Toxina botulínica;
Disocia de hombro;
Ecografía

Conclusions: Due to its safety and effectiveness, BoNT-A may be used off-label as an adjuvant to physical therapy and/or surgery in moderate to severe OBPP. Ultrasound may increase effectiveness and reduce adverse effects.

© 2018 Published by Elsevier España, S.L.U. on behalf of Sociedad Española de Neurología. This is an open access article under the CC BY-NC-ND license (<http://creativecommons.org/licenses/by-nc-nd/4.0/>).

Utilidad del tratamiento con infiltraciones ecoguiadas de toxina botulínica A en el desequilibrio muscular de niños con parálisis obstétrica del plexo braquial. Descripción del procedimiento y protocolo de actuación

Resumen

Introducción: La parálisis braquial obstétrica (PBO) suele tener un pronóstico favorable; sin embargo, casi un tercio de los casos graves presentan secuelas permanentes que generan gran discapacidad. Valoramos la eficacia del tratamiento con infiltraciones ecoguiadas de toxina botulínica A (TB-A) y describimos el procedimiento.

Pacientes y métodos: Estudio prospectivo, descriptivo, de los casos de PBO moderada-grave tratados entre enero del 2010 y diciembre del 2014. Recogimos datos demográficos, tipo de PBO y evolución. Valoramos eficacia con la escala de movimiento activo (EMA), Mallet Classification System y videofilmación.

Resultados: Valoramos a 14.133 recién nacidos vivos, con 15 casos de PBO (1,06 por cada 1.000). El 40% casos graves (0,4/1000), nacidos de parto distócico, con APGAR < 5 y peso medio de 4.038 g. Edad media de inicio de infiltraciones 11,5 meses. El pronator teres, subescapularis, teres mayor, latissimus dorsi y/o pectoralis major fueron los más frecuentemente infiltrados. Mejoría progresiva hasta 3 niveles en EMA y una media de 19,5 puntos sobre 25 en la escala de Mallet a los 2 años en todos los casos de PBO que completaron el seguimiento (83%). Todos mejoraron funcionalidad y posturas anormales. Evitamos la cirugía en 3 pacientes y se retrasó en uno. Los efectos adversos del tratamiento fueron leves y autolimitados.

Conclusiones: Por su seguridad y eficacia, parece razonable la utilización «off label» de TB-A como tratamiento adyuvante a las terapias físicas y/o tratamiento quirúrgico en las PBO moderadas-graves. La ecografía podría aumentar la eficacia y disminuir efectos adversos.

© 2018 Publicado por Elsevier España, S.L.U. en nombre de Sociedad Española de Neurología. Este es un artículo Open Access bajo la licencia CC BY-NC-ND (<http://creativecommons.org/licenses/by-nc-nd/4.0/>).

Introduction

Obstetric brachial plexus palsy (OBPP) is the most frequent neonatal peripheral neuropathy, with incidence ranging from 0.5 to 2 cases per 1000 live births in developed countries, depending on the series.¹⁻⁴

Prognosis depends on the severity and extension of the lesions to the nerve roots. Fortunately, most cases spontaneously achieve complete recovery, or at least a near-normal range of motion and strength, in the first 6 to 8 weeks of life.⁵ However, in severe cases, permanent motor sequelae cause considerable disability; these cases require early identification and treatment.

Permanent functional limitation occurs in approximately one-third of severe lesions and mainly affects the muscles involved in elbow flexion, forearm supination, wrist extension, and the external rotation and abduction of the shoulder.⁵⁻⁷ Weakness of these muscle groups leads to an imbalance in strength with respect to the healthy antagonist muscles, resulting in significant functional limitation of the affected limb. Given its natural history, persistent

muscle imbalance would limit the motion and strength of the affected limb, which frequently leads to the development of muscle contractures and occasionally bone deformities, mainly in the shoulder.⁸

It is therefore vitally important to identify the most severe cases early and to follow a systematic action protocol to limit permanent disability in children, whenever possible.

Botulinum toxin (BT) has been found to be effective and safe in the treatment of muscle imbalance, muscle co-contractions, and contractures; it may be used in these patients to weaken the healthy antagonist muscles with the aim of balancing strengths and enabling growth, strengthening, and functional improvement of the affected muscles through physical and occupational therapies, facilitating the development of a correct movement pattern during reinnervation, whenever possible.⁹⁻¹¹

The aim of this study is to describe our experience with the treatment of OBPP with ultrasound-guided infiltrations of BT type A (BoNT-A), and to describe the procedure and action protocol.

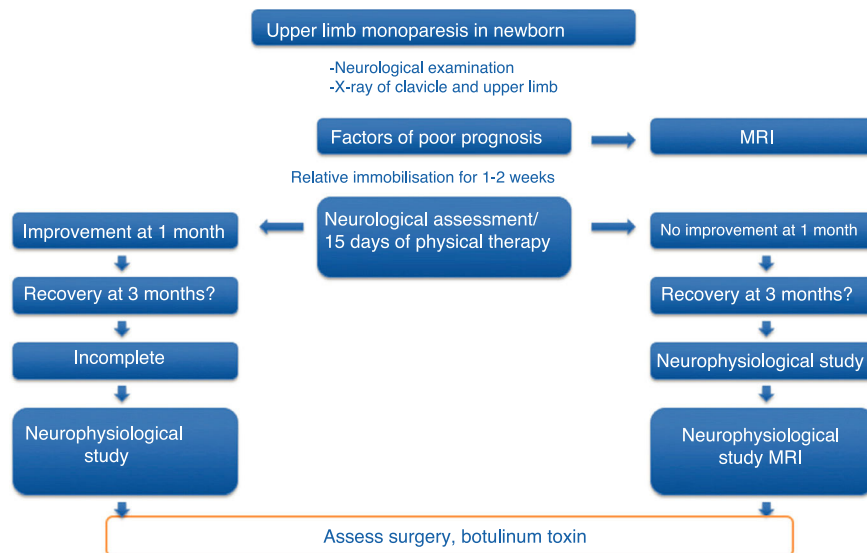


Figure 1 Action protocol for newborns with upper limb monoparesis.

Patients and methods

This is an open, non-randomised, prospective, descriptive study on the safety and effectiveness of treatment with ultrasound-guided infiltrations of BoNT-A, including all cases of moderate-to-severe OBPP diagnosed and treated at our centre between January 2010 and December 2014. Patients were included according to a previously established action protocol (Fig. 1), which is applied to all newborns with upper limb monoparesis. Once the diagnosis of OBPP was established, follow-up visits were scheduled to assess the clinical progression of newborns and include candidates for BoNT-A infiltrations; patients’ parents signed informed consent forms before treatment.

Inclusion criteria

- Moderate-to-severe OBPP showing slight improvement with physical rehabilitation
- Recovery of biceps contraction at 6 to 9 months of life
- Muscle imbalances involving shoulder, elbow, forearm, or wrist muscles, leading to anomalous movement patterns and/or positions
- Biceps-triceps co-contraction
- Joint contractures (elbow flexion) in the affected arm
- Commitment to continue physical and occupational therapy before and after BoNT-A infiltrations

We excluded patients with mild OBPP with complete resolution in the first months of life, who therefore needed no treatment with BoNT-A.

We gathered data on demographic variables (age, sex), obstetric history (gestational age at birth, type of delivery, birth weight), type of OBPP (affected side, affected nerve roots, and classification by severity and prognosis according to the schema proposed by Gilbert and Tassin/Narakas [Fig. 2]),^{12,13} and factors associated with poor prognosis (Horner syndrome, diaphragmatic paralysis, complete paral-

Group	Roots affected	% showing spontaneous, complete recovery
I	C5-C6	90
II	C5-C6-C7	65
III	C5-C6-C7-C8-T1	< 50
IV	C5-T1 + HORNER S.	0

Figure 2 Severity and progression classification proposed by Gilbert and Tassin/Narakas.

ysis, lack of improvement with conservative treatment at 3 months of progression, lack of antigravity strength in the deltoids and triceps at the end of the third month of life).

Procedure

All infiltrations were performed by the same physician, using ultrasound guidance, conscious analgesia/sedation with Kalinox[®] (50% protoxide of nitrogen and 50% medical oxygen; Air Liquide Healthcare, Spain), and topical analgesia with Emla[®] cream (lidocaine 25 mg/g + prilocaine 25 mg/g; AstraZeneca Farmacéutica Spain, SA) in collaborating patients; unconscious sedation with intravenous drugs (ketamine, midazolam, propofol, or fentanyl, depending on the patient) was also used in non-collaborating patients to minimise complications and adverse reactions and to improve efficacy.

1. Muscle selection: performed on a case-by-case basis according to the previous examination of the affected

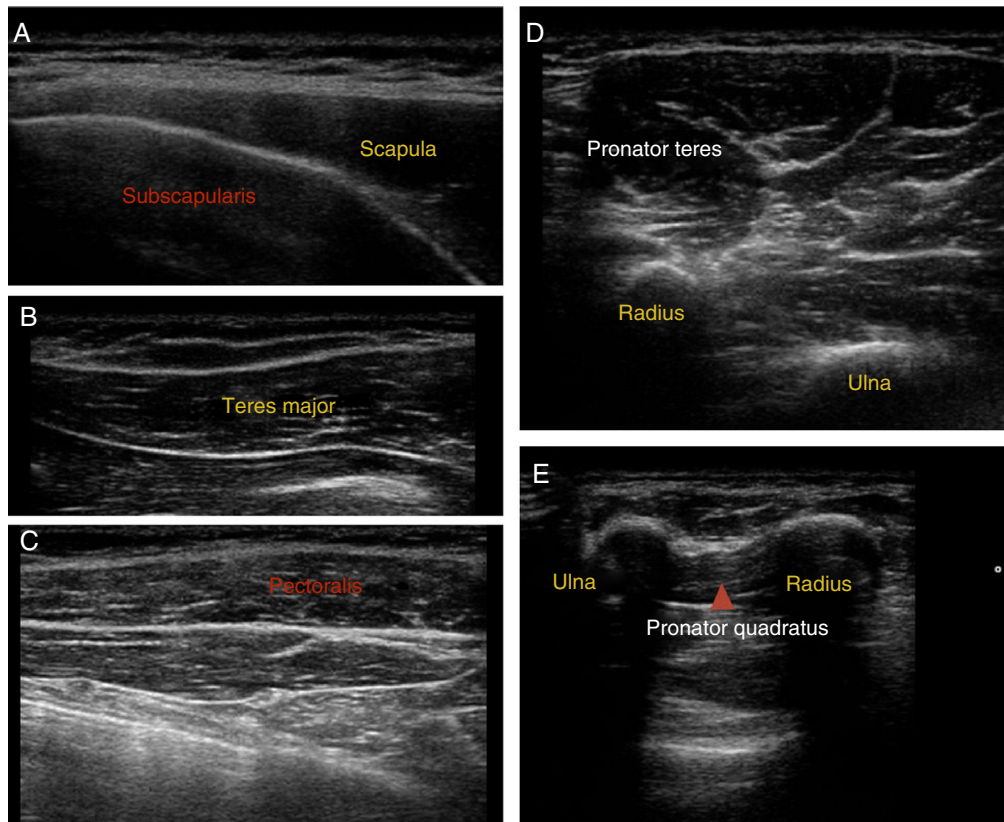


Figure 3 Ultrasound images of muscle localisation.

limb, function, and/or deformity or the most frequent anomalous motion patterns.

- a. Internal rotation of the shoulder: subscapularis muscles, teres major muscle, latissimus dorsi, and/or pectoralis major
 - b. Extension of the arm: triceps brachii
 - c. Pronation of the forearm: pronator teres and/or pronator quadratus
 - d. Wrist flexion: flexor carpi ulnaris or flexor carpi radialis muscles
 - e. Finger flexion: flexor digitorum superficialis or flexor digitorum profundus
2. Muscle location: ultrasound guidance was used to locate target muscles and control the infiltration technique. Fig. 3 shows ultrasound images of the most frequently infiltrated muscles.
 3. Dosing: drugs were dosed according to the toxin used (Onabotulinum toxin A [Botox[®], Allergan Pharmaceuticals Inc. TB-A, 100 U vial] or Abobotulinum toxin A [Dysport[®], Ipsen Pharmaceuticals, France, 500 U vial]), the patient's body weight, the muscle to be infiltrated, and symptom severity. We referred to the recommendations established in expert guidelines for the treatment of spasticity, adjusted according to the personal experience of the physician performing the infiltrations.^{14,15}
 4. For the subscapularis muscles, teres major, pectoralis major, triceps brachii, pronator teres, and flexor carpi ulnaris or flexor carpi radialis, we used 1 to 2 U/kg Botox[®] or 2 to 4 U/kg Dysport[®]. For the latissimus dorsi, we used

1 to 3 U/kg Botox[®] or 2 to 6 U/kg Dysport[®], and 0.5 to 1 U/kg Botox[®] or 1 to 2 U/kg Dysport[®] for the remaining muscles (pronator quadratus, etc.).

5. Dilution: we reconstituted both toxins with low volumes to prevent as far as possible their spread to other muscles: 1 mL of 0.9% saline solution with no preservatives for the 100 U vial of Onabotulinum toxin A (0.1 mL = 10 U), and 2.5 mL of 0.9% saline solution for the 500 U vial of Abobotulinum toxin A (0.1 mL = 20 U).

Evaluating effectiveness

1. Active movement scale (AMS)¹⁶: based on the observation of spontaneous motion triggered by stimulation against and without gravity, before and after every infiltration. It assesses movement on an 8-point scale, with 0 indicating absence of muscle contraction and 7 indicating full motion (Table 1).
2. Mallet Classification System scale¹⁷: a scale assessing shoulder function. It includes 5 items: global abduction, global external rotation, and hand to neck, spine, and mouth; each is scored from 1 (no motion) to 5 (normal motion, symmetric to the unaffected side). Overall score ranges from a minimum of 5 to a maximum of 25 points (Fig. 4).
3. Video recording before and after infiltration (with signed informed consent).

Table 1 Active movement scale (AMS).

Observations	Muscle grade
<i>Gravity eliminated</i>	
No contraction	0
Contraction, no motion	1
Motion, ≤ half range	2
Motion, > half range	3
Full motion	4
<i>Against gravity</i>	
Motion, ≤ half range	5
Motion, > half range	6
Full motion	7

Recording of adverse effects

We conducted an interview during the follow-up consultations after infiltrations to detect possible adverse reactions to the toxins, which we classified as mild, moderate, or severe.

Results

During the 4-year study period, we assessed 14 133 live births; 15 were diagnosed with OBPP in the neonatal period, which represents an incidence of 1.06 cases per 1000 live births. All patients were delivered vaginally after full-term pregnancies, with a slight predominance of girls (60%). In terms of the overall analysis of the clinical characteristics of OBPP, upper nerve roots were affected in most cases, with

93% of the sample included in groups I and II; the right side was more frequently affected (2/3). Table 2 lists patients' clinical and demographic characteristics.

Nine patients (60%) showed favourable progression with spontaneous, complete remission with conservative treatment, and were therefore excluded from the study. All patients were born after a full-term pregnancy and considered appropriate for gestational age; although they were born by non-instrumented vaginal delivery, shoulder dystocia occurred in 66% of births. No signs of foetal distress were observed, and no patient required resuscitation. In this subgroup with favourable progression, the most frequent type of OBPP was group I (8 cases), mainly affecting the sight side (5:4).

Our final sample included a total of 6 patients with moderate-to-severe OBPP (0.4/1000 live births). All were born after a full-term pregnancy by dystocic delivery (shoulder dystocia), with instrumentation (forceps) required for delivery in 2 cases. Weight ranged from 3740 g to 4450 g, with a mean weight of 4038 g. Weight was considered high for gestational age in 2 cases, whereas the remaining patients were within percentiles 75 to 90. Three patients had an Apgar score < 5, associated with foetal distress. By type of OBPP, the right upper nerve roots were most frequently affected (group II, 5 patients), followed by left total palsy (group IV). No patient presented bone lesions in neuroimaging studies, although we did observe a case of diaphragmatic paralysis among patients in the upper injury group.

All severe cases presented a lack of recovery (biceps contraction) with conservative treatment at the third month of life; from a neurophysiological perspective, a common negative prognostic factor was poor recovery in the

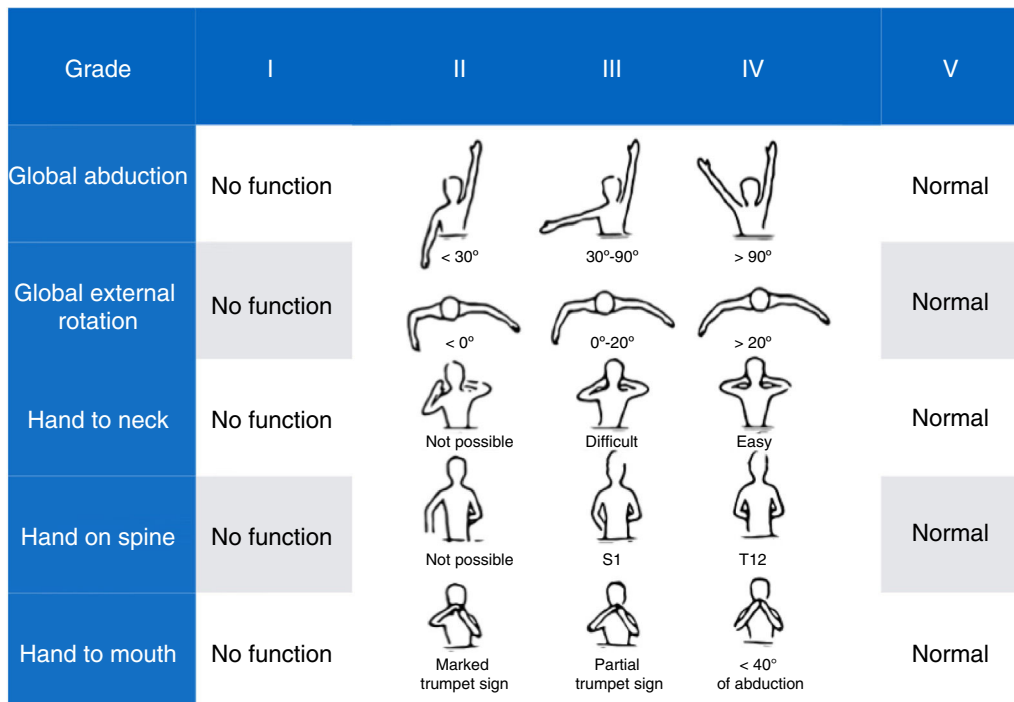


Figure 4 Mallet Classification System.

Table 2 Demographic and clinical characteristics of the sample.

	Age	Sex	Obstetric				OBPP type	Progression
			Gestational age at birth	Birth	Weight	Resuscitation		
1	5 years	Girl	39 + 2	Shoulder dystocia	3730 g (P90)	Apgar 8/9, resus. I	Upper C5-C7 Left	Conservative treatment Complete recovery Discharge at 14 months
2	3 years	Boy	38 + 3	Shoulder dystocia	4020 g (P95)	Apgar 7/9, resus. I	Upper C5-C6 Left	Conservative treatment Complete recovery Discharge at 2 months
3	3 years	Girl	41 + 5	Shoulder dystocia	3680 g (P75)	Apgar 7/9, resus. I	Upper C5-C6 Right	Conservative treatment Complete recovery Discharge at 12 months
4	3 years	Girl	40 + 3	Eutocic	4030 g (P95)	Apgar 7/9, resus. I	Upper C5-C6 Right	Conservative treatment Follow-up at another centre
5	2 years	Girl	40 + 2	Eutocic	4180 g (P98)	Apgar 10/10, no resus.	Upper C5-C6 Left	Conservative treatment Complete recovery Discharge at 6 months
6	21 months	Girl	38 + 4	Shoulder dystocia	3240 g (P65)	Apgar 9/10, no resus.	Upper C5-C6 Left	Conservative treatment Complete recovery Discharge at 19 months
7	11 months	Boy	39	Eutocic	3240 g (P65)	Apgar 0/10, resus. I	Upper C5-C6 Right	Conservative treatment Improvement at 3 months' follow-up Under follow-up
8	11 months	Boy	38 + 6	Shoulder dystocia	3240 g (P65)	Apgar 10/10, no resus.	Upper C5-C6 Right	Conservative treatment Improvement at 3 months' follow-up Under follow-up
9	13 months	Girl	39	Eutocic	3560 g (P75)	Apgar 9/9, no resus.	Upper C5-C6 Right	Conservative treatment Improvement at 3 months' follow-up Under follow-up
10	4 years	Girl	38	Forceps. Shoulder dystocia	4450 g (> P99)	Apgar 2/6, resus. IV	Upper C5-C6 Right Axonotmesis	No recovery after 3 months
11	2 years	Boy	41 + 3	Shoulder dystocia	3880 g (P90)	Apgar 7/9, resus. III	Upper C5-C6 Right Neurotmesis	No recovery after 3 months
12	6 years	Girl	39 + 2	Shoulder dystocia	3740 g (P86)	Apgar 2/7, resus. IV	Right upper C5-C6 Axonotmesis	No recovery after 3 months
13	4 years	Girl	39	Spatula. Shoulder dystocia	3800 g (P90)	Apgar 1/3/5/7, resus. V	Upper C5-C7 Right Axonotmesis	No recovery after 3 months Diaphragmatic paralysis
14	2 years	Boy	39	Shoulder dystocia	3740 g (P86)	Apgar 9/10, no resus.	Upper C5-C6 Right Neurotmesis	No recovery after 3 months
15	3 years	Boy	38 + 6	Shoulder dystocia	4380 g (> P99)	Apgar 8/9, no resus.	Complete left Neurotmesis	No recovery after 3 months Complete paralysis Horner syndrome

electromyographical study due to severe nerve lesions (neurotmesis and axonotmesis).

Infiltrations were started at ages ranging from the sixth to eighteenth month of life (mean 11.5 months), with a mean number of 3 infiltrations per patient. The most frequently infiltrated muscles were the subscapularis muscle,

teres major, pectoralis major, latissimus dorsi, and pronator teres, which received infiltrations at least once in all treated cases, followed by the pronator quadratus and flexor carpi ulnaris.

Doses of BoNT-A were adjusted according to the patient's characteristics, response to previous infiltrations, and the

type of toxin used. We used one adjusted dose per session and patient weight, which ranged from 8 to 10 U/kg for onabotulinum toxin A, 100 U vial, and 18 to 22 U/kg for abobotulinum toxin A, 500 U vial. We used an initial dose of 1 U/kg of onabotulinum toxin A for the subscapularis muscle, teres major, pectoralis major, flexor carpi ulnaris or flexor carpi radialis muscle, flexor digitorum superficialis, and pronator quadratus, and 2 U/kg for latissimus dorsi, biceps, triceps brachii, and pronator teres. Abobotulinum toxin A was initially administered at 4 U/kg for the latissimus dorsi and pronator teres, 3 U/kg for the subscapularis muscle, teres major, and pectoralis major, and 2 U/kg for the remaining muscles.

All patients received infiltrations at least twice, with 83.5% remaining under treatment and clinical follow-up. One patient was lost to follow-up due to a change of residence. From the first infiltration, we observed AMS score improvements of one level in the patient with total palsy and 2 levels in the remaining upper injury groups; symptoms improved 2 to 3 weeks after infiltration and mean duration of the relief was 4 months, with a drop of one level on the scale from that time. An additional infiltration before patients returned to the baseline situation, together with other treatments (occupational therapy, physical therapy, and/or surgery), enabled improvement of the limb to continue until patients reached level 6 on the AMS and a mean of 19.5 points out of 25 on the Mallet Classification System scale at 2 years' progression in all cases of upper injury who completed follow-up.

Furthermore, regular infiltrations enabled us to avoid surgery in 3 patients and delay it on 2 occasions (case 1). All patients presented improvements in limb function and abnormal posture. Data on patients' progression are listed in [Table 3](#).

Regarding adverse effects of the infiltration technique, 2 patients (cases 2 and 6) presented mild, self-limiting adverse effects (post-infiltration haematoma, muscle pain in the second infiltration); another 2 cases (1 and 5) presented weakness with almost complete, self-limited palsy of the limb, with functional recovery at about 3 weeks, also during the second infiltration and with an increased dose ([Table 3](#)). No patient presented adverse reactions related to analgesia/sedation.

Discussion

Obstetric lesion of the brachial plexus is caused by a lateral traction injury to the nerve roots during delivery. Prognosis depends on the severity and extension of the lesion; although it is favourable in most cases, with complete recovery during the first months of life, almost one-third of patients display permanent sequelae limiting movement, strength, and even the size and thickness of the muscle affected.^{5–8}

A conservative approach has been traditionally adopted, observing the degree of spontaneous recovery and later scheduling such palliative surgical treatment as tendon transfer, osteotomy, or arthrodesis. However, the current trend is towards early treatment during the first months of life.¹⁸

This approach is controversial due to the difficulty of properly selecting candidates and discriminating between those with a favourable or a poor prognosis. Biceps recovery is one of the basic pillars in natural progression, since recovery at 2 months is a predictor of spontaneous, complete recovery in most cases, whereas absence of contraction at 3 months is predictive of the need for surgical treatment.¹²

BT represents an intermediate approach between watchful waiting and invasive treatment. Its main indication in neurology has traditionally been the treatment of various syndromes progressing with muscle hyperactivity: spasticity of any aetiology, dystonias, hemifacial spasm, facial synkinesis, tics and tremors, etc.¹⁹ However, it may also be useful for numerous other indications, such as in muscle imbalances caused by nerve lesions, as in the case of OBPP.^{9,20}

BoNT-A selectively, temporarily, and reversibly blocks cholinergic neurotransmission at the neuromuscular junction of the healthy antagonist muscles. It aims to compensate for the muscle imbalance generated by the plexopathy and prevent the development of pathological motor learning patterns and a possible aberrant reinnervation.^{9,10,20}

Despite limited evidence on the efficacy of BoNT-A in this pathology, due to the scarcity of published studies and the lack of randomised controlled trials, the available data show benefits for the elbow joint, with improved flexion and supination from the first infiltrations and persisting for over a year when infiltrations are repeated every 3 to 5 months.^{9,10,21–23}

In our series, all patients showed improvement on the scales used, both in the shoulder and the elbow joint from the first infiltration, with progressive improvement in both joints with periodic infiltrations every 3 to 6 months. This benefit was also subjectively reported by patients' parents and observed when reviewing the audiovisual material (video recordings) of the patients, with a significant improvement in movement patterns and shoulder function.

As in other published series, it was possible to use BoNT-A independently of other treatments, and even as adjuvant treatment to brachial plexus surgery.^{23,24} The combination of both treatments in 2 of our patients resulted in better scores on the AMS and preserved shoulder elevation/abduction and elbow supination during progression. BoNT-A infusions enabled us to postpone surgery on 2 occasions in one patient; the level of improvement observed after surgery was higher than with BoNT-A alone.

Although our study presents some limitations, such as the limited sample size ($N = 15$), we believe that our series is reasonably heterogeneous and representative of everyday clinical practice. We obtained an incidence rate similar to that published in other series, with a sample obtained from a population also similar in terms of culture and socioeconomic level; both the symptoms and the dysfunctions caused by the disease were those expected in this group of patients.

Our main contribution is the infiltration technique, since the precise localisation of BT in the target muscle is currently believed to be more important than dose and dilution in reducing adverse effects, avoiding spread to adjacent muscles, and obtaining the greatest possible therapeutic effects with the lowest possible dose.²⁵ Unlike in other studies, our patients received ultrasound-guided infiltrations, increasing the accuracy of the technique, and with

Table 3 Progression of patients treated with botulinum toxin A.

	Start of infiltrations	No. of infiltrations	Adverse effects	AMSPre	Post	Mallet system/AMS (2 years)	Final function
Case 1	7 months	8 (+ surgery)	Transient palsy	3	5	18/6	Improved supination Full elevation Forearm flexion
Case 2	9 months	3	Haematoma after infiltration	2	3	18/6	Improved supination (+5°) Full elevation Full forearm flexion
Case 3	18 months	6	None	3	5	22/6	Arm elevation, 150° Forearm flexion Improved supination, 30°
Case 4	14 months	2	None	3	5	Drop-out	Improved arm elevation
Case 5	6 months	4 (+ neurolysis)	Transient palsy	3	5	20/6	Improved supination Full elevation Forearm flexion
Case 6	10 months	3 (+ surgery)	Pain after infiltration	2	3	13/5	Arm elevation, 80° Full forearm flexion Minimum supination

low dilution volumes to avoid toxin spread to other muscles. This may be the reason why we obtained better scores and limb function in all treated cases, with an acceptable rate of adverse effects. Due to this increased accuracy of infiltration, we were able to use somewhat lower doses than those of similar studies,¹⁰ with no negative impact on results.

Finally, we should highlight the importance of early identification of cases of OBPP requiring treatment (surgical or non-surgical) to prevent permanent motor sequelae. Given its safety and effectiveness, it seems reasonable to use this off-label indication of BoNT-A as an adjuvant treatment to physical therapies and/or surgical treatment for moderate-severe OBPP. It should be noted that our conclusions are limited by a lack of prospective and randomised studies with long-term follow-up and using functional assessment scales with standardised scoring systems, which may support our results.

Conflicts of interest

The authors have no conflicts of interest to declare.

References

1. Chauhan SP, Blackwell SB, Ananth CV. Neonatal brachial plexus palsy: incidence, prevalence, and temporal trends. *Semin Perinatol.* 2014;38:210–8.
2. Foad SL, Mehlman CT, Ying J. The epidemiology of neonatal brachial plexus palsy in the United States. *J Bone Joint Surg Am.* 2008;90:1258–64.
3. Chauhan SP, Rose CH, Gherman RB, Magann EF, Holland MW, Morrison JC. Brachial plexus injury: a 23-year experience from a tertiary center. *Am J Obstet Gynecol.* 2005;192:1795–800.
4. Collado-Vázquez S, Jiménez-Antona C, Carrillo J. Parálisis braquial obstétrica, una revisión histórica. *Rev Neurol.* 2012;55:619–25.
5. Abzug JM, Kozin SH. Evaluation and management of brachial plexus birth palsy. *Orthop Clin North Am.* 2014;45:225–32.
6. Pondaag W, Malessy MJA. The evidence for nerve repair in obstetric brachial plexus palsy revisited. *BioMed Res Int.* 2014;2014:434619.
7. Pondaag W, Gert van Dijk, Thomeer R. TWM. Natural history of obstetric brachial plexus palsy: a systematic review. *Dev Med Child Neurol.* 2004;46:138–44.
8. Bae DS, Ferretti M, Waters PM. Upper extremity size differences in brachial plexus birth palsy. *Hand (N Y).* 2008;3:297–303.
9. Arad E, Stephens D, Curtis CG, Clarke HM. Botulinum toxin for the treatment of motor imbalance in obstetric brachial plexus palsy. *Plast Reconstr Surg.* 2013;131:1307–15.
10. Shin YB, Shin MJ, Chang JH, Cha YS, Ko HY. Effects of botulinum toxin on reducing the co-contraction of antagonists in birth brachial plexus palsy. *Ann Rehabil Med.* 2014;38:127–31.
11. Basciani M, Intiso D. Botulinum toxin type-A and plaster cast treatment in children with upper brachial plexus palsy. *Pediatr Rehabil.* 2006;9:165–70.
12. Gilbert A, Tassin JL. Surgical repair of the brachial plexus in obstetric paralysis. *Chirurgie.* 1984;110:70–5.
13. Narakas AO. Obstetric brachial plexus injuries. In: Lamb DW, editor. *The paralysed hand. The hand and upper limb.* Edinburgh [Lothian]. New York, NY: Churchill Livingstone; 1987. p. 116–35.
14. Pascual Pascual SI, Herrera Galante A, Póo P, García-Aymerich V, Aguilar-Barberà M, Bori-Fortuny I, et al. Guía terapéutica de la espasticidad infantil con toxina botulínica. *Rev Neurol.* 2007;44:303–9 (Grupo Español de Espasticidad).
15. Heinen F, Desloovere K, Schroeder AS, Berweck S, Borggraefe I, van Campenhout A, et al. The updated European Consensus. 2009 on the use of botulinum toxin for children with cerebral palsy. *Eur J Paediatr Neurol.* 2010;14:45–66.
16. Curtis C, Stephens D, Clarke HM, Andrews D. The active movement scale: an evaluative tool for infants with obstetric brachial plexus palsy. *J Hand Surg Am.* 2002;27:470–8.
17. Mallet J. Obstetric paralysis of the brachial plexus. II. Therapeutics. Treatment of sequelae. Priority for the treatment of the shoulder. Method for the expression of results. *Rev Chir Orthop Reparatrice Appar Mot.* 1972;58 Suppl. 1:166–8.
18. Socolovsky M, Costales JR, Paez MD, Nizzo G, Valbuena S, Varone E. Obstetric brachial plexus palsy: reviewing the literature

- comparing the results of primary versus secondary surgery. *Childs Nerv Syst.* 2016;32:415–25.
19. Walter U, Dressler D. Ultrasound-guided botulinum toxin injections in neurology: technique, indications and future perspectives. *Expert Rev Neurother.* 2014;14:923–36.
 20. Van Dijk JG, Pondaag W, Malessy MJ. Botulinum toxin and the pathophysiology of obstetric brachial plexus lesions [Letter to Editor]. *Dev Med Child Neurol.* 2007;49:318.
 21. Rollnik JD, Hierner R, Schubert M, Shen ZL, Johannes S, Tröger M, et al. Botulinum toxin treatment of cocontractions after birth-related brachial plexus lesions. *Neurology.* 2000;55:112–4.
 22. Desiato Mt Risina B. The role of botulinum toxin in the neuro-rehabilitation of Young patients with brachial plexus brith palsy. *Pediatr Rehabil.* 2001;4:29–36.
 23. DeMatteo C, Bain JR, Galea V, Gjertsen D. Botulinum toxin as an adjunct to motor learning therapy and surgery for obstetrical bracial plexus injury. *Dev Med Child Neurol.* 2006;48:245–52.
 24. Price AE, DiTaranto P, Yaylali I, Tidwell MA, Grossman JA. Botulinum toxin type A as an adjunct to the surgical treatment of the medial rotation deformty of the shoulder in girth injuries of the brachial plexus. *J Bone Joint Surg Br.* 2007;89:327–9.
 25. Shaari C, Sanders I. Quantifying how location and dose of botulinum toxin injections affect muscle paralysis. *Muscle Nerve.* 1993;16:964–9.