




SOCIEDAD ESPAÑOLA  
DE NEUROLOGÍA

# NEUROLOGÍA

[www.elsevier.es/neurologia](http://www.elsevier.es/neurologia)



## LETTERS TO THE EDITOR

### Malnutrition and Wernicke encephalopathy in the elderly<sup>☆</sup>



### Desnutrición en el anciano y encefalopatía de Wernicke

Dear Editor:

Wernicke encephalopathy (WE) is the main neurological disorder caused by deficiency of the cofactor thiamine, which is crucial in energy metabolism; magnesium is also involved as a thiamine cofactor.<sup>1</sup> WE can be alcoholic or non-alcoholic<sup>2</sup> (caused by malnutrition or increased water-soluble vitamin loss, as in dialysis). Prevalence of WE lesions in autopsy studies has been reported to be 12.5% in alcoholics<sup>3</sup> and 30% to 60% in alcohol-related fatalities.<sup>4,5</sup> WE is a little-recognised and underdiagnosed condition. Although WE is more prevalent in men, women are more susceptible.<sup>6,7</sup> Diagnosis is clinical and early treatment is fundamental in preventing coma and death.

We present the case of an 81-year-old woman (height 1.58 m, weight 58 kg, BMI 23.2), who was autonomous in the activities of daily living before symptom onset.

Her personal history included 10 years of schooling, no history of alcohol abuse, hypertension, hiatal hernia diagnosed 18 years previously, anti-reflux surgery 15 years previously, cholecystectomy, and acute biliary pancreatitis. She was being treated with pantoprazole, domperidone, ursodeoxycholic acid, candesartan, mexazolam, mirtazapine, and brotizolam.

Two to 3 weeks after an influenza episode, she developed anorexia, dehydration, mental confusion, altered sleep-wake cycle, and visual and gait impairment.

Physical examination revealed somnolence, disorientation in time but not space, incoherent speech, strabismus, persistent horizontal-rotary nystagmus, dysphagia for liquids, and hypotonia. The patient was haemodynamically stable, with normal results in the cardiopulmonary auscultation and sinus rhythm in the electrocardiography. Blood analysis revealed no anaemia or leukocytosis and a normal level of C-reactive protein. Urine benzodiazepine levels were twice the normal value. Head CT scan findings were normal but at 24 hours she presented a suspected

lacunar stroke of the right tectal plate (Fig. 1A), requiring examination with brain MRI. A transthoracic echocardiography did not detect cardioembolism, and lumbar puncture returned normal results.

She started treatment with thiamine at high doses (500 mg IV every 8 hours for 2 days, 500 mg IV every 24 hours for 5 days), then at 100 mg IV every 8 hours during the remaining days of hospitalisation, combined with a multivitamin solution (vitamin A, B, H [biotin], and F) and protein-calorie supplementation.

She was initially admitted to the stroke unit to rule out brainstem stroke. We observed a significant clinical improvement, with decreased nystagmus, improved verbal expression, and corrected sleep pattern. A brain MRI (Fig. 1B-G) performed at day 5 of admission revealed diffuse hyperintensity of the tectum, periaqueductal region, medial thalami, mammillary bodies, and structures adjacent to the diencephalon and cortical convexity with brain atrophy; these findings are indicative of WE.

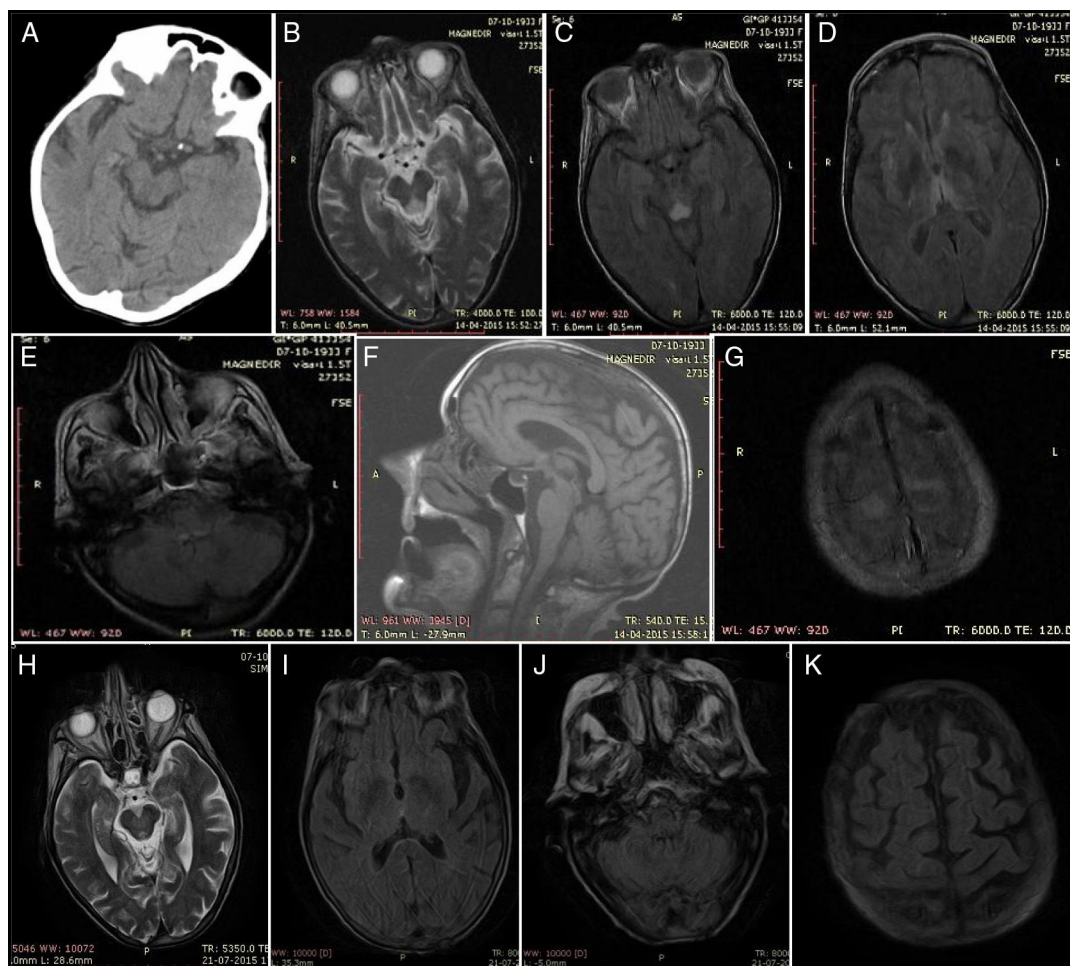
At day 6 of admission, the patient was transferred to the neurology department. She was awake, with no spontaneous verbal response, strabismus (exotropia of the right eye), isochoric and reactive pupils (preserved photomotor and consensual reflexes), and mild horizontal-rotatory nystagmus. The patient presented no motor deficit and did not collaborate in the examination. Enteral feeding via nasogastric tube was continued; the patient's body weight was 39 kg (BMI: 15.6).

The examination revealed a haemoglobin level of 7.8 g/dL; haematocrit, 24% (normal range, 36-46); vitamin B<sub>1</sub>, 27 ng/mL (28-85); vitamin B<sub>12</sub>, 158 pg/mL (187-883); vitamin D, 17 ng/mL (30-100); magnesium, 1.37 mg/dL (1.6-2.6); sodium, 135 mg/dL (136-145); proteins, 5.3 g/dL (6.4-8.3), and albumin, 2.9 g/dL (3.2-4.6). Results of the analysis of MCV and MCH (red blood cells), folic acid, ammonia, thyroid function, and calcium and phosphate metabolism were normal. Intrinsic factor antibody test and serological test for syphilis yielded negative results.

She received a transfusion of 1U of red blood cells; thiamine was maintained at 100 mg IV every 8 hours; pantoprazole was withdrawn and ranitidine started at 150 mg at night. The patient also started treatment with oral vitamin B<sub>12</sub> at 5 mg/day, cholecalciferol 667 IU/day, magnesium 10 mL/12 h, calcium carbonate 500 mg/12 h, and 0.9% saline solution.

During the first 2 weeks of progression, her speech improved and she was able to produce sentences; nystagmus manifested only at extreme lateral gaze. Ataxic gait was later identified and she started rehabilitation.

<sup>☆</sup> Please cite this article as: Ros Forteza FJ, Cabrera H, Bousende M. Desnutrición en el anciano y encefalopatía de Wernicke. Neurología. 2019;34:543–546.



**Figure 1** *Baseline findings:* (A) Head CT at 24 hours: hypodensity in the right tectal plate. (B) Axial T2-weighted MRI sequence. (C) Axial FLAIR MRI sequence: lesion to the midbrain periaqueductal region. (D) Axial FLAIR MRI sequence: bilateral thalamic lesions. (E) Axial FLAIR MRI sequence: tectal lesion. (F) Sagittal T1-weighted MRI sequence: no alterations. (G) Axial FLAIR MRI sequence: lesion to the superior frontal cortex and pia mater. *Findings at resolution:* (H) Axial T2-weighted MRI sequence: regressing periaqueductal lesion. (I) Axial FLAIR MRI sequence: no thalamic lesion. (J) Axial FLAIR MRI sequence: no bulbar lesion. (K) Axial FLAIR MRI sequence: no lesion to the cortex or pia mater.

At one month of progression, we performed an awake EEG (Fig. 2), which revealed slow background activity, suggesting diffuse brain dysfunction (grades 2-3). Vitamin B<sub>1</sub> level was 193 ng/mL. The patient was transferred to another institution for recovery and continued with feeding via nasogastric tube.

From the second month of treatment, our patient presented good general appearance, fluent and coherent speech, an MMSE score of 23 (4 in orientation, 3 in registration, 4 in attention and calculation, 3 in recall, and 9 in language and copying); she was self-critical, interacted with her family, and could walk only with assistance. She needed help eating and with personal care. The patient participated in craft activities and regular rehabilitation sessions.

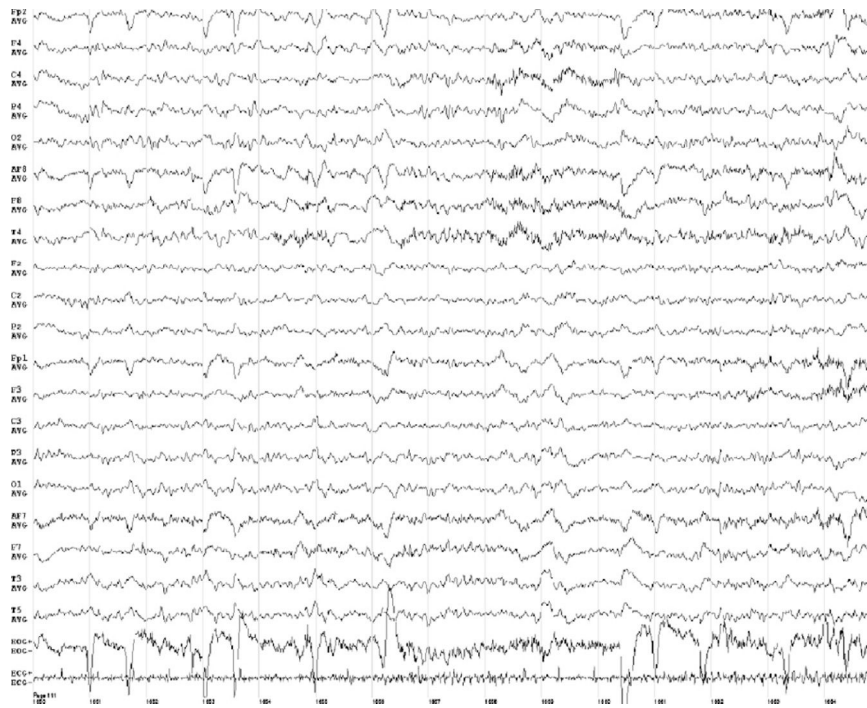
At 3 months, a significant improvement was observed in her nutritional status and she walked with a walker; a brain MRI scan revealed complete remission of the brain lesions (Fig. 1H-K).

The neuropsychological evaluation showed that autobiographical memory was preserved. We were able to apply only

3 subtests of the Wechsler Adult Intelligence Scale (WAIS-III): matrix reasoning, similarities, and digit span; results were higher level, average level, and average level, respectively. No areas of deficit were identified.

WE should be considered in the differential diagnosis of all patients with delirium<sup>8</sup> or acute ataxia. Structural diseases of the medial thalamus, hippocampus, or the inferior medial region of the temporal lobe should also be considered due to the similar neuroanatomical involvement to WE. These include top of the basilar syndrome, hypoxic-ischaemic encephalopathy following cardiac arrest, herpes simplex encephalitis, and third ventricle tumour.<sup>9,10</sup>

Age of onset in our patient is atypical (eighth decade of life); she presented the classic triad of WE (encephalopathy, oculomotor dysfunction, and ataxia), although it was not observed at admission. In this case, WE was severe and was caused by malnutrition.<sup>11</sup> She lost 33% of her body weight, with a BMI of 15.6 (BMI below 16 corresponds to grade 3/severe thinness according to the WHO classifications [1995,2000]).



**Figure 2** EEG showing slow background activity.

Protein-calorie deficiency is not always present; in a review of 625 cases reported in the literature, the cause of WE was fasting or malnutrition in 10.2% of cases.<sup>12</sup>

Brain MRI showed the characteristic findings of WE, but this test is more sensitive for detecting WE lesions in non-alcoholic than in alcoholic patients<sup>13</sup>; clinical progression was excellent with vitamin supplementation.

Regarding the pathophysiology of these symptoms, thiamine reserves were depleted in 2-3 weeks due to caloric restriction. In the event of thiamine depletion, the function of the thiamine-dependent enzyme systems deteriorates and blood thiamine levels decrease. This damage occurs 4 days after onset of thiamine deficiency and eventually progresses to programmed cell death. At 14 days, brain lesions develop.<sup>11</sup> It is probable that some subjects with genetically reduced transketolase activity require higher levels of thiamine and therefore present a higher risk of WE in situations of increased demand or lower absorption.<sup>13</sup> The low level of magnesium (a thiamine cofactor) also helped in the development of the disease. Other associated factors were vitamin B<sub>12</sub> deficiency (long-term use of pantoprazole suppresses gastric acid production, which may lead to vitamin B<sub>12</sub> malabsorption<sup>14</sup>), and vitamin D and albumin deficiency.

Our case is interesting as despite the several weeks of progression with altered mental state, vision, and gait, the first diagnostic hypothesis was vertebrobasilar stroke. Furthermore, WE was diagnosed in a context of severe malnutrition in a non-alcoholic patient, despite symptoms and neuroimaging findings being more typical of an alcoholic patient.

We propose that WE should be considered in patients of advanced age with altered level of consciousness of unknown cause, even in non-alcoholic patients; infusion of

thiamine should be started immediately when the disorder is suspected, even in the absence of typical symptoms.

With this case, we aim to raise awareness of the need to identify this preventable, treatable, and high-mortality disease.

## References

1. Mclean J, Manchip S. Wernicke's encephalopathy induced by magnesium depletion. *Lancet*. 1999;353:1768.
2. Lindboe CF, Løberg EM. Wernicke's encephalopathy in non-alcoholics. An autopsy study. *J Neurol Sci*. 1989;90:125-9.
3. Torvik A, Lindboe CF, Rogde S. Brain lesions in alcoholics. A neuropathological study with clinical correlations. *J Neurol Sci*. 1982;56:233-48.
4. Naidoo DP, Bramdev A, Cooper K. Autopsy prevalence of Wernicke's encephalopathy in alcohol-related disease. *S Afr Med J*. 1996;86:1110-2.
5. Skullerud K, Andersen SN, Lundevall J. Cerebral lesions and causes of death in male alcoholics. A forensic autopsy study. *Int J Legal Med*. 1991;104:209-13.
6. Victor M, Adams RA, Collins GH. *The Wernicke-Korsakoff syndrome and related disorders due to alcoholism and malnutrition*. Philadelphia, PA: Fa Davis; 1989.
7. Harper C. The incidence of Wernicke's encephalopathy in Australia—a neuropathological study of 131 cases. *J Neurol Neurosurg Psychiatry*. 1983;46:593-8.
8. O'Keefe ST, Tormey WP, Glasgow R, Lavan JN. Thiamine deficiency in hospitalized elderly patients. *Gerontology*. 1994;40:18-24.
9. Yoneoka Y, Takeda N, Inoue A, Ibuchi Y, Kumagai T, Sugai T, et al. Acute Korsakoff syndrome following mammillothalamic tract infarction. *AJNR Am J Neuroradiol*. 2004;25:964-8.
10. Renou P, Ducreux D, Batouche F, Denier C. Pure and acute Korsakoff syndrome due to a bilateral anterior fornix infarction: a diffusion tensor tractography study. *Arch Neurol*. 2008;65:1252.



11. Hutcheon DA. Malnutrition-induced Wernicke's encephalopathy following a water-only fasting diet. *Nutr Clin Pract.* 2015;30:92–9.
12. Galvin R, Brathen G, Ivashynka A, Hillbom M, Tanasescu R, Leone MA. EFNS guidelines for diagnosis, therapy and prevention of Wernicke encephalopathy. *Eur J Neurol.* 2010;17:1408–18.
13. Gascón-Bayarri J, Campdelacreu J, García-Carreira MC, Estela J, Martínez-Yélamos S, Palasí A, et al. Encefalopatía de Wernicke en pacientes no alcohólicos: una serie de 8 casos. *Neurología.* 2011;26:540–7.
14. Lam JR, Schneider JL, Zhao W, Corley DA. Proton pump inhibitor and histamine 2 receptor antagonist use and vitamin B<sub>12</sub> deficiency. *JAMA.* 2013;310:2435–42.

F.J. Ros Forteza<sup>a,b,\*</sup>, H. Cabrera<sup>b,c</sup>, M. Bousende<sup>d</sup>

<sup>a</sup> *Serviço de Neurologia, Unidade Local de Saúde da Guarda, EPE, Guarda, Portugal*

<sup>b</sup> *Departamento de Ciências Médicas, Faculdade de Ciências da Saúde (UBI), Covilhã, Portugal*

<sup>c</sup> *Serviço de Medicina Interna, ULS-Guarda, EPE, Guarda, Portugal*

<sup>d</sup> *Serviço de Neurorradiologia, Centro Hospitalar São João, EPE, Porto, Portugal*

\* Corresponding author.

E-mail address: javierros40@hotmail.com

(F.J. Ros Forteza).

<https://doi.org/10.1016/j.nrleng.2018.11.005>  
2173-5808/

© 2018 Published by Elsevier España, S.L.U. on behalf of Sociedad Española de Neurología. This is an open access article under the CC BY-NC-ND license (<http://creativecommons.org/licenses/by-nc-nd/4.0/>).

## New mutation in a patient with Charcot-Marie-Tooth disease<sup>☆,☆☆</sup>



## Nueva mutación genética en un caso de enfermedad de Charcot-Marie-Tooth

Dear Editor:

Charcot-Marie-Tooth disease (CMT) is a type of hereditary sensorimotor polyneuropathy which may be caused by a great variety of genetic alterations<sup>1</sup>; new alterations continue to be identified.

We present the case of a 39-year-old patient diagnosed with CMT type 1 during childhood. His mother also has the disease but with mild clinical symptoms.

Examination of the patient revealed distal amyotrophy with weakness, steppage gait, and areflexia. Neurophysiological studies have always shown decreased conduction velocity and amplitudes of motor potentials; sensory potentials could not be elicited. At the time, the patient and his partner were trying to conceive.

A genetic study was conducted in 2015. Proceeding gradually, the study began with genotyping with polymerase chain reaction and allele-specific oligonucleotide of a battery of polymorphisms distributed throughout the CMT1/HNPP region (17p11.2), with no evidence of duplication or deletion. Massively parallel sequencing was performed for 7 genes from the panel associated with autosomal dominant CMT type 1; this did not reveal any clearly pathogenic variant associated with the disease. The study was

subsequently expanded to 42 genes, which revealed a mutation of the *SBF1* gene (c577C>T [pArg193Trp]) in heterozygosis and a mutation of the *GJB1* gene (c.476\_481del [pGly159\_Tyr160del]) in hemizygosis; since these are not pathogenic variants clearly associated with CMT disease, we conducted a Sanger confirmation and a cosegregation study in the patient's mother.

We confirmed presence of the mutation (c.476\_481del [pGly159\_Tyr160del]) and the mother was found to be a carrier of the mutation in heterozygosis.

We describe a new mutation of the *GJB1* gene, located at Xq13.1 and coding for gap junction beta-1 protein (or connexin 32),<sup>2</sup> in a patient with demyelinating CMT with an X-linked dominant inheritance pattern. Variations of this gene are the second most frequent genetic alteration observed, following duplication of the *PMP22* gene at chromosome 17p11.2-p12.<sup>2,3</sup>

Curiously, in these X-linked forms, motor conduction velocities are not homogeneous in different nerves; nor are they as decreased as in autosomal dominant forms.<sup>3,4</sup> These forms can also be associated with disorders of the central nervous system<sup>5</sup>; we therefore requested a brain magnetic resonance imaging scan in our patient, which yielded normal results.

In conclusion, we deem it important to characterise and communicate these alterations, both for the purpose of genetic counselling (as illustrated by our patient) and with a view to the potential prognostic and therapeutic implications of future research.

## References

1. Pareyson D, Marchesi C. Diagnosis, natural history, and management of Charcot-Marie-Tooth disease. *Lancet Neurol.* 2009;8:654–67.
2. Ouvrier R, Geevasingha N, Ryan MM. Autosomal-recessive and X-linked forms of hereditary motor and sensory neuropathy in childhood. *Muscle Nerve.* 2007;36:131–43.
3. Carter GT, Weiss MD, Han JJ, Chance PF, England JD. Charcot-Marie-Tooth disease. *Curr Treat Options Neurol.* 2008;10:94–102.

<sup>☆</sup> Please cite this article as: Domínguez Díez FJ, López Alburquerque JT. Nueva mutación genética en un caso de enfermedad de Charcot-Marie-Tooth. *Neurología.* 2019;34:546–547.

<sup>☆☆</sup> This study has been presented at the 68th Annual Meeting of the Spanish Society of Neurology in Valencia (17 November 2016).