

## LETTERS TO THE EDITOR

## Difficulties in diagnosing absence seizures in adults<sup>☆</sup>



### Sobre la dificultad diagnóstica de las ausencias en el adulto

Dear Editor,

Witness accounts of the characteristics of a convulsive seizure serve as the basis for the diagnosis, classification, and treatment of epileptic syndromes; however, no such account is available in many cases.

In clinical practice, one-third of focal seizures with cognitive alterations are not controlled by antiepileptic drugs, with misdiagnosis remaining common. For this reason, video electroencephalography (EEG) monitoring is invaluable in the diagnosis, classification, and treatment of epilepsy.

We present a case which demonstrates the potential difficulty of evaluating an adult patient with absence seizures, in which treatment and “resetting” the clinical history were a help in correctly diagnosing the condition and selecting an appropriate treatment.

The patient was a 45-year-old man who was referred from another hospital, with no relevant family history; 15 years earlier, he had developed recurrent “disconnections” from his surroundings accompanied by occasional oral automatism, lasting approximately 5 seconds, during which posture was maintained. These episodes featured no associated sensory aura, dystonic posture, or tonic-clonic seizures and occurred approximately 4 times per day; the patient had no memory of the event. The physical examination revealed no pathological findings. Given the symptoms described, the patient was diagnosed with temporal lobe epilepsy (with complex partial seizures).

A brain magnetic resonance imaging scan yielded normal results, as did a blood test with complete blood count; studies of liver function, iron metabolism, and kidney

function; and an autoimmune study. EEGs were performed on 3 occasions, always displaying normal readings.

The patient was treated with various antiepileptic drugs, both in monotherapy and in combination therapy. Drugs administered were: clonazepam, lamotrigine, and valproate, which did not achieve seizure control; oxcarbazepine, perampanel, and pregabalin, which were withdrawn due to adverse effects; and carbamazepine and lacosamide, which increased seizure frequency. The patient’s diagnosis was reconsidered due to the exacerbation caused by the latter 2 drugs, and a video EEG was performed, successfully recording a seizure. The reading displayed a generalised, synchronous, symmetrical 3.5-Hz spike-and-wave discharge (Fig. 1), which lasted 7 seconds and coincided with the patient’s disconnection from his surroundings and oral automatism.

A discussion of the patient’s clinical history with family members revealed that his school teacher had complained of frequent “distractions” in class when the patient was 14 years old. These went unnoticed as they were never witnessed by the family.

Given the new information provided by the family and the video EEG results, the patient was diagnosed with juvenile absence epilepsy (JAE) and started with zonisamide and levetiracetam, which reduced seizure frequency to one per month.

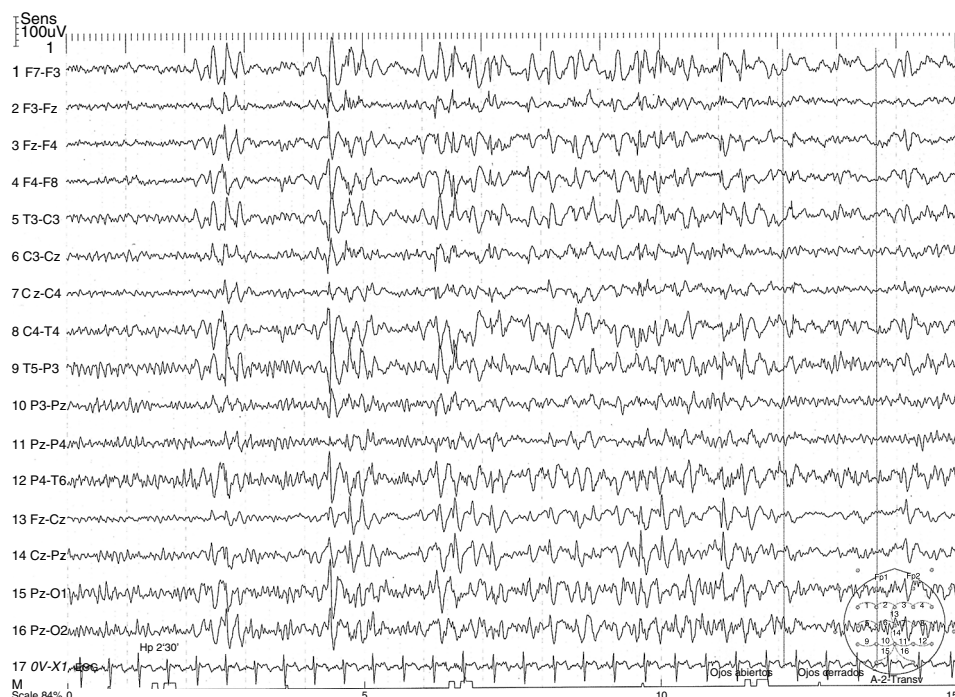
JAE accounts for approximately 10% of cases of idiopathic generalised epilepsy,<sup>1</sup> generally appearing during adolescence and improving from the fourth decade of life.

EEG typically reveals generalised, synchronous, symmetrical, 3.5-Hz spike-and-wave discharge, coinciding with an altered level of consciousness, usually lasting 5–20 seconds.

Some studies suggest that calcium channels are a key factor in absence seizure pathogenesis.<sup>2</sup> As is the case with most types of idiopathic generalised epilepsy, genetic factors play a more important role than environmental factors. Like childhood absence epilepsy, JAE manifests as an abrupt change in the patient’s level of consciousness, with total or partial absence of response to external stimuli. This is frequently associated with palpebral myoclonic movements and oral automatism. In comparison to childhood absence seizures, JAE seizures tend to be longer in duration (mean duration, 16 seconds), are not clearly related with circadian rhythm (seizures occur shortly after awakening), affect level of consciousness less severely, tend to be associated with generalised tonic-clonic seizures (in up to 80% of cases), and occasionally feature mild myoclonic tremor of the type observed in juvenile myoclonic epilepsy (15%–25% of cases).

<sup>☆</sup> Please cite this article as: Camacho Velásquez JL, Rivero Sanz E, Sanabria Sanchinel AA, Santos Lasoosa S, Mauri Llerda JA. Sobre la dificultad diagnóstica de las ausencias en el adulto. Neurología. 2018;33:403–405.

This study has not been submitted previously to any journal, nor has it been presented at any meeting or congress.



**Figure 1** Electroencephalography reading showing a generalised synchronous, symmetrical, 3.5-Hz spike-and-wave discharge.

Interictal EEG readings are usually normal and seizures are often triggered by hyperventilation; video EEG is usually the diagnostic test of choice. Neuroimaging studies do not reveal pathological abnormalities.

Nearly 80% of patients remain seizure-free with classic antiepileptic drugs such as ethosuximide and valproate; levetiracetam is also a good treatment option.<sup>3</sup> Inadequate seizure control may lead to the development of atypical absence seizures, particularly in patients treated with such drugs as carbamazepine, oxcarbazepine, vigabatrin, gabapentin, and pregabalin.

This case demonstrates the potential difficulty involved in differentiating complex partial seizures from absence seizures in adult patients. In our patient, the normal results in the routine EEG and the lack of consideration given to the “distractions” in class resulted in a misdiagnosis of temporal lobe epilepsy. This led to the administration of incorrect and occasionally contraindicated treatments (carbamazepine, lacosamide, oxcarbazepine, and pregabalin), exacerbating the absence seizures. It was this exacerbation that led us to reassess the diagnosis and therapeutic approach, confirming the new diagnosis with video EEG.

Animal models have shown that correct, early treatment not only suppresses seizures, but also prevents the development of associated histological alterations.<sup>4</sup>

Zonisamide is an antiepileptic drug that stabilises the cell membrane and acts on voltage-dependent sodium channels and calcium channels<sup>5,6</sup>; the latter are one of the main factors involved in the pathophysiology of absence seizures. Responder rates for the drug are 87.5% in cases of typical absence seizures and 46.3% for atypical seizures<sup>7</sup>; the drug rarely causes severe adverse effects, even at high doses.

The main differential diagnosis to be taken into account is mesial temporal lobe epilepsy, which is clinically characterised by prodromes, complex automatism, and

postictal confusion<sup>8</sup>; the latter symptom is not usually present in adult and/or juvenile absence seizures. Mesial temporal lobe epilepsy also displays markedly different EEG readings and more severe cognitive alterations than JAE. Another diagnosis that should be considered is juvenile myoclonic epilepsy, which may present as disconnection from the patient’s surroundings; however, this condition is distinguished by myoclonic jerks, distribution following the circadian rhythm (with greater seizure frequency upon awakening), and EEG findings of generalised 3-6-Hz spike-and-wave discharge of short duration (1-3 seconds, vs 8-30 seconds in JAE). Furthermore, these readings are not always accompanied by clinical signs, which are almost always present in JAE. JAE is distinguished from Jeavons syndrome by the fact that the latter is a form of reflex epilepsy characterised by palpebral myoclonus, which may or may not be associated with absence seizure. As a general rule, this is induced by eye closure; patients are also highly sensitive to light, which can be a trigger factor. EEG studies show generalised 3-6-Hz spike-and-wave discharges.

## Funding

The authors have received no private or public funding.

## References

1. Gelisse P, Wolf P, Inoue Y. Juvenile absence epilepsy. In: Boreau M, Genton P, Dravet C, Delgado-Escueta A, Tassinari P, Thomas P <ET AL>, editors. *Epileptic syndromes in infancy, childhood and adolescence*. 5th ed. Montrouge: John Libbey Eurotext Ltd.; 2012. p. 329–39.

2. Kim D, Song I, Keum S, Lee T, Jeong MJ, Kim SS <ET-AL>. Lack of the burst firing of thalamocortical relay neurons and resistance to absence seizures in mice lacking alpha(1G) T-type Ca(2+) channels. *Neuron*. 2001;31:35–45.
3. Rosenfeld WE, Benbadis S, Edrich P, Tassinari CA, Hirsch E. Levetiracetam as add-on therapy for idiopathic generalized epilepsy syndromes with onset during adolescence: analysis of two randomized, double-blind, placebo-controlled studies. *Epilepsy Res*. 2009;85:72–80.
4. Blumenfeld H, Klein JP, Schridde U, Vestal M, Rice T, Khera DS, et al. Early treatment suppresses the development of spike-wave epilepsy in a rat model. *Epilepsia*. 2008;49:400–9.
5. Suzuki S, Kawakami K, Nishimura S, Watanabe Y, Yagi K, Seino M <ET-AL>. Zonisamide blocks T-type calcium channel in cultured neurons of rat cerebral cortex. *Epilepsy Res*. 1992;12:21–7.
6. Hoy SM. Zonisamide: a review of its use in the management of adults with partial seizures. *Drugs*. 2013;73:1321–38.
7. Wilfong A, Schultz R. Zonisamide for absence seizures. *Epilepsy Res*. 2005;64:31–4.
8. Hurst R, Chiota-McCollum N, Tatum W. Adult absence semiology misinterpreted as mesial temporal lobe epilepsy. *Epileptic Disord*. 2014;16:471–6.

J.L. Camacho Velásquez\*, E. Rivero Sanz, A.A. Sanabria Sanchinel, S. Santos Lasaosa, J.A. Mauri Llerda

*Servicio de Neurología, Hospital Clínico Universitario Lozano Blesa, Zaragoza, Spain*

\* Corresponding author.

E-mail address: [jlcv2002@hotmail.com](mailto:jlcv2002@hotmail.com)

(J.L. Camacho Velásquez).

2173-5808/

© 2016 Sociedad Española de Neurología. Published by Elsevier España, S.L.U. This is an open access article under the CC BY-NC-ND license (<http://creativecommons.org/licenses/by-nc-nd/4.0/>).

## Thymic cyst associated with myasthenia gravis<sup>☆</sup>



### Quiste tímico asociado a miastenia gravis

Dear Editor,

Thymic cysts account for 1%–5% of anterior mediastinal masses,<sup>1</sup> and may be congenital or acquired. Acquired thymic cysts have been associated with such systemic diseases as lupus erythematosus, Sjögren syndrome, rheumatoid arthritis, Hashimoto thyroiditis, HIV infection, and in very rare cases, with myasthenia gravis (MG).<sup>2</sup>

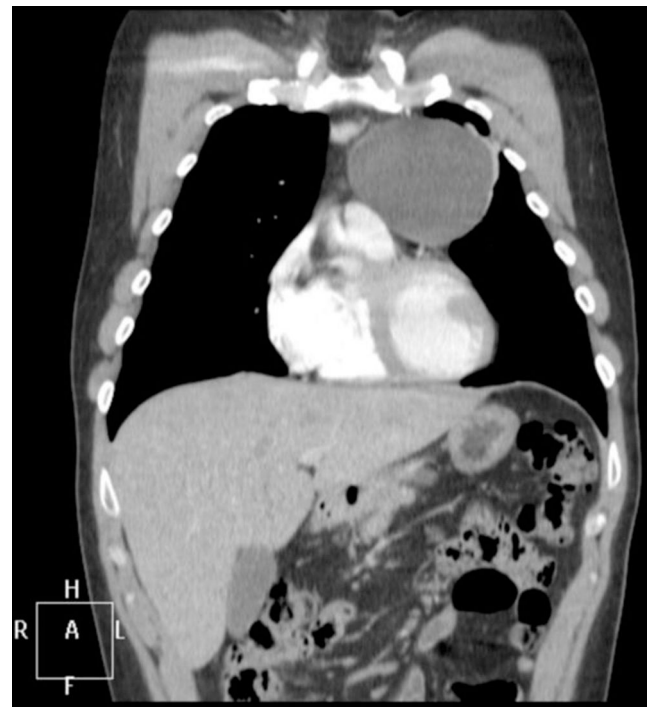We present an extremely rare case of MG associated with thymic cyst.

The patient was a 34-year-old former smoker with no history of disease. He attended our department due to a 2-month history of fatigue of the facial muscles, with no additional symptoms. The physical examination revealed mild left ptosis, which did not increase with maintained vertical gaze, as well as weakness of the tongue and the left orbicularis oculi and oris muscles.

We made a diagnosis of MG; this was confirmed by the results of an anti-acetylcholine receptor (anti-AChR) antibody analysis (22.1 nmol/L) and a single-fibre EMG in the left orbicularis oculi muscle (semi-pathological jitter; 47% blocking). These findings are compatible with a postsynaptic alteration in neuromuscular transmission. A mediastinal computerised tomography (CT) scan revealed a cystic lesion in the prevascular space, measuring 78 × 79 × 77 mm, with well defined contours and thin walls, of liquid density, showing no contrast uptake and no evidence of lymph node involvement (Fig. 1).

The mediastinal lesion was surgically resected 4 months after diagnosis. The anatomical pathology study identified it as a unilocular thymic cyst with follicular hyperplasia. A cytology study of the pleural fluid was negative for malignant cells, suggesting a cyst of lymphoid content.

Following diagnosis, the patient was started on treatment with pyridostigmine dosed at 60 mg every 8 hours. This partially improved the ptosis and the strength of the orbicularis oris muscle. One month later, the patient started a slow tapering course of prednisone, beginning at a weight-adjusted dose of 80 mg/48 hours. In the second month



**Figure 1** Chest CT scan. The mass in the anterior mediastinum is compatible with thymic cyst.

<sup>☆</sup> Please cite this article as: Morollón N, Guerrero P, Duarte J. Quiste tímico asociado a miastenia gravis. *Neurología*. 2018;33:405–407.