

A. Martínez-Saniger*, D. López-Herrera-Rodríguez,
R. Guerrero-Domínguez, F. Sánchez-Carrillo

*Servicio de Anestesiología y Reanimación, Hospital
Universitario Virgen del Rocío, Sevilla, Spain*

*Corresponding author.

E-mail address: ana.martinezsa@gmail.com

(A. Martínez-Saniger).

Binocular vertical diplopia following chemical labyrinthectomy with gentamicin: A case report and review of literature[☆]



Diplopía vertical binocular tras laberintectomía química con gentamicina. A propósito de un caso y revisión de la literatura

Dear Editor:

Chemical labyrinthectomy with gentamicin (CLG) is a minimally-invasive outpatient procedure aiming to achieve high concentrations of the drug in the cochlea with very little systemic dissemination. It is a useful treatment alternative in those patients with Meniere disease (MD) who do not respond to conventional medical treatment. Although vestibular toxicity secondary to CLG is a known adverse effect, visual alterations are rare; there are only 3 published cases of binocular vertical diplopia (BVD) with skew deviation (SD) due to this treatment. We present the fourth case of this complication, a patient with MD who developed BVD after undergoing an initial session of CLG.

Our patient was a 79-year-old woman with a 2-year history of drug-resistant MD in the left ear. She had received an intratympanic gentamicin injection one week previously (30 mg/mL; 0.5 mL). Before receiving the second dose, she reported a 5-day history of gradually progressing symptoms of BVD. In view of the patient's symptoms, her otorhinolaryngologist ordered an urgent neuro-ophthalmologic assessment. The study of extraocular movements revealed right hypertropia with 3 prism dioptres in all eye positions (Fig. 1). All other tests (visual acuity, pupillary light reflex, confrontation visual field exam, saccades and smooth pursuit eye movements, Bielschowsky head-tilting test, Ishihara test, and fundus observation with slit-lamp) yielded normal results. The patient was taking her usual medication, and her vital signs, cognitive state, and clinical examination results were all normal. Despite the above, she was admitted to the neurology department due to possible CNS involvement. Analyses and a brain MRI study did not reveal any relevant results. She was finally discharged and instructed to continue with the treatment she had received during her hospital stay: alternating an eye patch every day and using

prisms. After 8 weeks of follow-up by the neurology and ophthalmology departments, BVD disappeared, confirming the diagnosis of SD due to CLG.

Binocular visual diplopia is a medical emergency that requires immediate neuro-ophthalmologic assessment. SD is considered one of the most frequent causes of BVD (Table 1) as well as the semiological manifestation of damage at the level of the cerebellum or brainstem. However, this clinical manifestation may also be observed in the immediate and late postoperative periods following surgery for unilateral peripheral vestibular disorders.^{1–5} In addition, MD is a chronic disorder of the inner ear that manifests with vertigo, tinnitus, ear fullness, and fluctuating hypacusia. Today, CLG has replaced other invasive treatment options for MD. This treatment destroys the glycoalyx and stops endolymph production.^{4–8} Although numerous studies on CLG have been conducted, there is no consensus on dosing schedules. Weekly dosing plus follow-up hearing tests is an increasingly common approach. Although relatively safe, CLG is also associated with a number of complications,

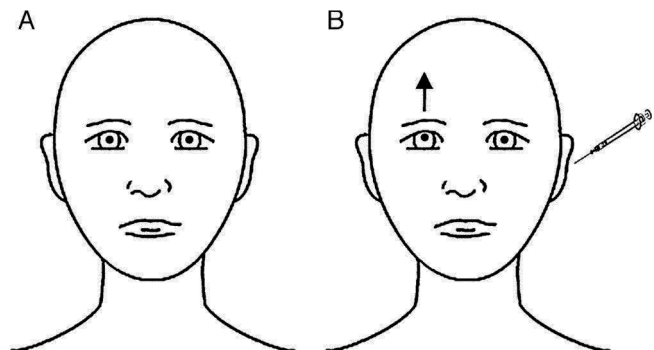


Figure 1 Ocular findings in our patient with her eyes in the primary position, before (A) and immediately after (B) intratympanic gentamicin injection. At baseline, eyes were in their neutral position. After CLG, the patient experienced upward deviation of the visual axis of the right eye, whereas the left eye remained unaltered; called hypertropia, this misalignment of the eyes is present in SD and eventually leads to BVD. Skew deviation is usually caused by supranuclear alterations in the brainstem or the cerebellum. It affects vertical vestibulo-ocular tracts or, at times, the vestibular nerve or vestibular terminal organ (organ of Corti). SD is usually comitant; when incomitant, it may mimic partial paralysis of the third or fourth cranial nerves. The cause is usually vascular ischaemia in the pons or the lateral medulla oblongata (Wallenberg syndrome), probably due to involvement of the vestibular nuclei or their projections. When damage is located in the inferior area of the pons (as in our patient), the ipsilateral eye is undermost (ipsiversive SD), whereas in the case of rostral lesions at the level of the pons, the undermost eye is the contralateral eye (contraversive SD).^{1–3}

[☆] Please cite this article as: León Ruiz M, Izquierdo Esteban L, Parra Santiago A, Benito-León J, Nieto Altuzarra AE, García-Albea Ristol E. Diplopia vertical binocular tras laberintectomía química con gentamicina. A propósito de un caso y revisión de la literatura. *Neurología*. 2016;31:503–505.

Table 1 Causes of binocular vertical diplopia.

<i>Common causes</i>
Superior oblique palsy
Dysthyroid orbitopathy (muscle infiltration)
Myasthenia gravis
Skew deviation (brainstem, cerebellar, hydrocephalus)
<i>Less common causes</i>
Orbital inflammation (myositis, idiopathic orbital inflammatory syndrome [formerly known as 'orbital pseudotumour'])
Orbital infiltration (lymphoma, metastases, amyloid)
Primary orbital tumour
Entrapment of the inferior rectus (blowout fracture)
Third nerve palsy
Superior division third nerve palsy
Atypical third nerve palsy (partial nuclear lesion)
Aberrant third nerve reinnervation
Brown syndrome (congenital, acquired)
Congenital extraocular muscle fibrosis or muscle absence
Double elevator palsy (monocular elevator deficiency); controversial in origin
<i>Other causes</i>
Chronic progressive external ophthalmoplegia
Miller Fisher syndrome
Botulism
Monocular supranuclear gaze palsy
Vertical nystagmus (oscillopsia)
Stiff person syndrome (associated with hypometric saccades and abduction deficits)
Superior oblique myokymia
Dissociated vertical deviation (divergence)
Wernicke encephalopathy
Vertical one-and-a-half syndrome

Source: Daroff et al.,² 2012.

including instability, exacerbation of vertigo, and worsening of hearing impairment. There are also several published cases of ataxia accompanied by oscillopsia, which may be due to the CNS being unable to compensate fully for vestibular suppression secondary to CLG.^{4–9} SD, on the other hand, is a vertical misalignment of the eyes due to damage to prenuclear vestibular inputs to the ocular motor nuclei. The most recent hypotheses suggest that SD linked to CLG is caused by asymmetrical, unilateral damage to the utricle at the level of neural integration for vertical eye movements in the midbrain (those involving oculomotor neurons and the interstitial nucleus of Cajal).^{5,8,9} Delayed onset of SD after CLG is due to the pharmacodynamic properties of intracochlear gentamicin. After gentamicin is injected into the middle ear, the drug concentration in the inner ear peaks in about the first 16 hours and gradually decreases during the following 16 to 24 hours. Toxicity affecting vestibular ciliated cells is likely to accumulate during a similar period of time, and SD occurs when vestibular denervation reaches a critical level.^{6–8} Fortunately, this condition usually resolves within 6 to 8 weeks.⁸ Lastly, the recently developed video Head Impulse Test (vHIT) is a valuable complementary tool for identifying vestibular deficits and preventing iatrogenic

effects.^{10,11} In conclusion, development of BVD secondary to CLG has previously been reported in 2 articles published in otorhinolaryngology journals,^{8,9} but never in a neurological journal. This entity is probably underdiagnosed. Our case shows that CLG may cause reversible BVD. This statement is supported by the Naranjo algorithm for adverse drug reactions: our patient scored 7 out of 13 points, which suggests that CLG was the most likely cause of BVD.¹² Clinicians should therefore be on the lookout for this rare adverse drug reaction; it may resemble CNS damage and treating it requires an interdisciplinary approach. It is still to be determined if CLG has a more extensive biochemical effect on the CNS. Prospective studies describing more cases should be conducted for a better understanding of this entity.

Conflicts of interest

The authors have no conflicts of interest to declare.

Acknowledgements

We would like to thank Drs. Victoria Galán Sánchez-Seco, José Tejeiro Martínez, Francisco Cabrera Valdivia, María Molina Sánchez, and María Henedina Torregrosa Martínez.

References

- Palla A, Straumann D. Neurological evaluation of acute vertical diplopia. *Schweiz Arch Neurol Psychiatr.* 2002;153:180–4.
- Lavin PJ. Neuro-ophthalmology: ocular motor system. In: Daroff RB, Fenichel GM, Jankovic J, Mazziotta JC, editors. *Bradley's neurology in clinical practice*, vol. 1, 6th ed. Philadelphia: Elsevier Saunders; 2012. p. 589–633.
- Wong AM. Understanding skew deviation and a new clinical test to differentiate it from trochlear nerve palsy. *J AAPOS.* 2010;14:61–7.
- Schmerber S, Dumas G, Morel N, Chahine K, Karkas A. Vestibular neurectomy vs. chemical labyrinthectomy in the treatment of disabling Menière's disease: a long-term comparative study. *Auris Nasus Larynx.* 2009;36:400–5.
- Cosetti MK, Tawfik K, Fouladvand M, Roland JT Jr, Lalwani AK. Diplopia due to skew deviation following neurotologic procedures. *Otol Neurotol.* 2012;33:840–2.
- Salt AN, Gill RM, Plontke SK. Dependence of hearing changes on the dose of intratympanically applied gentamicin: a meta-analysis using mathematical simulations of clinical drug delivery protocols. *Laryngoscope.* 2008;118:1793–800.
- Herraiz C, Miguel Aparicio J, Plaza G. Intratympanic drug delivery for the treatment of inner ear diseases. *Acta Otorrinolaringol Esp.* 2010;61:225–32.
- Ng D, Fouladvand M, Lalwani AK. Skew deviation after intratympanic gentamicin therapy. *Laryngoscope.* 2011;121:492–4.
- Santos-Gorjón P, Collazo-Lorduy T, Sánchez-Terradillos E, Sánchez-Jara Sánchez JL, Velasco-García MJ, Martín-Hernández G. Acute diplopia posterior to chemical labyrinthectomy. *Rev Soc Otorrinolaringol Castilla León Cantab La Rioja.* 2012;3:83–94. Available at: <http://dialnet.unirioja.es/servlet/articulo?codigo=3883826> [accessed 13.09.14].
- MacDougall HG, Weber KP, McGarvie LA, Halmagyi GM, Curthoys IS. The video head impulse test: diagnostic accuracy in peripheral vestibulopathy. *Neurology.* 2009;73:1134–41.

11. Walther LE, Huelse R, Blättner K, Bloching MB, Blödown A. Dynamic change of VOR and otolith function in intratympanic gentamicin treatment for ménière's disease: case report and review of the literature. *Case Rep Otolaryngol.* 2013;2013:168391, <http://dx.doi.org/10.1155/2013/168391>.
12. Doherty MJ. Algorithms for assessing the probability of an adverse drug reaction. *Respir Med CME.* 2009;2:63–7.

M. León Ruiz^{a,*}, L. Izquierdo Esteban^a, A. Parra Santiago^a, J. Benito-León^{b,c,d}, A.E. Nieto Altuzarra^{e,f}, E. García-Albea Ristol^{a,g}

^a Servicio de Neurología, Hospital Universitario Príncipe de Asturias, Alcalá de Henares, Madrid, Spain

^b Servicio de Neurología, Hospital Universitario 12 de Octubre, Madrid, Spain

^c Departamento de Medicina, Facultad de Medicina, Universidad Complutense de Madrid, Madrid, Spain

^d Centro de Investigación Biomédica en Red sobre Enfermedades Neurodegenerativas (CIBERNED), Spain

^e Departamento de Otorrinolaringología, Hospital Universitario Príncipe de Asturias, Alcalá de Henares, Madrid, Spain

^f Departamento de Cirugía, Ciencias Médicas y Sociales, Facultad de Medicina, Universidad de Alcalá, Alcalá de Henares, Madrid, Spain

^g Departamento de Medicina, Facultad de Medicina, Universidad de Alcalá, Alcalá de Henares, Madrid, Spain

* Corresponding author.

E-mail address: pistolpete271285@hotmail.com (M. León Ruiz).

Transcranial puncture using Onyx for endovascular embolisation of dural arteriovenous fistula[☆]



Punción transcraneal arterial microselectiva e inyección de Onyx para el cierre endovascular de fístula arteriovenosa dural

Dear Editor:

Dural arteriovenous fistulas (AVF) account for 10% to 15% of all intracranial vascular malformations.^{1,2} The overall annual risk of bleeding is approximately 1.5%.³ According to the Cognard classification,^{4–6} dural AVFs associated with leptomeningeal venous drainage or venous ectasia are considered to pose a high risk of haemorrhage.

Malignant dural AVFs, which are associated with cortical venous reflux, usually have an aggressive presentation, with a 35% risk of rebleeding within the first 2 weeks after the haemorrhage.⁷

Dural AVFs can be treated with surgery (endovascular treatment) or radiotherapy, the former being the treatment of choice in most cases.^{8,9} The direct transcranial approach through the parietal and mastoid foramina was developed by Houdart et al.¹⁰ Other authors¹¹ have also described different surgical routes, including the dural sinus after craniectomy, the superior ophthalmic vein prior to surgical exposure, the cavernous sinus via the foramen rotundum, and the extracranial segment of the occipital arteries.

We present the case of a 56-year-old man with grade IV dural AVF according to the Cognard classification who displayed subarachnoid haemorrhage secondary to a ruptured flow-related aneurysm in the ascending artery (Fig. 1). The

fistula, located near the tentorium, was supplied by both occipital arteries, the meningeal branches of the vertebral arteries, and the meningeal branches of the right internal carotid artery and the left superior cerebellar artery (the location of the aneurysm undergoing endovascular repair). The arteriovenous shunt was located medial to the attachment of the falx to the tentorium. We found large-calibre veins with retrograde flow draining to the straight sinus and signs of bilateral cortical reflux draining to the superior sagittal sinus.

In view of the technical difficulties of performing distal catheterisation (marked elongation of the arteries ascending to the fistula and the tortuosity of the vein), we decided to perform a transcranial puncture of the right occipital artery through the parietal foramen (Fig. 2). After general anaesthesia was administered, the patient was placed in a prone position and the puncture was guided radiographically and angiographically. With an 18-gauge needle guided by direct fluoroscopy, a Marathon microcatheter (Covidien) was advanced to the arteriovenous shunt. After microcatheterisation we injected Onyx,^{8,12} which achieved complete occlusion of the AVF. The procedure was performed without incidents; at discharge, the patient remained asymptomatic.

In line with other studies,^{11,13} our case supports the hypothesis that the transcranial route is safe and effective when endovascular access is not viable due to blood vessel tortuosity.

In our view, a transcranial approach reduces treatment risks; in fact, it avoids the need for craniectomy. It also lowers the duration of the procedure and makes it easier to advance the microcatheter to reach the shunt location, which permits greater control over the injected liquid embolic agent.^{8,14} A possible complication specific to transcranial access is the formation of epidural or epicranial haematomas. The risk can be reduced by conducting a previous CT study of the foramen and performing the puncture using a map delivered by a catheter placed in the carotid.

In conclusion, transcranial puncture for the treatment of dural AVFs may be considered an effective endovascular technique when arterial or venous access is impossible or extremely complex.

[☆] Please cite this article as: Gonzalo N, Navia P, Larrea JA, Massó J. Punción transcraneal arterial microselectiva e inyección de Onyx para el cierre endovascular de fístula arteriovenosa dural. *Neurología.* 2016;31:505–507.