

LETTERS TO THE EDITOR

Fulminant stunned myocardium following endoscopic ventriculostomy in a patient with chronic hydrocephalus^{☆,☆☆}

Síndrome de corazón contundido fulminante tras ventriculostomía endoscópica en una paciente con hidrocefalia crónica

Dear Editor:

Neurogenic stunned myocardium (NSM) is a clinical-pathological entity that presents with myocardial injury and dysfunction occurring after diverse types of acute brain injury; it results from imbalance of the autonomic nervous system¹ which is typically secondary to subarachnoid haemorrhage. However, NSM may also be related to other central nervous system disorders associated with brain injuries, such as ischaemic strokes, trauma, hydrocephalus, and epileptic seizures. Several theories attempt to explain the pathophysiological mechanism of NSM, but the most widely accepted theory implicates a flood of catecholamines released by the central nervous system. These catecholamines cause systemic myocardial injury, which is characterised by pathological findings of contraction band necrosis with normal coronary perfusion.^{2–5} Electrocardiogram shows QT prolongation, deep symmetrical T-wave inversions, and ST slurring. It also displays a depressed ejection fraction of less than 40%.⁶

We present the case of a patient with chronic hydrocephalus due to idiopathic stenosis of the aqueduct of Sylvius, with onset of NSM after an endoscopic third ventriculostomy.

Our patient is a 35-year-old woman admitted to the neurosurgery department for scheduled surgical treatment of chronic hydrocephalus secondary to idiopathic stenosis of the aqueduct of Sylvius. In the preceding 10 months, she had experienced increased frontal headache and fluctuating memory changes. Findings from the neurological exam were

limited to slightly diminished visual acuity. Magnetic resonance imaging (MRI) showed triventricular hydrocephalus (Fig. 1A–C). Presurgical cardiological evaluation revealed no cardiac changes (Fig. 2A and B). Presurgical blood pressure was 126/84 mmHg. With the patient's informed consent, we proceeded to perform an endoscopic third ventriculostomy and found no elevated intracranial pressure. The external ventricular drain was placed on the right lateral ventricle. Nine hours after the surgery, while the patient's status was good, she began to develop symptoms of sudden-onset headache and progressive decrease in level of consciousness, with subsequent decerebrate rigidity, right-sided mydriasis, intracranial hypertension, altered heart rate, and arterial hypotension. The patient was intubated and transferred in coma to the intensive care unit. A transthoracic echocardiogram showed dilated left ventricle with akinesia of the lower interventricular septum, lateral and posterior hypokinesia, and an ejection fraction of 38%. Electrocardiogram revealed widened QRS complex, inverted T wave, and ST segment elevation (Fig. 2C and D). Levels of cardiac enzymes were high. Initial brain computed tomography revealed diffuse subarachnoid haemorrhage (Fig. 3). Three days after onset of coma, we performed an electroencephalogram that showed no brain activity. Our patient died 5 days later due to acute heart failure. We were unable to perform an autopsy because the patient's family did not give consent.

NSM is usually secondary to acute neurological damage that activates the sympathetic nervous system, causing a catecholaminergic storm. In fact, previous studies have established an association between subarachnoid haemorrhage and hypothalamic disturbances as precipitants of cardiac hyperexcitability and secondary myocardial damage.^{7,8} These entities have also been causally linked to other brain injuries such as head trauma, acute hydrocephalus, etc.^{7,9}

In our case, the patient displayed heart symptoms a few hours after the endoscopic third ventriculostomy and external ventricular drain placement were performed. On this basis, we might conclude that stunned myocardium could have been secondary to hypothalamic stimulation during surgery. Another possible explanation might be subarachnoid haemorrhage after the intervention. Diffuse cerebral oedema could also have been due to a significant decrease in brain perfusion during the period in which ejection fraction was below 40%.^{7,10,11} Pulmonary oedema, also called neurogenic pulmonary oedema, is a widely studied entity.¹² It is believed to be secondary to sympathetic

[☆] Please cite this article as: Piña Batista KM, Gutiérrez Morales JC, Astudillo A, Alvarez de Eulate-Beramendi S. Síndrome de corazón contundido fulminante tras ventriculostomía endoscópica en una paciente con hidrocefalia crónica. *Neurología*. 2015;30:181–183.

^{☆☆} This study was presented in poster format at the 18th Congress of the Spanish Society of Neurosurgery, 14–17 May 2013.

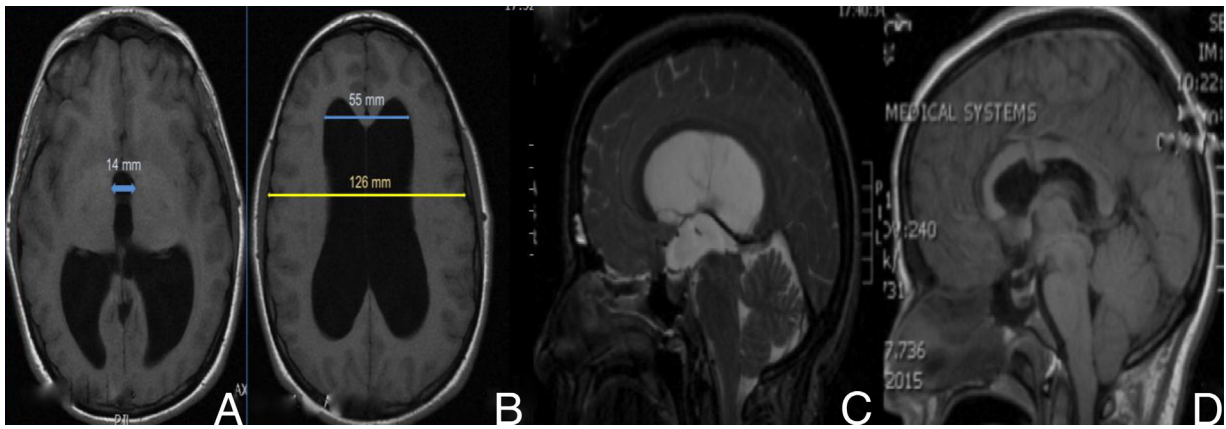


Figure 1 Presurgical imaging studies (A and B): T1-weighted brain MRI without contrast that revealed triventricular hydrocephalus. Evans index was 0.43 (B) and third ventricle diameter was > 1.4 cm (A). Presurgical study (C): T2-weighted MRI showing increased convexity of the corpus callosum, flattening of the midbrain, and stenosis of the aqueduct of Sylvius. Postsurgical studies (D): T1-weighted MRI without contrast that revealed decreased ventricular size, upward displacement of midbrain, and the endoscope path for the third ventriculostomy.

hyperactivity, although this condition is not always present in stunned myocardium.

Although intraventricular hydrocephalus due to stenosis of the aqueduct of Sylvius generally manifests in childhood, its first clinical signs may not appear until adulthood in some cases. The precise pathophysiological mechanism

explaining delayed manifestation is still unknown. However, idiopathic stenosis of the aqueduct of Sylvius could be due to a congenital anomaly in the development of the aqueduct of Sylvius, or to aqueductal gliosis. Several cases of chronic hydrocephalus due to idiopathic stenosis of the aqueduct of Sylvius in adults have been described in the literature.^{13,14}

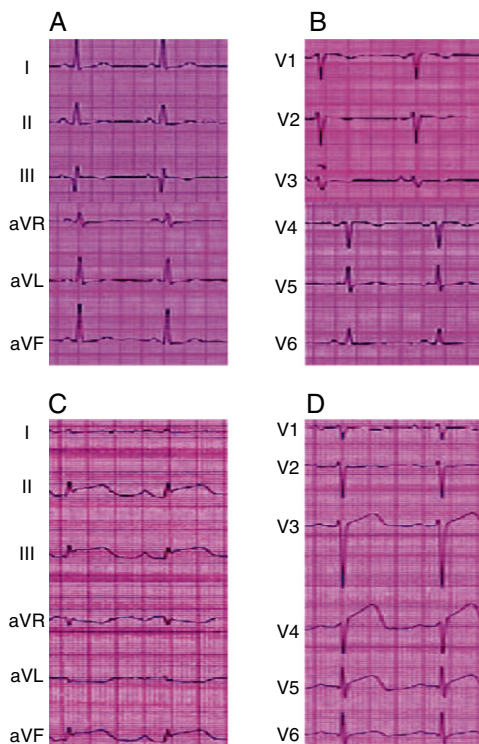


Figure 2 (A and B) Presurgical electrocardiogram showed no changes. (C and D) The electrocardiogram performed after the endoscopic third ventriculostomy revealed changes indicative of stunned myocardium (ST segment elevation and inverted T wave).

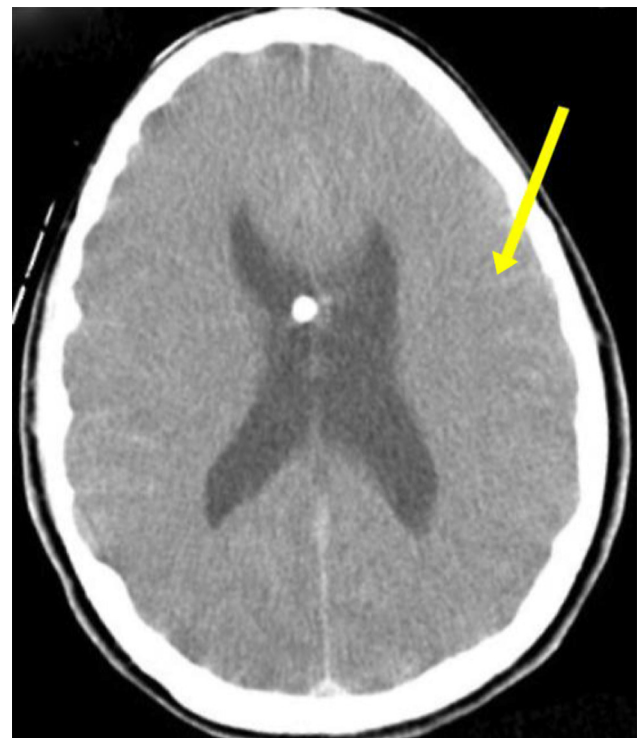

Figure 3 Cranial computed tomography after the endoscopic third ventriculostomy that revealed subarachnoid haemorrhage on the cortical convexity sulci (arrow).

The most common symptom is headache, but that symptom is not necessarily progressive. Treatment of choice for hydrocephalus due to aqueductal stenosis is usually endoscopic third ventriculostomy, in both children and adults.¹³

Cases described in the literature do not normally present fulminant progression. In fact, cardiac enzyme levels generally improve in a period of several hours to a few days, after which patients recover. We cannot explain why our patient displayed non-reactive right-sided mydriasis and decerebrate rigidity as initial signs.

References

1. Nguyen H, Zaroff J. Neurogenic stunned myocardium. *Curr Neurol Neurosci Rep.* 2009;9:486–91.
2. Jennifer EF, Wijdicks EF, Kumar G, Rabinstein AA. One thing leads to another: GBS complicated by PRES and Takotsubo cardiomyopathy. *Neurocrit Care.* 2009;11:395–7.
3. Temes RE, Tessitore E, Schmidt JM, Naidech AM, Fernandez A, Ostapovich ND, et al. Left ventricular dysfunction and cerebral infarction from vasospasm after subarachnoid hemorrhage. *Neurocrit Care.* 2010;13:359–65.
4. Lee VH, Oh JK, Mulvagh SL, Wijdicks EF. Mechanism in neurogenic stress cardiomyopathy after aneurysmal subarachnoid hemorrhage. *Neurocrit Care.* 2006;24:3–249.
5. Brevis Nuñez F, Tschiedel E, Felderhoff-Mueser U, Neudorf U, Chapot R, Dohna-Schwake C. Neurogenic stunned myocardium after embolization in two children with vein of Galen aneurysmal malformation. *Neuroradiology.* 2013;55:213–6.
6. Mayer SA, Lin J, Homma S, Solomon RA, Lennihan L, Sherman D, et al. Myocardial injury and left ventricular performance after subarachnoid hemorrhage. *Stroke.* 1999;30:780–6.
7. Jeremiah J, Ragheb J, Garg R, Patten W, Sandberg D, Bhatia S. Neurogenic stunned myocardium after acute hydrocephalus: report of 2 cases. *J Neurosurg Pediatr.* 2010;5:428–33.
8. Loewy AD, Araujo JC, Kerr FW. Pupillodilator pathways in the brain stem of the cat: anatomical and electrophysiological identification of a central autonomic pathway. *Brain Res.* 1973;60:65–91.
9. Jarquin-Valdivia AA, Rich AT, Yarbrough JL, Thompson RC. Intraventricular colloid cyst, hydrocephalus and neurogenic stunned myocardium. *Clin Neurol Neurosurg.* 2005;107:361–5.
10. Chen MA. Transient stress cardiomyopathies in the elderly: clinical and pathophysiological considerations. *J Geriatr Cardiol.* 2012;9:38–48.
11. Prieto-Arribas R, Pascual-Garvi JM, Gonzalez-Llanos F, Roda JM. ¿Cómo reparar el daño cerebral isquémico? Utilidad de los modelos experimentales en la búsqueda de respuestas. *Neurología.* 2011;26:65–73.
12. Simon RP, Bayne LL. Pulmonary lymphatic flow alterations during intracranial hypertension in sheep. *Ann Neurol.* 1984;15:188–94.
13. Edwards RJ, Britz GW, Marsh H. Chronic headaches due to occult hydrocephalus. *J R Soc Med.* 2003;96:77–8.
14. Oi S, Shimoda M, Shibata M, Honda Y, Togo K, Shinoda M, et al. Pathophysiology of long-standing overt ventriculomegaly in adults. *J Neurosurg.* 2000;92:933–40.

K.M. Piña Batista*, J.C. Gutiérrez Morales, A. Astudillo, S. Alvarez de Eulate-Beramendi

Servicio de Neurocirugía, Hospital Universitario Central de Asturias, Oviedo, Asturias, Spain

*Corresponding author.

E-mail addresses: pineappledr@gmail.com, pineappledr@hotmail.com (K.M. Piña Batista).

Characteristics of informal caregivers of patients with dementia in Alicante province[☆]

Red de cuidadores informales de los pacientes con demencia en la provincia de Alicante, descripción de sus características

Dear Editor:

We have read with great interest “Characteristics of informal caregivers of patients with dementia in Alicante province” by Toribio-Díaz et al.¹ We believe that this study constitutes a relevant contribution to the literature on informal care for dementia patients for 2 main reasons: firstly, it introduces the concept of the ‘absent caregiver’ and

develops the concept of ‘supporting caregiver’; and secondly, it analyses the tasks performed by caregivers and addresses the reasons why primary caregivers take responsibility for these care tasks. However, we feel that the authors have not mentioned some of the topics mentioned in other studies conducted by Spanish researchers and published in international journals. Our letter aims to address those omitted topics in order to enrich the discussion of informal care for dementia patients, thereby complementing, if possible, the outstanding article by Toribio-Díaz et al.

Rotation (moving a patient between different relatives’ households) is a care strategy used for many dependent elderly patients, but it is more common in patients with dementia. Very few studies have examined this strategy since it is almost exclusive to Mediterranean countries. While the authors mention this method, they do not provide further details or cite the only article in the literature offering an in-depth analysis of rotation.² We recommend that they read the study indicated above, which includes very useful information on informal care. On the other hand, the authors state that they have found no previous studies on dementia showing that primary caregivers reduce their working hours in order to care for patients. Our research group has published several studies on informal care for dementia patients^{2–6} that document this reduction in working hours with quantitative data. We invite Toribio-Díaz

DOI of refers to article: <http://dx.doi.org/10.1016/j.nrleng.2012.03.012>

[☆] Please cite this article as: Rivera-Navarro J, Benito-León J. Red de cuidadores informales de los pacientes con demencia en la provincia de Alicante, descripción de sus características. *Neurología.* 2015;30:183–184.