

5. Sarma S, Sekhar LN, Schessel DA. Nonvestibular schwannomas of the brain: a 7-year experience. *Neurosurgery*. 2002;50:437–48.
6. Myssiorek D. Head and neck paragangliomas: an overview. *Otolaryngol Clin North Am*. 2001;34:829–36.
7. Mabanta SR, Buatti JM, Friedman WA, Meeks SL, Mendenhall WM, Bova FJ. Linear accelerator radiosurgery for nonacoustic schwannomas. *Int J Radiat Oncol Biol Phys*. 1999;43:545–8.
8. Jordan JA, Roland PS, McManus C, Weiner RL, Giller CA. Stereotactic radiosurgery for glomus jugulare tumors. *Laryngoscope*. 2000;110:35–8.
9. Jiménez-Caballero PE, Marsal-Alonso C, Méndez-Cendón JC, Alvarez-Tejerina A. Síndrome de Collet–Sicard secundario a tumor gómico: valoración mediante resonancia magnética. *Rev Neurol*. 2004;39:1072–3.
10. Paparounas K, Gotsi A, Apostolou F, Akritidis N. Collet–Sicard syndrome disclosing glomus tumor of the skull base. *Eur Neurol*. 2003;49:103–5.
11. Garcia-Escrivà A, Pampliega Pérez A, Martín-Estefanía C, Botella C. Schwannoma of the hypoglossal nerve presenting as a syndrome of Collet–Sicard. *Neurología*. 2005;20:311–3.

R. Gutiérrez Ríos\*, A. Castrillo Sanz, C. Gil Polo, M.I. Zamora García, N. Morollón Sánchez-Mateos, A. Mendoza Rodríguez

*Sección de Neurología, Complejo Asistencial de Segovia, Segovia, Spain*

\* Corresponding author.

*E-mail address: gutiriosra@yahoo.es (R. Gutiérrez Ríos).*

## Terson syndrome and ocular ultrasound<sup>☆</sup>

### Síndrome de Terson y ecografía orbitaria

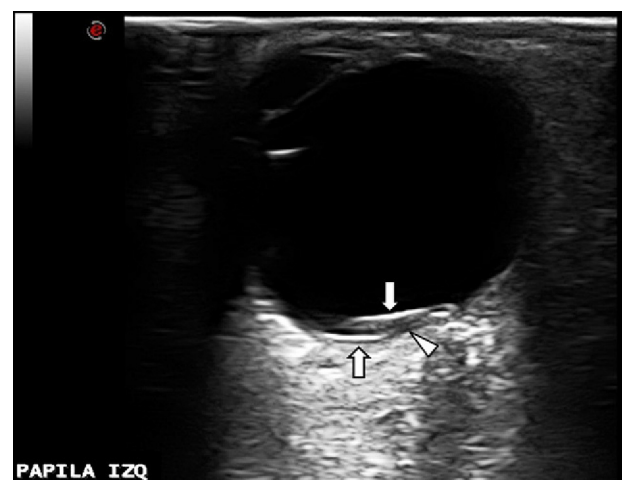
*Dear Editor:*

We have read with interest the article by Sánchez Ferreiro et al.<sup>1</sup> regarding Terson syndrome (TS) and its potentially important role as a prognostic marker for subarachnoid haemorrhage (SAH). However, we cannot agree with all the points highlighted by the authors. Visible haemorrhages in the fundus of the eye are not a rare occurrence in SAH patients, and while haemorrhages have been suggested as indicators of poor prognosis, not all authors accept this premise.<sup>2</sup> Furthermore, the article by Sánchez Ferreiro et al. states that most SAH patients with associated TS present a low level of consciousness. However, our experience contrasts with this statement. As an example, we present the case of a 49-year-old man attended in our hospital on the same day we read the Letter to the Editor. The patient had suffered subarachnoid bleeding during the night while engaging in sexual intercourse. Presence of aneurysm of the anterior communicating artery was observed using CT angiography. His SAH was classified as Fisher grade 3 and Hunt & Hess grade II: stuporous condition was not observed in the patient at any time during the first days of bleeding, and there were no neurological signs except for intense headache and neck rigidity. Twenty-four hours after symptom onset, the patient underwent successful embolisation with platinum coils resulting in total aneurysm occlusion. Five days after embolisation, funduscopic examination revealed several subhyaloid and retinal haemorrhages (a larger one on the superior-nasal quadrant adjoining the optic disk) not affecting the macular area in the left eye. In the right eye, we observed macular and

peripapillary retinal haemorrhages. The ocular ultrasound performed that same day revealed the intraretinal origin of the largest haemorrhage, which was located on the superior nasal quadrant of the left eye. On the ultrasound image (Fig. 1), we can observe that the anechogenic area (corresponding to the bleeding and indicated by an arrowhead) divides the retinal lamina (hyperechogenic on the figure, indicated by 2 arrows).

Therefore, in our case, presence of TS in an SAH patient was not associated with stupor or coma, contrary to the rule suggested by Sánchez Ferreiro et al. In fact, we believe that TS in cases of SAH is sufficiently frequent (although underdiagnosed) that it can be clearly associated with any possible outcome.

Although TS as initially described referred only to vitreous haemorrhages in association with SAH, vitreous, subhyaloid, intraretinal, and subretinal haemorrhages are included in this term as it is currently understood.<sup>3</sup> However, TS pathophysiology remains unknown, as Sánchez Ferreiro et al. explain in their article. Presence of intraocular haemorrhages might be explained by the pressure exerted by the



**Figure 1** Intraretinal haemorrhage in a patient with SAH.

<sup>☆</sup> Please cite this article as: Monteagudo M, Doménech C, Segura T. Síndrome de Terson y ecografía orbitaria. *Neurología*. 2015;30:132–3.

haematoma on periocular structures, thus favouring the flow of blood through the optic nerve sheath across the subarachnoid space.<sup>4,5</sup> Another theory suggests that TS could be associated with increased intracranial pressure (ICP) secondary to SAH. Venous hypertension caused by ICP might cause rupture of retinal veins, thereby giving rise to ocular haematoma.<sup>6</sup> If this theory was right, poor prognosis in these patients would have more to do with ICP than with intraocular haemorrhage, and TS would be considered an epiphenomenon.

Lastly, we would like to highlight the utility of orbital Doppler sonography in TS diagnosis,<sup>6,7</sup> since this is a simple, fast, and noninvasive technique available to neurologists. This test not only enables diagnosis of TS but also can be used to identify the exact nature of the type of haemorrhage and any potential complications such as retinal detachment, which are therapeutically relevant points.<sup>6</sup>

## References

1. Sánchez Ferreiro AV, Muñoz Bellido L. Presentación atípica de un síndrome de Terson: a propósito de un caso. *Neurología*. 2012;27:380–1.
2. Liu GT, Volpe NJ, Galetta SL. Optic disc swelling: papilledemas and other causes. In: *Neuro-ophthalmology: diagnosis and management*. Philadelphia: WB Sanders Company; 2001. p. 202–3.
3. Sung W, Arnaldo B, Sergio C, Juliana S, Michel F. Terson's syndrome as a prognostic factor for mortality of spontaneous subarachnoid haemorrhage. *Acta Ophthalmol*. 2011;89:544–7.
4. Garfinkle AM, Danys IR, Nicolle DA, Colohan AR, Brem S. Terson's syndrome: a reversible cause of blindness following subarachnoid hemorrhage. *J Neurosurg*. 1992;76:766–71.
5. Pfausler B, Belcl R, Metzler R, Mohsenipour I, Schmutzhard E. Terson's syndrome in spontaneous subarachnoid hemorrhage: a prospective study in 60 consecutive patients. *J Neurosurg*. 1996;85:392–4.
6. Stienen MN, Lücke S, Gautschi OP, Harders A. Terson haemorrhage in patients suffering aneurysmal subarachnoid haemorrhage: a prospective analysis of 60 consecutive patients. *Clin Neurol Neurosurg*. 2012;114:535–8.
7. Rojo Aladro JA. Estudio ultrasonográfico de la órbita. In: Irimia P, Segura T, Serena J, Moltó JM, editors. *Neurosonología: aplicaciones diagnósticas para la práctica clínica*. España: Editorial Panamericana; 2011. p. 347–62.

M. Monteagudo<sup>a,\*</sup>, C. Doménech<sup>b</sup>, T. Segura<sup>a</sup>

<sup>a</sup> *Servicio de Neurología, Complejo Hospitalario Universitario de Albacete, Albacete, Spain*

<sup>b</sup> *Servicio de Neurología, Hospital General Universitario de Elche, Alicante, Spain*

\*Corresponding author.

E-mail address: [mariamonteagudo86@gmail.com](mailto:mariamonteagudo86@gmail.com) (M. Monteagudo).

## Reply to "Terson syndrome and ocular ultrasound"<sup>☆</sup>

### Respuesta a «Síndrome de Terson y ecografía orbitaria»

Dear Editor:

It was with great interest that we read 'Terson syndrome and ocular ultrasound', which appears to be a very interesting and instructive letter.

We agree with the authors that Terson syndrome is an underestimated and underdiagnosed disorder. Action protocols between departments should be created to ensure appropriate treatment and follow-up for these patients.

We also agree that ocular ultrasound is an important diagnostic tool in cases of retinal haemorrhage. However, the most important diagnostic tool in these cases is examination of the fundus with an ophthalmoscope, a simple and inexpensive technique that yields unambiguous results.

That being said, we adhere to the opinion expressed in the original article<sup>1</sup> regarding the severity of the haemorrhage and the presence of Terson syndrome.

In our hospital, we systematically examine the fundus of the eye of all the patients who present cerebral haemorrhage, according to a series of protocols established together with the ICU and the anaesthesiology departments, where patients are initially treated.

We have spent 2 years adding data to a database so as to establish whether there is a significant relationship between haemorrhage severity and presence of retinal haemorrhage in this patient group.

At this time, we can cautiously state that we have established a significant relationship between the severity of the patient's condition and presence of a haemorrhage in the fundus of the eye.

One of our preliminary conclusions is that haemorrhage was more severe when Terson syndrome was also present, in most of the patients we have studied.

Doctors may find atypical cases that do not follow this paradigm, as we mentioned in the original article. However, these cases make up a small minority and they are not significant.

In any case, additional articles confirm the relationship between haemorrhage severity and presence of retinal haemorrhage. For example, Frizell et al.<sup>2</sup> corroborated the results of earlier studies indicating that presence of Terson syndrome is related to subarachnoid haemorrhage severity. Pfausler et al.<sup>3</sup> observed high mortality rates (90%) among patients with this syndrome.

Subarachnoid haemorrhages are the most frequent cause of sudden death due to cerebrovascular accident and a

DOI of refers to article: <http://dx.doi.org/10.1016/j.nrleng.2014.12.004>.

<sup>☆</sup> Please cite this article as: Sánchez Ferreiro AV, Muñoz Bellido L. Respuesta a «Síndrome de Terson y ecografía orbitaria». *Neurología*. 2015;30:133–4.