



CASE STUDY

Naso-Oropharyngeal Choristoma (Hairy Polyps) in Adults: A New Case, and Review of the Literature^{☆,☆☆}



Coristomas naso-orofaríngeos (pólipos pilosos) en adultos: un nuevo caso y revisión de la literatura

Mainak Dutta,^{a,*} Soumya Ghatak,^b Soham Roy,^c Ramanuj Sinha^a

^a Department of Otorhinolaryngology and Head-Neck Surgery, Medical College and Hospital, Kolkata, 88, College Street, Kolkata 700073, West Bengal, India

^b Department of Otorhinolaryngology and Head-Neck Surgery, R. G. Kar Medical College and Hospital, Kolkata 700004, West Bengal, India

^c Department of Otorhinolaryngology-Head and Neck Surgery, Children's Memorial Hermann Hospital, University of Texas Medical School at Houston, Houston, TX, USA

Received 7 August 2014; accepted 9 September 2014

Clinical Case

A 42-year-old woman presented with progressive difficulty in swallowing, and snoring since 4 years, with right-sided nasal obstruction for 2 years. She had a persistent sense of obstruction behind her tongue; on examination, a large, smooth-walled globular mass was seen

occupying the oropharynx extending up to the tongue-base and vallecula (Fig. 1). It was firm, non-tender, did not bleed on touch, and was free on all sides except superiorly, clinically resembling a choanal polyp. On diagnostic naso-endoscopy, the pedunculated mass was seen attached to the right Eustachian tube orifice and the adjacent epipharyngeal surface of soft palate, hanging from nasopharynx into the oropharynx obstructing the aerodigestive tract. Computed tomography (CT)-scan was non-contributory; the paranasal sinuses were clear, with no breach in the bones and skull-base. The lesion was excised under general anesthesia by combined naso-endoscopic/trans-oral approach. Grossly, the pear-shaped mass measured about 5 cm×3.5 cm×3 cm, was firm, bosselated, and appeared heterogeneous in consistency. Histopathology revealed stratified squamous epithelium with epidermal appendages (hair follicles, sebaceous glands) along with well-organized, mature cartilage nests and smooth-muscle fibers with a fibro-adipose core, without any evidence of dysplasia (Fig. 2a and b). The features suggested bigerminal choristoma (hairy polyp) of the naso-oropharynx. The symptoms of the patient ameliorated

[☆] Please cite this article as: Dutta M, Ghatak S, Roy S, Sinha R. Naso-orofaríngea coristomas (Hairy pólipos) en adultos: un nuevo caso y revisión de la literatura. Acta Otorrinolaringol Esp. 2016;67:e9–e12.

^{☆☆} This paper has been presented as a Poster in the Annual Meetings of The Triological Society (TRIO) at the 116th Combined Otolaryngology Spring Meetings (COSM) on 10th–14th April 2013, held at Orlando, Florida, USA. Links: <http://www.researchposters.com/Posters/COSM/COSM2013/2-224.pdf> and <http://www.triomeetingposters.org/wp-content/uploads/2013/04/2-224.pdf>.

* Corresponding author.

E-mail address: duttamainak@yahoo.com (M. Dutta).

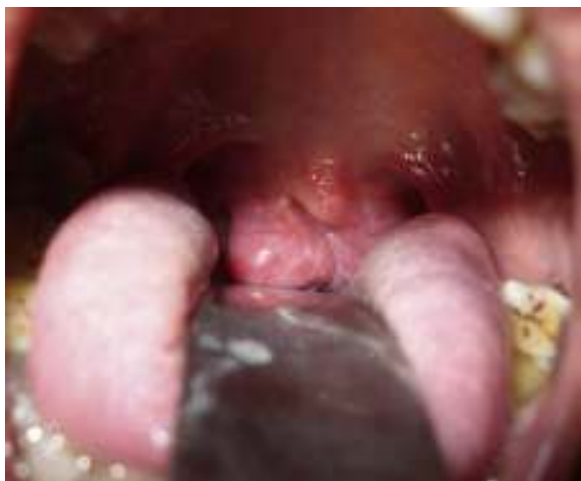

Figure 1 A large fleshy mass could be seen in the oropharynx of this 42-year-old woman. It is free on all sides except superior, and seems to originate from the nasopharynx.

following excision of the mass; she recuperated well and was disease-free on 2-year follow-up.

Discussion

Hairy polyps are mature congenital ectodermal and mesodermal tissue-aggregates, often covered with thin hair, presenting as polypoid masses at anatomically aberrant sites (choristoma).¹ They are almost exclusively seen in neonates and infants and can result in life-threatening asphyxia. Hairy polyps, however, are exceedingly rare in adults¹; a PubMed/MEDLINE® search with the keywords “hairy polyp”, “choristoma”, “adult” and “naso-oropharynx” revealed only 6 such cases in the last 3 decades (Table 1).^{2–6} Unlike in neonates, the presentation in adults is insidious and less dramatic, clinically apparent even beyond the fifth decade in some cases,^{2–4} rising questions whether they should as a rule be considered as developmental malformations.

Hairy polyps in neonates are often associated with congenital disorders (like branchial arch anomalies)^{1,6}; they are linked with development of the first and second pharyngeal arches owing to their endoscopy-documented anatomic associations with the Eustachian tube and tonsillar pillars.¹ However, their occurrence late in the lives of previously asymptomatic adults remains unexplained.¹ Also, no congenital/developmental anomaly has ever been associated with adults.¹ These choristomatous lesions could occur due to delayed pluripotent cell morphogenesis where stem-cells have either escaped the local governing influences due to some inciting factors (trauma), or have been misdirected or trapped on way to their pre-destined target (“missed target hypothesis”).¹ However, focal neoplasia could be an alternative explanation.¹ We have carried out an analysis on the origin of hairy polyps based on an extensive literature review.¹ Though the accumulated data there was based on clinical facets irrespective of age-groups and did not delve in-depth in the molecular aspects, we believe that neoplasia should be considered to explain the pathogenesis of hairy polyps in adults. Being characteristically bigeminal, they have traditionally been considered as “dermoid”. However, the consideration of hairy polyp as teratoma—a true neoplasia—is based on the changing concept of teratoma itself, whereby the classical belief of it being a trigerminous lesion is argued. Teratoma is presently considered a neoplastic mass composed of “any two germ layers”,^{6,7} or even as multiple tissue-aggregate non-indigenous to their anatomic location,⁸ making tissue composition irrelevant. Accordingly, terms like “bigeminal teratoma”⁹ and “benign teratoma”¹⁰ have been attributed to describe hairy polyps. Our description of hairy polyp as *bigeminal choristoma*, therefore, fits in with the evolving concept of teratoma in terms of composition and location. We believe that hairy polyps in adults constitute a distinct entity that has seldom, if at all, been explored before. It is to be acknowledged that their origin remains controversial with no single acceptable theory, and detailed molecular/cytogenetic analysis is required for a suitable explanation. But clinically, hairy polyps in adults seem to represent focal neoplastic

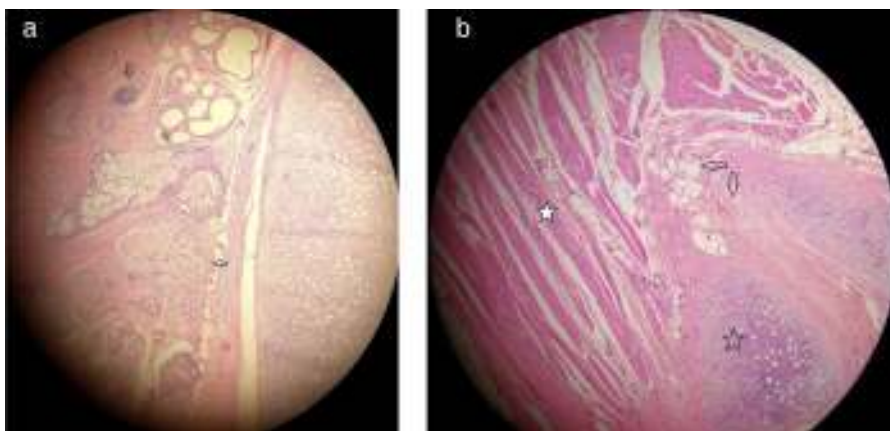


Figure 2 Histopathology showed mature tissue elements of ectodermal and mesodermal origin, including (a) stratified squamous epithelium, skin adnexa (hair follicle, hollow arrow; sebaceous glands, solid arrow), and (b) fibro-adipose tissue (arrows), cartilage (hollow star) and muscle fibers (solid star). (Hematoxylin & Eosin, $\times 400$).

Table 1 Mature Bigerminal Choristomas in Naso-Oropharynx Reported in Adults in English-Language Indexed Literature in the Last 30 Years.

S. No.	Year	Citation	Location/Origin	Age at presentation	Sex	Presentation
1.	1984	Resta et al. ²	Left side of Nasopharynx	71 years	M	Otalgia, otorrhea, hearing loss
2.	1996	Franco et al. ³	Between the palatine arches (bilateral)	58 years	F	Feeding difficulty, respiratory distress
3.	1998	Cerezal et al. ⁴	Left lateral nasopharyngeal wall	50 years	M	Recurrent epistaxis
4.	2006	Green and Pearl ⁵	Left lateral nasopharyngeal wall	24 years	F	Otalgia, hearing loss, feeding difficulty, respiratory distress
5.	2013	Tariq et al. ⁶	Reported a series of 4 patients, of which 2 were in their late teens (aged 17 and 18 years). The lesions were present in the nasopharynx in 2 cases and 1 each in lower lip and palate. Of the 4 patients, 3 were male and 1 female.			
6.	2014	Dutta et al. (present case)	Right lateral nasopharyngeal wall (Eustachian tube opening)	42 years	F	Difficulty in swallowing, intermittent respiratory obstruction

proliferations, or benign teratomas, rather than mere developmental aberrations as widely believed.

Interestingly, in spite of the theoretical and speculated differences in origin, hairy polyps in adults do not differ significantly in management and prognosis from those in the neonates/infants. In both, naso-oropharyngeal hairy polyps are best examined by endoscopy. Occasional bony breach and the need to evaluate the extent might necessitate CT or magnetic resonance imaging, but none such has been reported in adults. Also, as mentioned earlier, developmental or congenital stigmata have not been associated in adults. There is a 3.5-times female preponderance and left-sided predilection in children.¹ But the trend is not so clear in adults due to poor case-strength, though it seems that there is nearly an equal sex-distribution (Table 1). Likewise, although the presentation is more variable like epistaxis and ear problems (Table 1), no standard clinical picture could be derived. In adults however, hairy polyps might be confused with the commoner entities like choanal polyp (as in our patient). Combined naso-endoscopic/trans-oral excision is the treatment of choice.

Although hairy polyps are conventionally considered developmental aberrations related to the pharyngeal arches, an attempt to explain their origin in adults provides valuable insights to the present-day understanding of polygerminal lesions. This is the rationale why we intend to consider adults with hairy polyps as a distinct patient-cohort. Neoplasia should be a possibility as these lesions are being included within the “expanding domain

of teratoma”,¹ interpreted as *neoplastic masses of “any two” germ layers non-indigenous to their site of origin*. Thorough understanding of human embryology is essential to explain hairy polyps in adults, and addition of this case to the existing body of literature would help build a data-pool for the purpose.

Conflict of Interest

The authors have no conflicts of interest to declare.

References

- Dutta M, Roy S, Ghatak S. Naso-oropharyngeal choristoma (hairy polyps): an overview and current update on presentation, management, origin and related controversies. *Eur Arch Otorhinolaryngol*. 2014, <http://dx.doi.org/10.1007/s00405-014-3050-2>. April 27 [E-pub ahead of print].
- Resta L, Santangelo A, Lastilla G. The S. C. ‘hairy polyp’ or ‘dermoid’ of the nasopharynx (an unusual observation in older age). *J Laryngol Otol*. 1984;98:1043–6.
- Franco V, Florena AM, Lombardo F, Restivo S. Bilateral hairy polyp of the oropharynx. *J Laryngol Otol*. 1996;110:288–90.
- Cerezal L, Morales C, Abascal F, Canga A, Gómez J, Bustamante M. Magnetic resonance features of nasopharyngeal teratoma (hairy polyp) in adult. *Ann Otol Rhinol Laryngol*. 1998;107:987–90.
- Green VS, Pearl GS. A 24-year-old woman with a nasopharyngeal mass. *Arch Pathol Lab Med*. 2006;130:e33–4.

6. Tariq MU, Din NU, Bashir MR. Hairy polyp, a clinicopathological study of four cases. *Head Neck Pathol.* 2013;7:232–5.
7. Steinbach TJ, Reischauer A, Kunkemoller I, Mense MG. An oral choristoma in a foal resembling hairy polyp in humans. *Vet Pathol.* 2004;41:698–700.
8. Weaver RG, Meyerhoff WI, Gates GA. Teratomas of the head and neck. *Surg Forum.* 1976;27:539–44.
9. Delides A, Sharifi F, Karagianni E, Stasinopoulou A, Helidonis E. Multifocal bigerminal mature teratomas of the head and neck. *J Laryngol Otol.* 2006;120:967–9.
10. Ferlito A, Devaney KO. Developmental lesions of the head and neck: terminology and biologic behavior. *Ann Otol Rhinol Laryngol.* 1995;104:913–8.