

SCIENTIFIC LETTERS

Severe systemic type 1 pseudohypoaldosteronism: 5 years of evolution



Seudohipoaldosteronismo sistémico grave de tipo 1: 5 años de evolución

Type 1 pseudohypoaldosteronism (PHA-1) was first described in 1958 by Cheek and Perry.¹ It is a rare syndrome of aldosterone unresponsiveness, expressed in two forms: renal PHA-1 and systemic PHA-1.^{2,3} Renal PHA-1 results from autosomal dominant mutations in the kidney mineralocorticoid receptor. As the mineralocorticoid resistance is limited to one organ, the phenotype is milder and often improves spontaneously due to proximal nephron maturation. Systemic PHA-1 results from autosomal recessive mutations in the genes encoding α , β and γ subunit of epithelial sodium channels (ENaC) that exist in multiple organs (kidney, colon, lung, salivary and sweat glands), and therefore the phenotype is severe. Symptoms manifest during the first week of life and require prolonged hospitalizations. Salt-wasting episodes recur frequently and the patients need lifelong high-salt therapy. The mortality rate is high, especially during the neonatal period.

In both forms, diagnosis is established by the presence of high levels of serum aldosterone and plasma renin activity associated with findings typical of hypoaldosteronism (hyponatremia, hyperkalemia and metabolic acidosis).

Herein we describe the evolution of a previously reported case of systemic PHA-1 due to homozygous mutation in intron 3 of the *SCNN1A* gene (c.1052 + 2dupT)⁴ and our therapeutic approach.

Male child, born at full term with birth weight of 3010 g (10–25th percentile). There was no parental consanguinity. His 11-year-old sister had Chediak–Higashi syndrome. He was admitted in the Emergency Room at the tenth day of life with hypovolemic shock, severe hyponatremia (125 mEq/L), hyperkalemia (>10 mEq/L) and metabolic acidosis (pH 7.28, pCO₂ 48.9 mmHg, HCO₃ 22.6 mmol/L, BE –4 mEq/L). He received normal saline to correct dehydration and calcium gluconate, sodium bicarbonate, nebulized salbutamol, insulin infusion and rectal cation-exchange resin (sodium polystyrene sulfonate) to control hyperkalemia. Initially a clinical diagnosis of congenital adrenal hyperplasia was made and he started hydrocortisone and fludrocortisone. Later, an endocrinological study revealed normal levels of serum cortisol, ACTH, 17-hydroxyprogesterone, DHEAS and thyroid function, but high levels of serum aldosterone

(1750 ng/dL: range 7–184 ng/dL) and plasma renin activity (70 ng/ml/h; range 0.4–1.9 ng/ml/h), a diagnosis of PHA-1 was made. Glucose and insulin infusion, calcium gluconate, sodium bicarbonate and nebulized salbutamol were tapered and stopped, and potassium was controlled with high dose of cation-exchange resin. Sodium balance was achieved with 35 mEq/kg/day of sodium chloride. During hospitalization, he presented recurrent episodes of tachypnea and fever mimicking respiratory infections but without identifiable bacterial infection. He was discharged at 5 months of age on oral saline (33 mEq/kg/day) and cation-exchange resin (1 g/kg, six times/day).

He had frequent follow-up pediatric endocrinology consultations with good therapeutic adherence. Nevertheless recurrences of fluid and electrolyte imbalances appeared (Table 1) and he was admitted several times to the emergency room with hypovolemic shock, requiring intensive treatment, increase of cation-exchange resin and frequent nebulized salbutamol and calcium gluconate. He had several episodes that mimicked recurrent respiratory infections, characterized by cough, tachypnea, fever and wheezing. These respiratory episodes probably occurred due to defective sodium dependent liquid absorption and mucociliary function that increased airway liquid volume and narrowed airways lumen.⁵ These symptoms became less severe and less frequent with increasing age.

He had an atopic dermatitis-like rash that was probably the result of increased salt-loss through the skin.⁶

At 18-months-old, he had his first seizure in apirexia. Other six simple febrile seizures occurred. Electroencephalogram and brain magnetic resonance were normal. Analytical monitoring showed transient subclinical hypothyroidism, asymptomatic hypoglycemia and normal ACTH, cortisol, C-peptide, insulin and IGF-1. ACTH stimulation-test was normal.

Medication was provided by nasogastric tube until 2-years-old. Empirically, hydrochlorothiazide was started from 18 –months old until 4 years old (maximum 2 mg/kg/day). Fludrocortisone was gradually reduced until 3 years, and later, cation-exchange resin was also decreased until 3 years and 8 months old. Sodium supplements ranged from 28 to 55 mEq/kg/day.

He had a mild development delay and he was under a stimulation program but presently his Griffiths Mental Development Scale is adequate.

In the majority of cases, growth charts show that patients thrive poorly during the first two years. This is also the most critical period of salt-losing crises. Currently our patient, at 5 –years of age, maintains failure to thrive (height

Table 1 Amount of salt administration and Na⁺/K⁺ balance during specific periods of admissions.

	Amount of salt (mEq/kg/day)	Na ⁺ (mmol/L)	K ⁺ (mmol/L)
Discharge	33	135	4.8
5 mo.			
URTI	31	120	9.1
5.5 mo.			
Vomiting	33	135	7.7
6 mo.			
URTI	34	129	7.8
7 mo.			
Cough	35	131	5.1
8 mo.			
Vomiting	40	132	6.8
11 mo.			
Vomiting	42	128	6.2
12 mo.			
‘‘Hot day’’	47	135	5.8
15 mo.			
Vomiting	51	126	8.0
17 mo.			
Fever	46	135	5.2
2y. 2 mo.			
Vomiting	35	128	8.1
3y.			
Pneumonia	40	135	6.0
3y. 2 mo.			
URTI	45	128	5.6
3y. 3 mo.			
Vomiting	45	127	6.4
3y. 8 mo.			
URTI	40	129	6.4
4y. 2 mo.			
Fever	42	134	4.8
4y. 6 mo.			
‘‘Hot day’’	43	124	6.7
5y.			

Mo., months; URTI, upper respiratory tract infections; y., years.

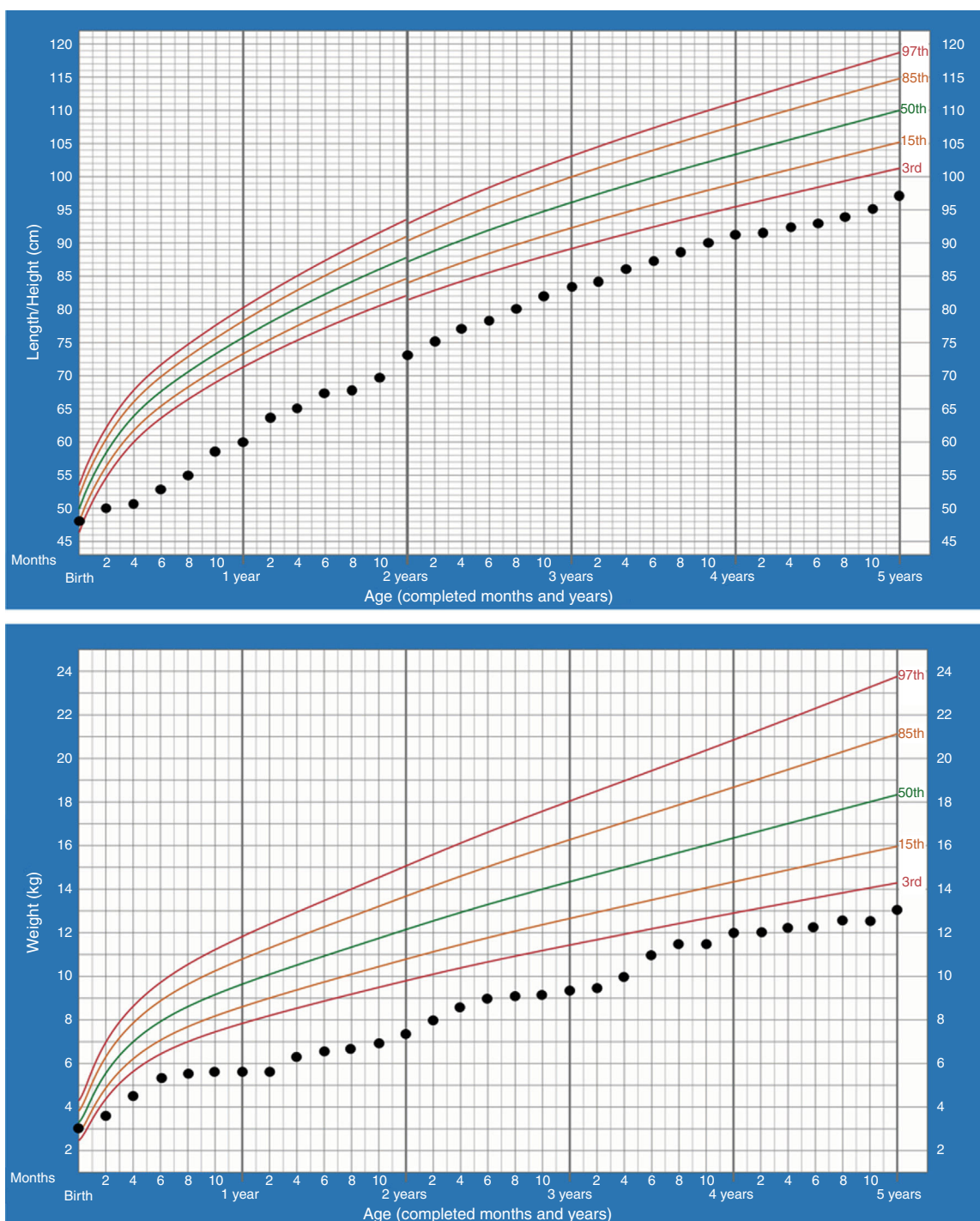
–2.61SDS, weight –3.53SDS) but regular growth velocity (Fig. 1). He only keeps oral sodium supplement.

Management of PHA-1 patients is very challenging since there are no evidence-based recommendations. There is scarce literature about hydrochlorothiazide use but it is used to deliver more sodium to the potassium secretory segment. The dosage of sodium per day to establish salt homeostasis varies greatly and has to be readjusted frequently due to changes in body weight. In severe cases this is not enough to prevent salt loss, and death can occur. Moreover, the quality of life of these patients and families is poor: recurrent hospitalizations, large amount of medications, failure to thrive, and susceptibility to infections. An age-dependent trend of amelioration has been reported. The reasons for this improvement are genotype, activity of the truncated ENaC subunit, compensatory increased expression of the NaCl-cotransporter and continued salt supplementation.^{7,8}

The diversity of mutations corresponds to the heterogeneity of clinical phenotypes.³ Mutations are mainly localized on the *SCNN1A* gene. Most of them are nonmissense mutations, leading to abnormal length protein and

a severe phenotype, while missense mutations lead to a normal length protein and are associated with milder phenotypes. In our case, there is a splice site mutation not previously described in the literature; therefore, we do not know its precise effect on the ENaC structure and function. Its location is close to the highly conserved donor splice site of intron 3 and most probably affects the RNA splicing, therefore leading to a grossly abnormal protein.

We would like to share our experience on the difficulties of the management of a patient with genetically proven systemic PHA-1 diagnosed in the newborn period. He fulfilled the criteria listed by Edelheit et al. for severe systemic PHA1: severe salt wasting, frequent hospitalization, recurrent respiratory illness, growth failure, high risk of mortality with requirement of high doses of sodium and cation-exchange resin.⁹ Our patient had a new splicing mutation in intron 3 and presented a severe phenotype. Despite initial poor prognosis, there was a favorable evolution. Severe presentation in the neonatal period does not indicate life-long severity of the disease.



WHO Child Growth Standards

Figure 1 Growth charts (longitudinal height and weight) from birth to 5 years of age.

Ethical declarations

The authors state that the procedures followed meet the regulations of the responsible clinical ethical research committee, the World Health Organization and the Declaration of Helsinki.

The authors declare that they have complied the protocols of their workplace for publishing patients' data. The

patients included have received sufficient information and have given written informed consent.

Funding

No honorarium, grant, or other form of payment was given to anyone to produce the manuscript.

Conflict of interest

There are no conflicts of interest.

References

- Cheek DB, Perry JW. A salt wasting syndrome in infancy. *Arch Dis Child.* 1958;33:252–6.
- Hanukoglu A. Type I pseudohypoadosteronism includes two clinically and genetically distinct entities with either renal or multiple target organ defects. *J Clin Endocrinol Metab.* 1991;73:936–44.
- Bonny O, Rossier BC. Disturbances of Na/K balance: pseudohypoadosteronism revisited. *J Am Soc Nephrol.* 2002;13:2399–414.
- Silva N, Costa M, Silva A, Sá C, Martins S, Antunes A, et al. A case of systemic pseudohypoadosteronism with a novel mutation in the SCNN1A gene. *Endocrinol Nutr.* 2013;60:33–6.
- Kerem E, Bistrizter T, Hanukoglu A, Hofmann T, Zhou Z, Bennett W, et al. Pulmonary epithelial sodium-channel dysfunction and excess airway liquid in pseudohypoadosteronism. *N Engl J Med.* 1999;341:156–62.
- Martin JM, Calduch L, Monteagudo C, Alonso V, Garcia L, Jorda E. Clinico-pathological analysis of the cutaneous lesions of a patient with type I pseudohypoadosteronism. *J Eur Acad Dermatol Venereol.* 2005;19:377–9.
- Hanukoglu A, Hanukoglu I. Clinical improvement in patients with autosomal recessive pseudohypoadosteronism and the necessity for salt supplementation. *Clin Exp Nephrol.* 2010;14:518–9.
- Adachi M, Asakura Y, Muroya K, Tajima T, Fujieda K, Kuribayashi E, et al. Increased Na reabsorption via the Na-Cl cotransporter in autosomal recessive pseudohypoadosteronism. *Clin Exp Nephrol.* 2010;14:228–32.
- Edelheit O, Hanukoglu I, Gizewska M, Kandemir N, Tenenbaum-Rakover Y, Yurdakök M, et al. Novel mutations in epithelial sodium channel (ENaC) subunit genes and phenotypic expression of multisystem pseudohypoadosteronism. *Clin Endocrinol (Oxf).* 2005;62:547–53.

Maria Miguel Gomes^{a,*}, Sofia Martins^a, Olinda Marques^b, Nicole da Silva^a, Ana Antunes^a

^a *Department of Pediatrics, Hospital de Braga, Sete Fontes, São Victor, 4710-243 Braga, Portugal*

^b *Department of Endocrinology, Hospital de Braga, Sete Fontes, São Victor, 4710-243 Braga, Portugal*

*Corresponding author.

E-mail address: mariamgomes@hotmail.com (M.M. Gomes).

2173-5093/

© 2016 SEEN. Published by Elsevier España, S.L.U. All rights reserved.

Autosomal dominant hypocalcaemia: A novel mutation[☆]



Hipocalcemia autosómica dominante: una nueva mutación

Dear Editor:

We present the finding of a new activating mutation of the calcium-sensing receptor (CaSR) gene. The mutation was identified in 2 subjects from the same family; they had asymptomatic chronic hypocalcemia with low parathyroid hormone (PTH) and inappropriate urinary calcium excretion.

The CaSR is primarily expressed in the parathyroid glands and the kidney. It is controlled by extracellular calcium, and allows for the regulation of PTH secretion and the tubular reabsorption of calcium, depending on changes in extracellular calcium levels.¹ Genetic changes in the CaSR may cause changes in calcium homeostasis. Both activating and inactivating changes in calcium metabolism caused by mutations have been reported.² One third of patients with idiopathic congenital hypoparathyroidism may have activating CaSR mutations. This results in autosomal dominant hypocalcemia (ADH) that may present a broad range of clinical manifestations.^{3,4} Over 50 mutations causing

ADH have been identified to date. ADH is characterized by hypocalcemia, detectable but inappropriately low PTH, and high calciuria, considering the hypocalcemia.⁵ Many of these patients, particularly those with no symptoms, are underdiagnosed or diagnosed with idiopathic hypoparathyroidism.⁶ Treatment with calcium or vitamin D supplements may exacerbate hypercalciuria, causing nephrocalcinosis, stones, and renal failure.

We report the case of a 25-year-old woman, referred to our clinic for hypocalcemia detected as an incidental finding in routine pregnancy check-ups 2 years previously. According to the patient, the diagnosis had not been investigated further and no treatment was started as she had no symptoms.

Low calcium levels were confirmed (7.76 mg/dL; normal range: 8.6–10), together with PTH levels in the low normal range (20 pg/mL; normal range: 15–65); the urinary calcium level was 34.3 mg/24 h (normal: 0–300). On further investigation into her family history, a similar pattern of hypocalcemia with low PTH levels was found in her father. Both patients were found to have normal 25- and 1.25-vitamin D levels, and treatment with oral calcium caused increased urinary calcium levels in both, with no significant changes in either serum calcium or PTH levels.

A genetic test was proposed to the patient and her father.

After obtaining their informed consent, the CaSR gene was studied. A missense mutation was found in exon 7: c.2621G > T (p.Cys874Phe). This mutation was assessed using bioinformatic applications (MutationTaster and PolyPhen-2) and was considered pathogenic.

The father was referred for monitoring to his reference hospital. We completed the study of our patient with a nephrourological ultrasound, which revealed no

[☆] Please cite this article as: Urbón López de Linares L, Crespo Soto C, Cuellar Olmedo L, Piedra León M. Hipocalcemia autosómica dominante: una nueva mutación. *Endocrinol Nutr.* 2016;63:505–506.