

ENDOCRINOLOGÍA Y NUTRICIÓN

www.elsevier.es/endo



SCIENTIFIC LETTERS

Ganglioneuroma as an uncommon cause of adrenal tumor[☆]

Ganglioneuroma como causa infrecuente de tumor suprarrenal

Ganglioneuroma (Gn) is a benign tumor of the sympathetic nervous system that may occur along the paravertebral sympathetic ganglia, from the neck to the pelvis, and occasionally in the adrenal medulla. Adrenal Gn (AGn) usually occurs asymptotically in patients under 20 years of age and is incidentally diagnosed in imaging tests requested for other reasons. Despite its benign nature, conversion to a malignant schwannoma has been documented in some cases, and it has been associated with tumors such as pheochromocytoma. Gn is treated by surgical resection and has an excellent prognosis. We report two patients with AGn diagnosed and operated on at our hospital.

Case 1. This was an 18-year-old female outpatient with an unremarkable history who attended for non-specific abdominal pain and was found to have a solid left adrenal mass in an ultrasound examination. A computed tomography (CT) scan confirmed the presence of a homogeneous, solid adrenal tumor 6 cm in diameter showing peripheral enhancement. Laboratory tests and functional hormone screening tests were normal. Based on the diagnosis of a nonfunctioning adrenal mass, laparoscopic left adrenalectomy was performed. The patient was discharged 24 h after surgery, and a 7 cm tumor pathologically diagnosed as Gn was found in the surgical specimen.

Case 2. This was a 28-year-old male patient with no remarkable history except for recurrent episodes of gastroenteritis and non-specific abdominal pain. An outpatient ultrasonography revealed a suspected right adrenal tumor. An abdominal CT scan confirmed the presence of a 5.8 cm × 4 cm adrenal mass with a mixed low density. As with the previous patient, routine laboratory tests and blood hormone profile were normal. A non-functioning incidental adrenal tumor was diagnosed, and laparoscopic right adrenalectomy was performed. The patient was also discharged at 24 h with no postoperative complications, and the pathological department reported a ganglioneuroma.

Gn is a rare, slowly growing tumor arising from primary sympathetic neurons of the neural crest. Gn belongs to the group of neurogenic tumors arising at this level, together with ganglioblastoma and neuroblastoma, but unlike these it consists of mature ganglion cells with no malignant potential.^{1–5} There is controversy as to whether Gn may occur *de novo* (primary Gn) or is the result of differentiation and maturation from ganglioblastoma or neuroblastoma.^{3,4} Tumors occur along the paravertebral sympathetic chain, from the neck to the pelvis, and occasionally in the adrenal medulla. They are most commonly located in the posterior mediastinum (40%) and retroperitoneum (37%), and more rarely in the anterior mediastinum, stomach, appendix, or prostate.^{1–5} Adrenal Gn accounts for approximately 15–30% of cases.

The incidence of AGn has increased in recent years as the result of the growing detection rate of incidentalomas in increasingly performed imaging tests of an improved quality. It is estimated that an adrenal tumor is incidentally found in 1–10% of abdominal CT scans. Of these, 1–6% are Gns.¹ Although cases have also been reported in children, AGn mainly affects young adults with no sex predominance.^{1,2} Approximately half the patients have no symptoms, and when these occur, the most common clinical signs include non-specific abdominal pain or a palpable mass. Gns are usually non-secretory from the functional viewpoint, but 20–30% secrete catecholamines and metabolites. When hormone activity exists, diarrhea (release of vasoactive intestinal peptide), sweating, or high blood pressure may be associated, but these do not cause clinical emergencies, unlike in pheochromocytoma.⁴

The first step in diagnosis always consists of hormone tests to show a non-functioning tumor: free cortisol in 24-h urine, suppression with dexamethasone 1 mg, serum basal cortisol, ACTH, renin, plasma aldosterone, and catecholamines (epinephrine and norepinephrine) and their metabolites in blood and urine.³ The most helpful imaging tests are abdominal CT and magnetic resonance imaging (MRI), which have been shown to be superior to ultrasonography for the detection and characterization of adrenal disease.¹ Gn is seen at CT as a well-defined, oval or lobulated solid mass with a low attenuation (usually less than 40 Hounsfield units) and a fibrous capsule (Fig. 1). Intratumoral calcifications are seen in 42–60% of cases, and may sometimes be heterogeneous after contrast administration.^{2,3,5,6} In MRI they show a low intensity signal in T1 and heterogeneity with high intensity in T2.⁵ Positron

[☆] Please cite this article as: Titos García A, et al. Ganglioneuroma como causa infrecuente de tumor suprarrenal. Endocrinol Nutr. 2011;58(8):443–6.

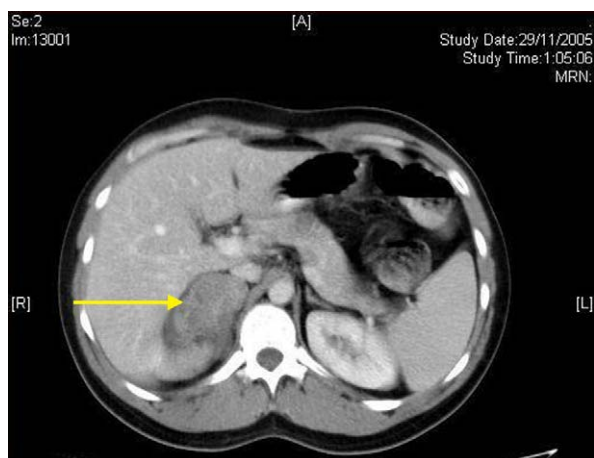


Figure 1 CT image showing a low attenuation oval solid mass in the right adrenal gland.

Emission Tomography (PET) has recently been incorporated to complement both tests in Gn diagnosis and, above all, to rule out malignant adrenal neoplastic conditions.¹ Final diagnosis is made after histopathological analysis of the surgical specimen. The characteristic microscopic appearance is a uniform image with a stroma consisting of irregularly intertwined transversely and longitudinally oriented Schwann cells. Fat may occasionally be found. Relatively mature neurons with little Nissl substance and forming small groups or nests are found scattered throughout this Schwannian background. A bulky eosinophilic cytoplasm and one to three nuclei with mild to moderate atypia are typically seen (Fig. 2). The use of fine needle aspiration is limited by the possibility that the lesion is malignant (adrenal carcinoma or metastasis) or cystic in nature and by the difficulty in differentiating adenoma from carcinoma.^{2,3}

The indication of surgery for incidental, non-functioning adrenal tumors is not clearly defined and will depend on lesion size and radiographic characteristics. However,

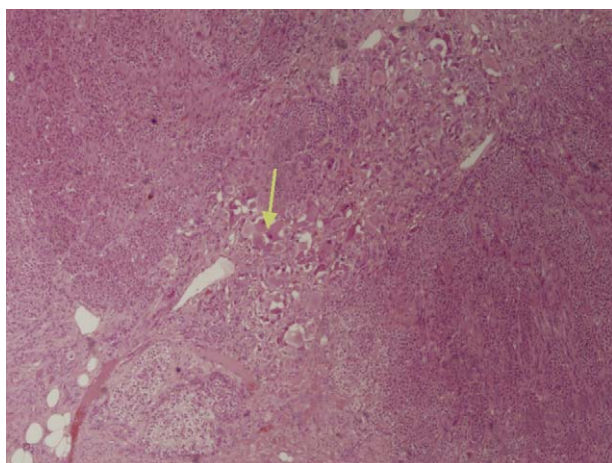


Figure 2 Mature ganglion cells forming small groups and nests (arrow) with neuromatous stroma, growing on normal adrenal tissue.

surgery should be performed on symptomatic tumors greater than 6 cm in diameter (an increased incidence of carcinoma has been seen in these lesions) or showing radiographic characteristics of malignancy.^{3,7} Clinical and radiographic monitoring is usually done for lesions less than 4 cm in size, although some authors advise surgical excision in young patients because of the very long follow-up that would be required and the anxiety this may cause.^{7,8} Treatment for lesions ranging from 4 and 6 cm in size is controversial, and both surgical excision and monitoring have been recommended. Surgery should be considered if the tumor grows or radiographic signs of malignancy occur.^{3,7}

Laparoscopy has become the procedure of choice for all adrenal pathology, including incidental, on-functioning masses, and is increasingly less limited by size.⁸ There is no current agreement about the maximum tumor size amenable to laparoscopic surgery. The traditionally accepted limit is 6 cm, but there are many series reporting surgery for greater tumors, up to 13 cm in size.^{1,7-10} A transperitoneal approach is usually used, but a retroperitoneal approach is preferred by some groups. Today, the presence of an invasive malignant tumor or venous thrombosis associated with the renal or suprarenal veins is an absolute contraindication.⁷⁻¹⁰ The prognosis of AGn after surgical resection is excellent, even when complete excision is not possible.¹⁰ Tumor recurrence is rare, and should be considered to result from an incomplete initial surgery (and should therefore be called "persistence" instead).

References

1. Zografos GN, Kothionidis K, Ageli C, Kopanakis N, Dimitriou K, Papalioudi E, et al. Laparoscopic resection of large adrenal ganglioneuroma. *JLS*. 2007;11:487-92.
2. Dubois C, Jankowski A, Gay Jeune C, Chabre O, Pasquier D, Ferretti G. Imagerie du ganglioneurome surrénalien: a propos d'un cas. *J Radiol*. 2005;86:659-62.
3. Arredondo Martínez F, Soto Delgado M, Benavente Fernández A, Basquero González B, Zurera Cosano A, Linares Armada R. Ganglioneuroma suprarrenal. Aportación de un nuevo caso. *Actas Urol Esp*. 2003;27:221-5.
4. Brouwers F, Eisenhofer G, Lenders J, Pacak K. Emergencies caused by pheochromocytoma, neuroblastoma or ganglioneuroma. *Endocrinol Metab Clin N Am*. 2006;35:699-724.
5. Guo YK, Yang ZG, Li Y, Deng YP, Ma ES, Min PQ, et al. Uncommon adrenal masses: CT and MRI features with histopathologic correlation. *Eur J radiol*. 2007;62:359-70.
6. Maweja S, Materne R, Detrembleur N, De Leval L, Defecheroux T, Meurisse M, et al. Adrenal ganglioneuroma. *Am J Surg*. 2007;194:683-4.
7. Yamaguchi K, Hara I, Takeda M, Tanaka K, Yamada Y, Fujisawa M, et al. Two cases of ganglioneuroma. *Urology*. 2006;67:622.e1-4.
8. Ramírez-Plaza CP, Rodríguez-Cañete A, Domínguez-López ME, Valle-Carbajo M, Jiménez-Mazure C, Marín-Camero N, et al. Desarrollo y evolución de la suprarrenalectomía laparoscópica en una unidad especializada: de los casos iniciales al hospital de día. *Endocrinol Nutr*. 2010;57:22-7.
9. Liao CH, Chueh SC, Lai MK, Hsiao PJ, Chen J. Laparoscopic adrenalectomy for potentially malignant adrenal tumors greater than 5 centimeters. *J Clin Endocrinol Metab*. 2006;91:3080-3.

10. Bingbing S, Han-zhong L, Cheng C, Shi R, Hua F, Jin W, et al. Differential diagnosis and laparoscopic treatment of adrenal pheochromocytoma and ganglioneuroma. *Chin Med J*. 2009;122:1790–3.

Alberto Titos García*, César Pablo Ramírez Plaza, Patricia Ruiz Diéguez, Naiara Marín Camero, Julio Santoyo Santoyo
U.G.C. Cirugía General, Digestiva y Trasplantes, Hospital Regional Universitario Carlos Haya, Málaga, Spain

*Corresponding author. Secretaría del Servicio de Cirugía General, Digestiva y Trasplantes., Hospital Regional Universitario Carlos Haya, 29010 Málaga, Spain.
E-mail address: albertotitosg@hotmail.com
(A. Titos García).

Acute hallucinatory psychosis secondary to oral glucocorticoid treatment in a patient diagnosed with Sheehan's syndrome[☆]

Psicosis alucinatoria aguda secundaria a tratamiento con glucocorticoides orales en una paciente diagnosticada de síndrome de Sheehan

Patients with untreated chronic adrenal insufficiency, high-dose glucocorticoid treatment, and Cushing's syndrome are known to frequently experience psychiatric changes. However, psychiatric changes, occurring after glucocorticoid replacement therapy that has been started following the diagnosis of adrenal insufficiency, are less well known.

We report the case of a 53-year-old female patient with a personal history of a complicated delivery in 1981 (28 years ago) requiring several transfusions of packed red cells for severe bleeding and hypotension. After delivery, the patient experienced agalactia, early menopause (amenorrhea since delivery) and hepatitis C virus (HCV) infection. She was on follow-up at the gastrointestinal clinic, but had not returned there for 8 years, and had been diagnosed with liver disease with Child C stage cirrhosis induced by HCV. The patient was admitted to hospital on December 2009 for obnubilation, bradypsychia, impaired speech, and temporal and spatial disorientation secondary to hyponatremia and hypoglycemia. She also reported significant fatigue, a depressive mood, and weight loss over several years. Examination revealed eyebrow alopecia, absence of pubic and axillary hair, pallor, and thinness. [Table 1](#) shows laboratory and imaging data.

Based on these clinical and laboratory findings, the patient was diagnosed with hypopituitarism due to Sheehan's syndrome. Replacement therapy was started with levothyroxine (25 µg/day) and hydrocortisone (60 mg/day in three divided doses). Her clinical condition improved after the start of treatment, with normalization of blood glucose levels and correction of hyponatremia, but three days

later the patient experienced anxiety, euphoria, and lack of inhibition. This condition progressed in two days to a hallucinatory psychosis with visual hallucinations with no delusional interpretation and partial subsequent recall. As there was no personal or family history of psychiatric disease or use of toxic substances, and after ruling out an infectious etiology to account for the condition, a "steroid psychotic crisis" was diagnosed, and treatment was started with tiapride and haloperidol. Glucocorticoid doses were decreased to 10 mg/day.

The patient experienced a gradual improvement in the five days following the start of treatment. The psychotic symptoms disappeared, and treatment with psychodrugs was discontinued at two weeks and has not been needed since then. After 6 days of treatment with hydrocortisone 10mg/day, the dose was increased to 30mg/day. The patient then experienced a mild exacerbation of the psychotic conditions which required a dose reduction to 10mg/day again. This dose was subsequently increased very slowly and gradually.

The patient is currently being treated with hydrocortisone 20 mg/day and levothyroxine 75 µg/day.

Sheehan's syndrome, currently uncommon thanks to improved obstetric procedures, is caused by pituitary infarction after severe bleeding during or after delivery. Clinical signs vary, depending on the severity of the condition and range from acute severe panhypopituitarism to less severe forms including agalactia, lack of resumption of the menstrual cycle after delivery, and a clinical picture of indolent hypopituitarism.¹ In such cases, prolactin, gonadotropin, and growth hormone deficiency occur in 90–100% of patients, while ACTH and TSH deficiency is a little less common (60–75% of patients). Diabetes insipidus rarely occurs. The most common water and electrolyte change in Sheehan's syndrome is hyponatremia (occurring in 35–65% of patients), resulting from cortisol deficiency, hypothyroidism, and a potentially impaired vasopressin secretion.² These patients often experience psychiatric changes such as depression, impaired memory, and difficulty in concentration, caused by untreated, long-standing hypothyroidism and chronic adrenal insufficiency. These changes are resolved when replacement therapy is started.

As regards psychiatric pathology and glucocorticoids, psychiatric changes are common in patients with untreated, long-standing hypocortisolism, as previously discussed. Psychiatric changes caused by the administration of high glucocorticoid doses, which usually occur early after the

[☆] Please cite this article as: Martín López M, et al. Psicosis alucinatoria aguda secundaria a tratamiento con glucocorticoides orales en una paciente diagnosticada de síndrome de Sheehan. *Endocrinol Nutr*. 2011;58:445–6.