



Image of the month

Perianal ulcers due to over-the-counter anti-hemorrhoidal cream

Úlceras perianales por crema antihemorroidal de venta libre

Elvis Vargas Castillo,* Franco Marinello, María Angeles Boleko, Manuel Prados Manuel

Unidad de Coloproctología, Hospital Universitario Dexeus, Barcelona, Spain

Perianal ulcers (PUs) can be secondary to many factors. When PUs are related to medication, inadequate perfusion of the perianal region appears to be the main pathophysiological factor. We present the clinical case of a PU in a 69-year-old man, after continuous use for 4 months of an antihaemorrhoid cream containing triamcinolone, lidocaine, and pentosan polysulphate sodium (Anso®), and its course after discontinuing use of the cream. This case highlights the potential harmful effect of a pharmacological product that does not require a prescription and the need to question the application of topical agents in patients with PU (Fig. 1).

Case diagnosis: perianal ulcers due to over-the-counter anti-haemorrhoid cream.

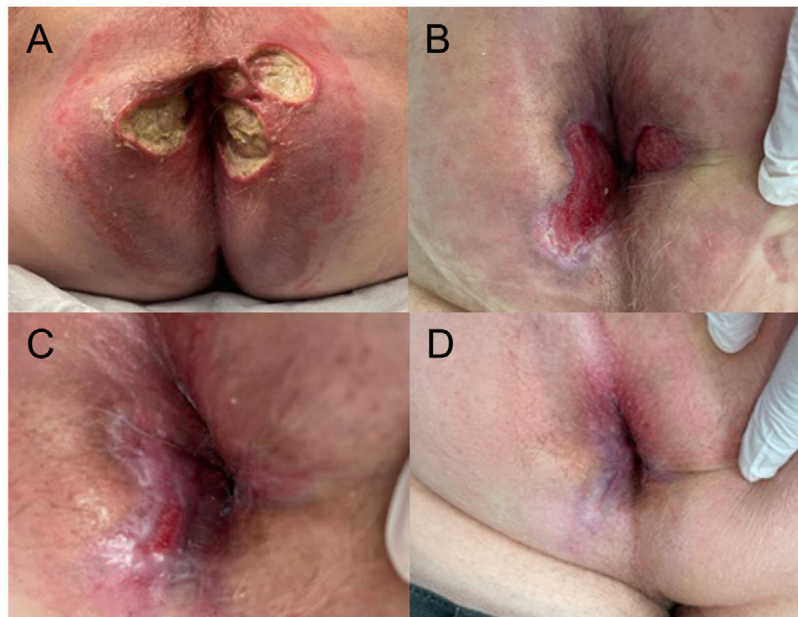


Fig. 1 – Perianal ulcers at first consultation (A), 4 (B), 6 (C), and 8 (D) weeks after discontinuation of treatment with antihaemorrhoid cream.

* Corresponding author.

E-mail address: elvisvargasc@hotmail.com (E. Vargas Castillo).

<http://dx.doi.org/10.1016/j.cireng.2022.09.018>

2173-5077/© 2022 AEC. Published by Elsevier España, S.L.U. All rights reserved.