



Image of the month

Pneumatosis intestinalis, a surgical emergency[☆]

Neumatosis intestinal, urgencia quirúrgica

Saioa Ercoreca Tejada,^{*} Cristina Plata Illescas, Natalia Zambudio Carroll,
Jesús María Villar del Moral

Servicio de Cirugía General y del Aparato Digestivo, Hospital Virgen de las Nieves, Granada, Spain

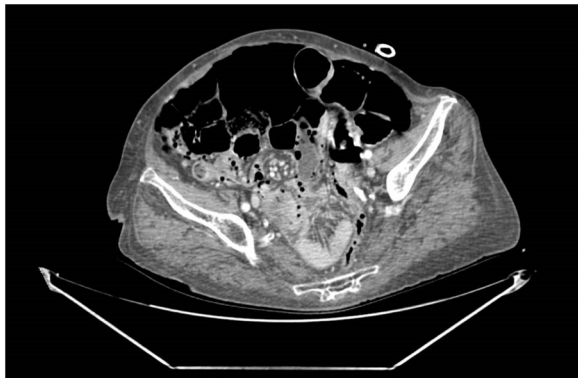


Fig. 1 – Abdominal CT scan: pneumoperitoneum and pneumatosis intestinalis.

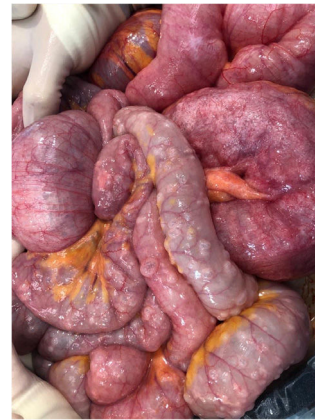

Fig. 2 – Intestinal loops with abundant wall pneumatosis.

A 77-year-old woman with a history of surgery due to intestinal obstruction caused by an adhesion band came to the emergency room due to progressive abdominal pain and constipation over the previous 24 h. Abdominal computed tomography showed considerable pneumoperitoneum and fluid, suggestive of a perforation with generalized peritonitis and pneumatosis in the descending colon and small intestine, with no signs of intestinal ischemia (Fig. 1), which was resected (Fig. 2). We reviewed the entire intestinal package but found no interruption or signs of ischemia. The patient presented no postoperative complications.

Diagnosis: intestinal obstruction with pneumatosis.

[☆] Please cite this article as: Ercoreca Tejada S, Plata Illescas C, Zambudio Carroll N, Villar del Moral JM. Neumatosis intestinal, urgencia quirúrgica. Cir Esp. 2021. <https://doi.org/10.1016/j.ciresp.2021.04.005>

^{*} Corresponding author.

E-mail address: saioa_erkoreca@hotmail.com (S. Ercoreca Tejada).