



Image of the Month

Evisceration due to spontaneous rupture of umbilical hernia in adult[☆]



Evisceración por rotura espontánea de hernia umbilical en adulto

Martín Adrián Bolívar-Rodríguez,^{*} Pedro Alejandro Magaña-Zavala,
Adrián Pamanes-Lozano, Edgar Fragoza-Sánchez

Departamento de Cirugía General, Centro de Investigación y Docencia en Ciencias de la Salud, Universidad Autónoma de Sinaloa, Hospital Civil de Culiacán, Culiacán, Sinaloa, Mexico

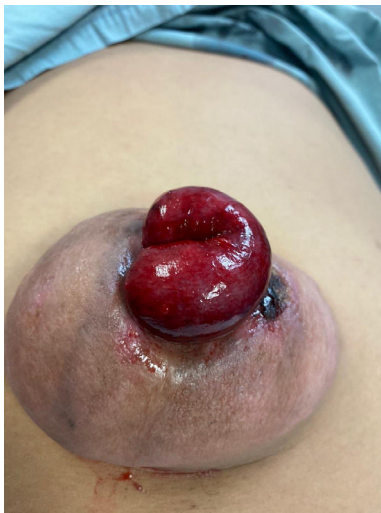

Fig. 1

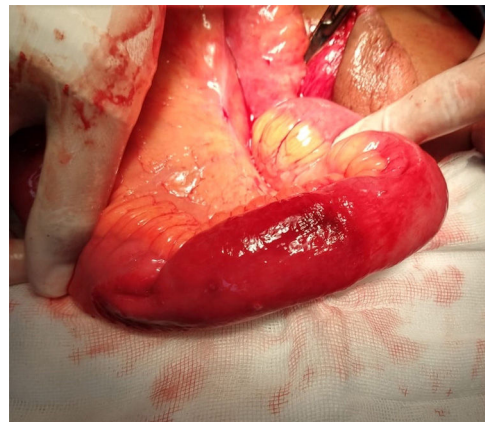


Fig. 2

The patient is a 46-year-old male with an umbilical hernia that had been developing for the past 6 years, with no other medical history. After physical exertion while working, he was admitted to the emergency room due to sudden abdominal pain, a limited amount of bleeding, and a reddish umbilical tumor. Physical examination revealed an incarcerated umbilical hernia and exposure of the intestinal loop, which showed discoloration (Fig. 1). During urgent surgery, the hernia content was released (Fig. 2) and reduced to the abdominal cavity, followed by wall repair performed with simple interrupted sutures of non-absorbable material. The patient showed satisfactory evolution and was discharged 48 h later.

Spontaneous rupture of umbilical hernia with evisceration in adults without cirrhosis is very rare.

[☆] Please cite this article as: Bolívar-Rodríguez MA, Magaña-Zavala PA, Pamanes-Lozano A, Fragoza-Sánchez E. Evisceración por rotura espontánea de hernia umbilical en adulto. Cir Esp. 2021. <https://doi.org/10.1016/j.ciresp.2020.10.015>

^{*} Corresponding author.

E-mail address: bolivarmartin64@hotmail.com (M. A. Bolívar-Rodríguez).