



Image of the month

Retrorectal cystic hamartoma with extrapelvic extension [☆]



Hamartoma quístico retrorrectal con componente extrapélvico

Javier Gómez Sánchez, * Marisol Zurita Saavedra, Javier Gutierrez Sainz, Benito Mirón Pozo

Servicio de Cirugía General y del Aparato Digestivo, Hospital Clínico San Cecilio, Granada, Spain

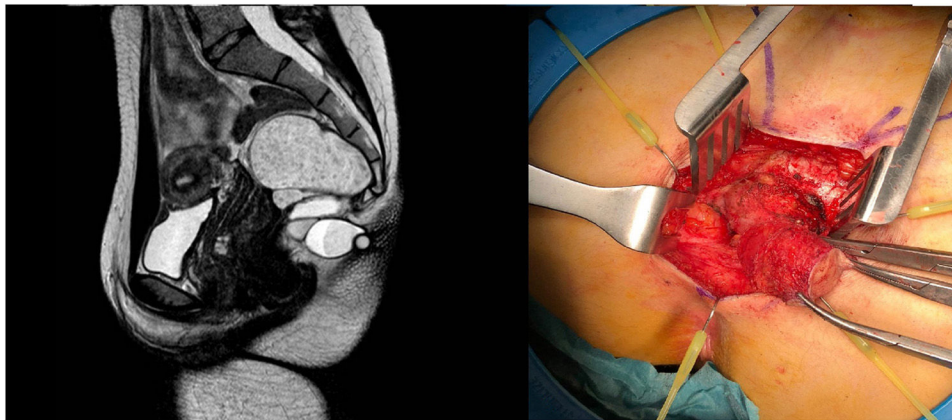


Fig. 1

A 23-year-old female patient consulted for a 3-cm fibroelastic intergluteal tumor with progressive growth in recent years. She did not present suppuration or intestinal/urinary disorders. Rectal examination revealed slight posterior bulging, with no endorectal alterations.

Ultrasound and pelvic magnetic resonance imaging identified a multilobulated mass with well-defined borders adjacent to the rectum, which extended outside the pelvic cavity through a midline defect that was caudal to the sacrum, compatible with a retrorectal cystic hamartoma with extrapelvic extension. The lesion was excised using an abdominosacral approach, and the pathological study confirmed the diagnosis (Fig. 1).

Please cite this article as: Gómez Sánchez J, Zurita Saavedra M, Gutierrez Sainz J, Mirón Pozo B. Hamartoma quístico retrorrectal con componente extrapélvico. Cir Esp. 2021;99:230.

* Corresponding author.

E-mail address: Javiergomezsanchez.jg@gmail.com (J.G. Sánchez).