



Image of the month

Non-operative management to gallstone ileus[☆]

Manejo conservador en íleo biliar

María Pérez Reyes,^{*} Irene Mirón Fernández, María Pitarch Martínez, Julio Santoyo Santoyo

Hospital Regional Universitario de Málaga, Málaga, Spain

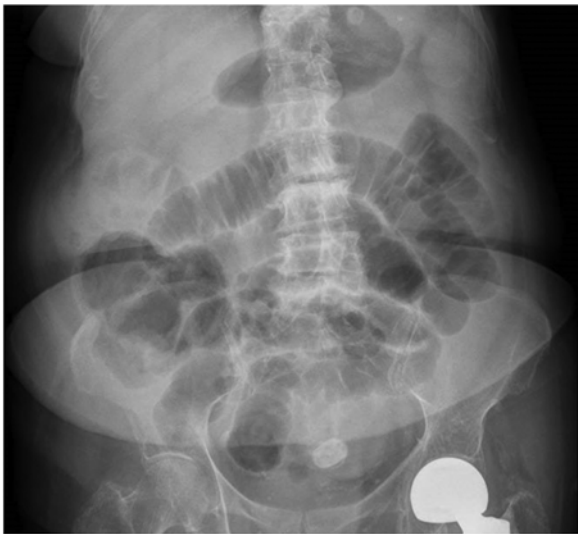

Fig. 1

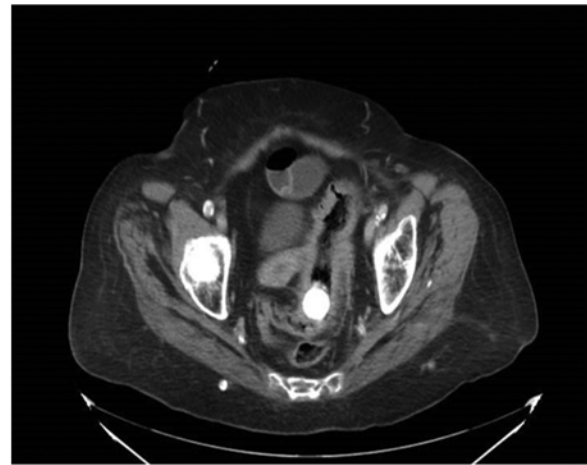


Fig. 2

A 91-year-old patient with a history of HTN came to the emergency room due to nausea, vomiting for the past 4 days and absence of bowel movements for 48 h. On examination, we observed abdominal distention and pain in the hypogastrium, with no peritoneal irritation. Radiography (Fig. 1) and abdominal CT scan (Fig. 2) revealed a gallstone in the sigmoid colon with retrograde dilation of the colon and small intestine as well as cholecystoduodenal fistula. Urgent colonoscopy was performed, during which the lithiasis was observed 10 cm from the anal margin, but it could not be removed. Finally, after the administration of enemas, expulsion was achieved without complications.

[☆] Please cite this article as: Pérez Reyes M, Mirón Fernández I, Pitarch Martínez M, Santoyo Santoyo J. Manejo conservador en íleo biliar. Cir Esp. 2020;98:556.

^{*} Corresponding author.

E-mail address: maria.perezreyes1991@gmail.com (M. Pérez Reyes).