



Image of the month

Use of Fluorescent Imaging With Indocyanine Green (ICG) for the Identification of Intestinal Lymphoma[☆]



Uso de la fluorescencia con verde de indocianina (ICG) en la identificación de un linfoma intestinal

Pilar Fernández Veiga,^{a,*} Eugenio Licardie,^b Isaías Alarcón,^{a,b} Salvador Morales-Conde^{a,b}

^a Unidad de Innovación en Cirugía Mínimamente Invasiva, Servicio de Cirugía general y Digestiva, Universidad de Sevilla, Hospital Universitario Virgen del Rocío, Sevilla, Spain

^b Servicio de Cirugía General y Digestiva, Hospital Quironsalud Sagrado Corazón, Sevilla, Spain

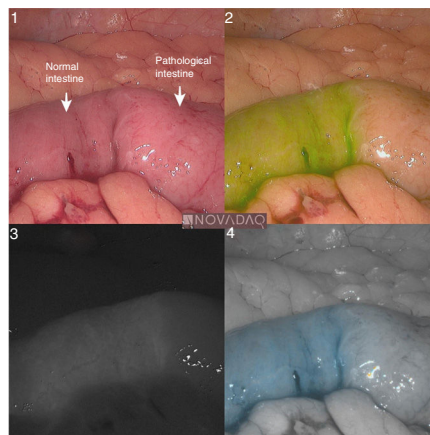


Figure 1

Image-guided surgery is one of the most developmental area in the surgical setting, highlighting fluorescent imaging with indocyanine green (ICG).

We want to present a case of female who has had a Follicular Lymphoma treated with Rituximab 10 years ago.

The patient underwent surgery because we suspected a possible intestinal lymphoma recurrence.

We performed a laparoscopy using the PINPOINT (NOVADAQ) fluorescent system (Images 2, 3, 4) applying 15 mg of ICG intravenously at the beginning of the surgery. It allowed us to identify the sick segment of the small intestine and locoregional lymph nodes which were biopsied.

The histology results showed a Follicular lymphoma.

[☆] Please cite this article as: Fernández Veiga P, Licardie E, Alarcón I, Morales-Conde S. Uso de la fluorescencia con verde de indocianina (ICG) en la identificación de un linfoma intestinal. Cir Esp. 2020;98:628.

* Corresponding author.

E-mail address: pilar.fveiga@gmail.com (P. Fernández Veiga).