



## Image of the month

Proctology and Sports Medicine: The Third Testicle<sup>☆</sup>

## Proctología y medicina deportiva: el tercer testículo

Tania Pastor,<sup>\*</sup> Carlos Placer, Juan Tubía, Jose María Enríquez-Navascués

Servicio de Cirugía General y Digestiva, Hospital Universitario Donostia, Donostia, Gipuzkoa, Spain

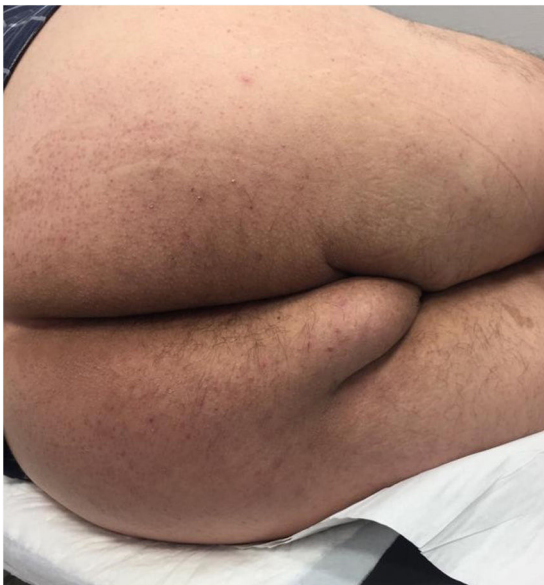

Figure 1

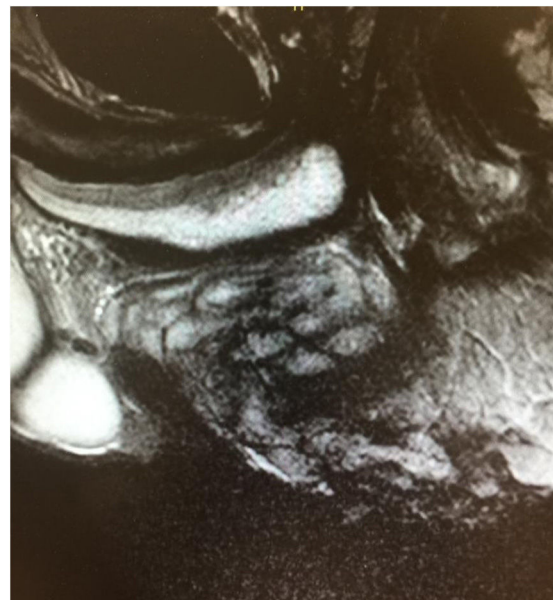


Figure 2

A 53-year-old male amateur cyclist presented with a large 10 cm perineal mass, which was soft and covered with healthy skin (third testicle, ischial hygroma or accessory testicle) (Fig. 1). This is an underdiagnosed condition that is characteristic of male cyclists, caused by continuous friction of the perineal soft tissue between the ischial tuberosity and the bicycle seat. It usually presents as one or more lateral or median raphe nodules.

On MRI (Fig. 2), alteration of the perineal fat was observed in the form of fibrous tracts that protruded towards the perineum. The treatment of choice is excision. This highlights the importance of clinical suspicion based on a correct anamnesis.

<sup>☆</sup> Please cite this article as: Pastor T, Placer C, Tubía J, Enríquez-Navascués JM. Proctología y medicina deportiva: el tercer testículo. Cir Esp. 2020;98:294.

<sup>\*</sup> Corresponding author.

E-mail address: [taniapastorbonel@gmail.com](mailto:taniapastorbonel@gmail.com) (T. Pastor).