



## Image of the month

## Gastric Outlet Obstruction Due to Duodenal Gallstone (Bouveret Syndrome)<sup>☆</sup>

### Obstrucción intestinal alta secundaria a cálculo impactado en duodeno (síndrome de Bouveret)

Tania Diaz Antonio,<sup>a,\*</sup> Guadalupe Dolores Garrido Ruiz,<sup>a</sup> Irene Mirón Fernández,<sup>b</sup> Laura Peñuela Ruiz<sup>a</sup>

<sup>a</sup> Servicio de Radiodiagnóstico, Hospital Universitario Virgen de la Victoria, Málaga, Spain

<sup>b</sup> Servicio de Cirugía General y del Aparato Digestivo y Trasplantes, Complejo Regional Universitario de Málaga, Málaga, Spain

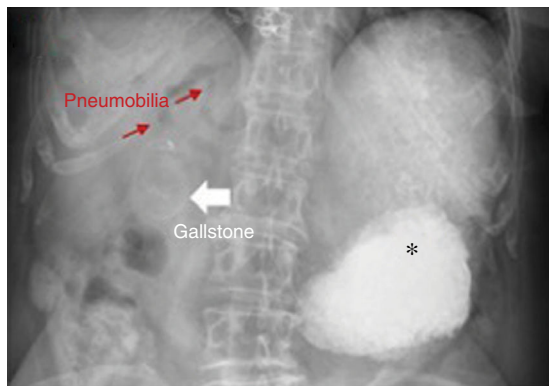

Fig. 1

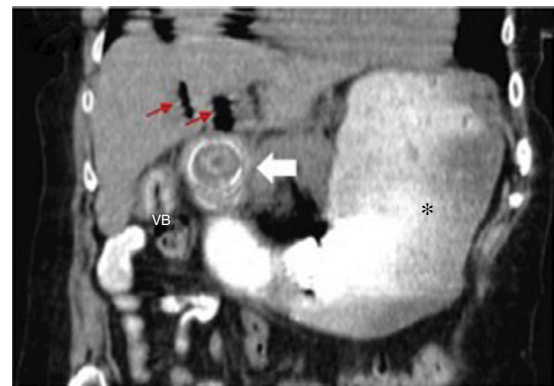


Fig. 2

A 78-year-old woman admitted in the emergency department due to epigastric pain and vomiting in the last week. As personal history, she underwent gallstone ileus surgery without cholecystectomy. Plain radiograph (Fig. 1) shows a large gastric dilatation with pneumobilia and gallstone in the right hypochondrium. CT (Fig. 2) confirmed the duodenal ectopic gallstone location as mechanical obstruction.

Bouveret syndrome is a rare form of gallstone ileus. Although endoscopy is the technique of choice, the role of surgery is highlighted as an alternative in cases of large or impacted stones. Diagnosis: gastric outlet obstruction due to duodenal gallstone (Bouveret syndrome).

### Acknowledgements

To the Surgery and Radiodiagnostic Services for their collaboration.

<sup>☆</sup> Please cite this article as: Diaz Antonio T, Garrido Ruiz GD, Mirón Fernández I, Peñuela Ruiz L. Obstrucción intestinal alta secundaria a cálculo impactado en duodeno (síndrome de Bouveret). Cir Esp. 2020;98:358.

\* Corresponding author.

E-mail address: [tdiazant@gmail.com](mailto:tdiazant@gmail.com) (T. Diaz Antonio).