



Image of the Month

Retroperitoneal Cystic Lymphangioma as an Incidental Finding in a Patient With Pancreatitis Symptoms[☆]

Linfangioma quístico retroperitoneal como hallazgo casual en un paciente con clínica de pancreatitis

Ana García-Vico,^{a,*} Jesús Cañete-Gómez,^a Ana Isabel Gómez-Sotelo,^a
Pablo Parra-Membrives^b

^a Servicio de Cirugía General y del Aparato Digestivo, Hospital Universitario de Valme, Sevilla, Spain

^b Unidad de Cirugía Hepatobiliar y Pancreática, Servicio de Cirugía General y del Aparato Digestivo, Hospital Universitario de Valme, Sevilla, Spain

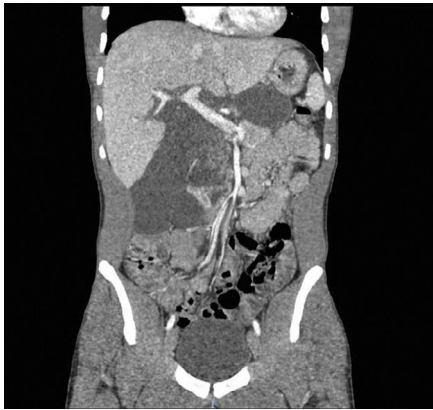

Fig. 1

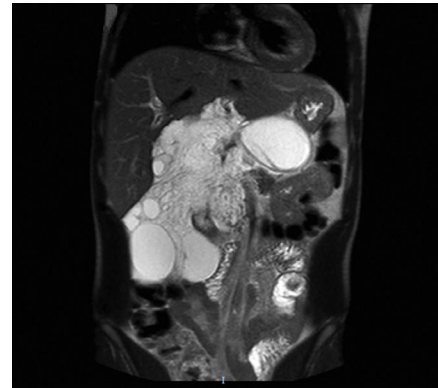


Fig. 2

A 23-year-old male patient came to the emergency department due to epigastric pain radiating to the back. Lab workup showed leukocytosis and elevated CRP. Abdominal CT scan revealed findings compatible with acute pancreatitis as well as retroperitoneal fluid collections, suggestive of retroperitoneal cystic lymphangioma (Fig. 1). The study was completed with pancreatic MRI, which confirmed the diagnosis (Fig. 2).

Retroperitoneal cystic lymphangioma is a benign disease that is rare in adults. In most cases, the presentation is asymptomatic. The current trend in treatment is the clinical follow-up of the patient given the high recurrence rate after surgery and the associated morbidity.

[☆] Please cite this article as: García-Vico A, Cañete-Gómez J, Gómez-Sotelo AI, Parra-Membrives P. Linfangioma quístico retroperitoneal como hallazgo casual en un paciente con clínica de pancreatitis. Cir Esp. 2019;97:594.

* Corresponding author.

E-mail address: anagarcivico91@gmail.com (A. García-Vico).