



Image of the month

Uncommon Anatomic Variation of the Pancreatic Duct: Ansa Pancreatica[☆]



Variación anatómica del conducto pancreático poco frecuente: ansa pancreática

Teresa Carrascosa-Mirón,^{a,*} Raquel León-Ledesma,^a Alba Manuel-Vázquez,^b Manuel Gorosabel-Calzada^a

^a Servicio de Cirugía General y Digestiva, Hospital Universitario de Getafe, Getafe, Madrid, Spain

^b Servicio de Cirugía General y Digestiva, Hospital Universitario de Guadalajara, Guadalajara, Spain

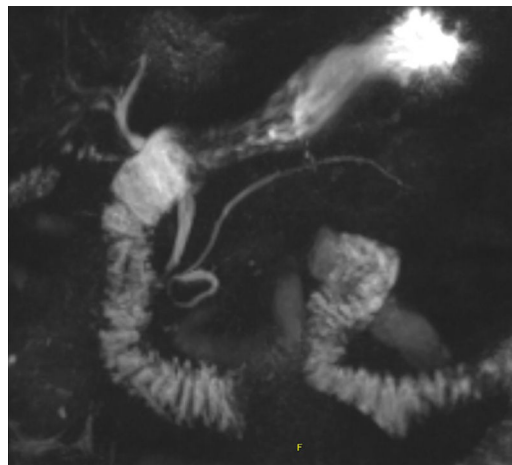


Fig. 1

A 70-year-old man with obstructive jaundice and *ansa pancreatica* as an incidental finding in magnetic resonance cholangiopancreatography (MRCP) as a variant of normality (Fig. 1).

The *ansa pancreatica* is the presence of an additional arcuate branch (loop) that connects the dorsal and ventral pancreatic ducts to each other, in the context of an obliteration of the accessory duct at the proximal level.

This anatomic variation is associated as a predisposing factor for acute pancreatitis; thus, this finding has a great clinical relevance.

Diagnosis might be performed by MRCP or by endoscopic retrograde cholangiopancreatography, which allows endoscopic treatment through sphincterotomy of the minor papilla.

[☆] Please cite this article as: Carrascosa-Mirón T, León-Ledesma R, Manuel-Vázquez A, Gorosabel-Calzada M. Variación anatómica del conducto pancreático poco frecuente: ansa pancreática. Cir Esp. 2020;98:236.

* Corresponding author.

E-mail address: t.carrascosa@hotmail.com (T. Carrascosa-Mirón).