



## Image of the month

## Massive Cervical Chylous Fistula After Left Cervical Dissection<sup>☆</sup>



### Linforragia cervical masiva tras vaciamiento cervical izquierdo

Paolo Cariati,\* Maria Roman Ramos, Jose Fernandez Solis, Ildefonso Martinez Lara

Servicio de Cirugía Oral y Maxilofacial, Hospital Universitario Virgen de las Nieves, Granada, Spain

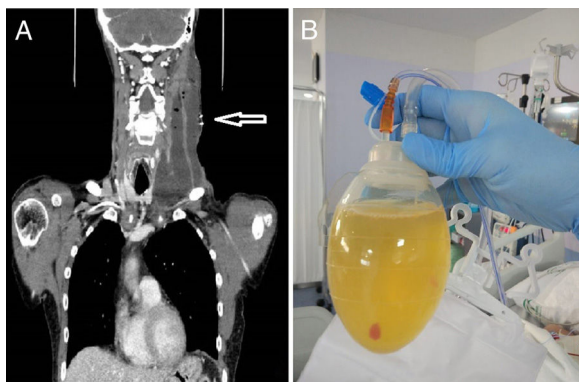


Fig. 1

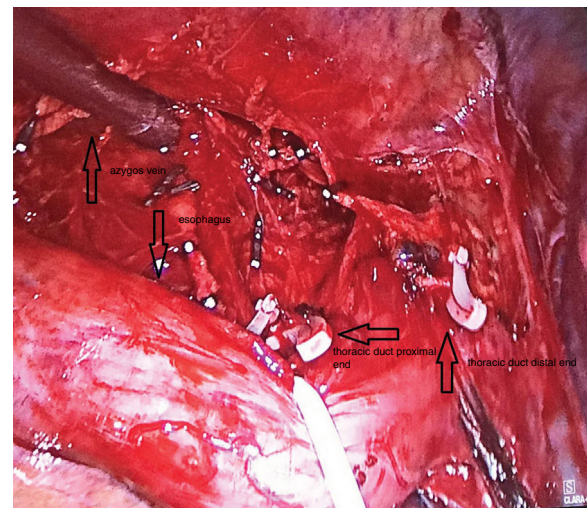


Fig. 2

59 years old male affected by tongue squamous cell carcinoma. The patient underwent tumorectomy and left selective neck dissection. On postoperative day 5, a chylous fistula developed in the left neck with large production (>1200 ml per day) of white and yellowish fluid through the cervical drainage (Fig. 1). The case was initially treated with conservative approach including low-fat diet with medium-chain triglycerides, total parenteral nutrition, drainage and use of somatostatin analogs. Unfortunately, conservative approach was not effective during 10 days. Hence, patient underwent thoracic duct ligation with thoracoscopic approach (Fig. 2). Chylous drainage completely stopped 4 days later. No other complications were observed during patient follow up.

<sup>☆</sup> Please cite this article as: Cariati P, Roman Ramos M, Fernandez Solis J, Martinez Lara I. Linforragia cervical masiva tras vaciamiento cervical izquierdo. Cir Esp. 2020;98:44.

\* Corresponding author.

E-mail address: [francocariati@hotmail.com](mailto:francocariati@hotmail.com) (P. Cariati).