



Image of the month

Ileocolic Intussusception in Adults[☆]

Intususcepción ileocólica en el adulto

Vanesa Crespo García del Castillo,^{*} Antonio José Morandeira Rivas,
Jerónimo Riquelme Gaona, Carlos Moreno Sanz

Servicio de Cirugía General y del Aparato Digestivo, Hospital General La Mancha Centro, Alcázar de San Juan, Ciudad Real, Spain

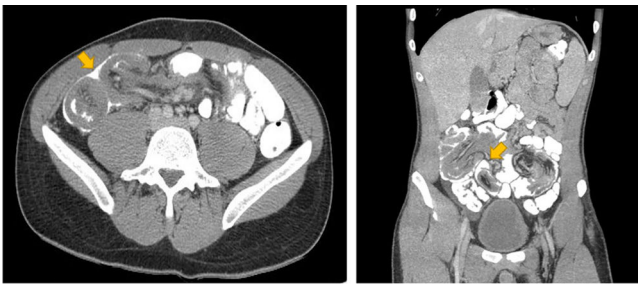

Fig. 1

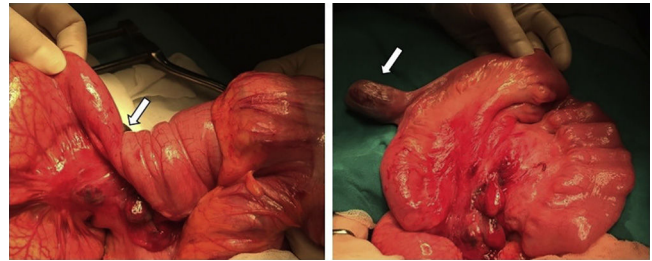


Fig. 2

A 20-year-old man consulted for abdominal pain and vomiting that had been progressing for several days. Physical examination detected pain in the mesogastrium. Ultrasound and computed tomography were performed (Fig. 1), which revealed an image compatible with ileocolic intussusception causing intestinal obstruction. Exploratory laparotomy discovered an ileocolic and ileo-ileal intussusception caused by a Meckel's diverticulum located 1 m from the ileocecal valve (Fig. 2). This invagination was corrected and the diverticulum was resected with a linear stapler. The patient progressed favorably after surgery, with no complications.

Diagnosis of the case: intestinal obstruction secondary to ileocolic and ileo-ileal intussusception caused by Meckel's diverticulum.

[☆] Please cite this article as: Crespo García del Castillo V, Morandeira Rivas AJ, Riquelme Gaona J, Moreno Sanz C. Intususcepción ileocólica en el adulto. Cir Esp. 2019;97:343.

^{*} Corresponding author.

E-mail address: vanesacrespo33@hotmail.com (V. Crespo García del Castillo).