



Image of the Month

Giant Cell Tumor of the Superior Maxilla[☆]

Tumor de células gigantes de maxilar superior

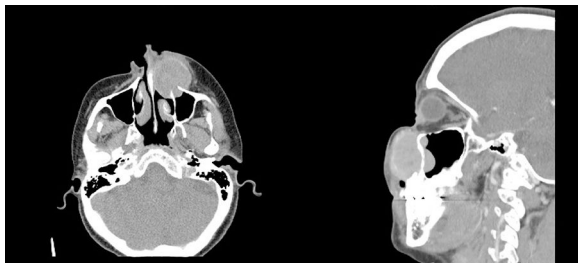
Jorge Luna-Abanto,^{a,b,*} Erick Gonzales Laguado^c^aDepartamento de Cirugía Oncológica, Instituto Nacional de Enfermedades Neoplásicas, Lima, Peru^bEscuela de Posgrado, Universidad Peruana Cayetano Heredia, Lima, Peru^cDepartamento de Cirugía de Cabeza y Cuello, Instituto Nacional de Enfermedades Neoplásicas, Lima, Peru

Fig. 1

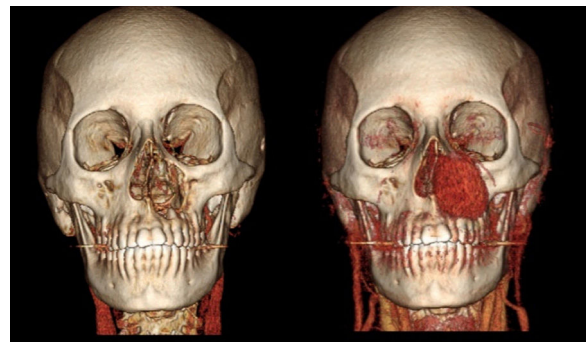


Fig. 2

A 37-year-old woman presented with a fast-growing mass in the left nasolabial region that had been developing over the previous 9 months. Computed tomography scan with contrast of the facial bones showed a solid, homogeneous lesion with partially defined margins, dependent on the left upper maxilla (Figs. 1 and 2).

Biopsy of the tumor identified the mass as a giant cell tumor (GCT). GCT of the bone are lesions characterized by the presence of multinucleated giant cells and represent 4% of all bone tumors. Only 2% originate in the craniofacial skeleton; maxillary tumors are exceptional. Standard treatment is surgical resection.

[☆] Please cite this article as: Luna-Abanto J, Gonzales Laguado E. Tumor de células gigantes de maxilar superior. Cir Esp. 2019;97:289.

* Corresponding author.

E-mail address: Jorgelunaabanto@gmail.com (J. Luna-Abanto).