



## Image of the month

## Jejuno-jejunal Invagination in a Patient With Intestinal Malrotation ☆



### Invaginación yeyuno-yeyunal en paciente con malrotación intestinal

Sagrario María Santos-Seoane, \* Ana María Alvarez-Suárez, Laura Sánchez-Suárez, Rosa Acebal-Berruete

Servicio de Medicina Interna, Hospital de Cabueñes, Gijón, Asturias, Spain

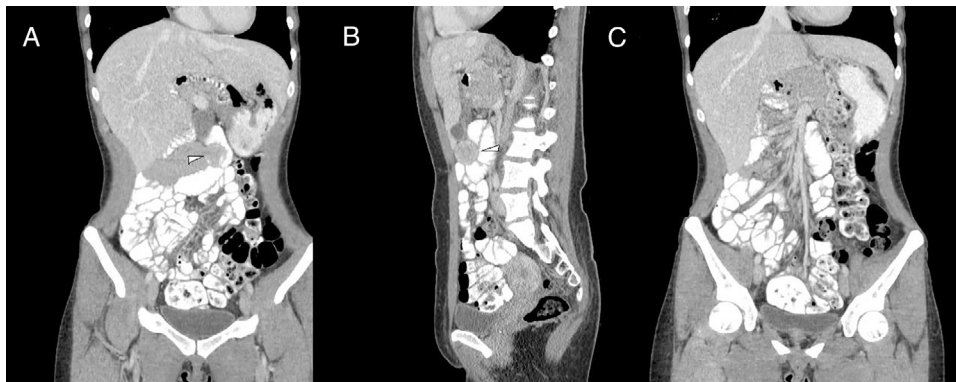


Fig. 1

A 24-year-old woman was admitted for abdominal pain that had been progressing for 72 h with associated nausea and vomiting, but no fever. Abdominal examination showed a diffuse painful abdomen, without clear peritonism. A CT scan of the mesogastrium revealed a doughnut-shaped segment of small intestine measuring about 7–8 cm, suggesting jejuno-jejunal intussusception (Fig. 1A and B, indicated by a white arrow). The CT scan also showed intestinal malrotation with the right colon located in a centralized position within the abdominal cavity, the left colon and the cecum in the pelvic location, and the small intestinal loops to the right (Fig. 1C). The patient progressed satisfactorily with conservative treatment.

Diagnosis: jejuno-jejunal invagination in a patient with intestinal malrotation.

☆ Please cite this article as: Santos-Seoane SM, Alvarez-Suárez AM, Sánchez-Suárez L, Acebal-Berruete R. Invaginación yeyuno-yeyunal en paciente con malrotación intestinal. Cir Esp. 2019;97:175.

\* Corresponding author.

E-mail address: smsspulp@yahoo.es (S.M. Santos-Seoane).