



## Innovation in Surgical Technique

# Use of Alexis Retractor in Thyroid and Parathyroid Surgery<sup>☆</sup>

Yolanda Lois-Ortega,<sup>a,\*</sup> Fernando García-Curdi,<sup>b</sup> Simón Brotons-Durbán,<sup>c</sup>  
Juan Bosco Vendrell-Marqués<sup>c</sup>

<sup>a</sup> Servicio de Otorrinolaringología, Hospital Ernest Lluch Martín, Calatayud (Zaragoza), Spain

<sup>b</sup> Servicio de Otorrinolaringología, Hospital Clínico Universitario Lozano Blesa, Zaragoza, Spain

<sup>c</sup> Servicio de Otorrinolaringología, Fundación Instituto Valenciano de Oncología, Valencia, Spain

### ARTICLE INFO

#### Article history:

Received 25 May 2018

Accepted 18 June 2018

Available online 13 December 2018

#### Keywords:

Alexis ring retractor

Thyroidectomy

Retractor

Traction

#### Palabras clave:

Anillo retractor Alexis

Tiroidectomía

Retractor

Tracción

### ABSTRACT

In thyroid and parathyroid surgical procedures, good visibility of the thyroid gland is essential. This is traditionally achieved by means of traction sutures of the dermo-plas-tysmal flaps to the drapes of the operative field, producing tension and even damage to the skin. The Alexis<sup>®</sup> retractor ring improves exposure and facilitates stable access to the thyroid, protecting the skin from injury during the intervention.

© 2018 AEC. Published by Elsevier España, S.L.U. All rights reserved.

### Uso de retractor Alexis en cirugía de tiroides y paratiroides

#### RESUMEN

En los procedimientos quirúrgicos de tiroides y paratiroides es indispensable una buena exposición de la glándula tiroidea, lo cual se realiza habitualmente mediante suturas de tracción de los colgajos dermoplastismales a los paños del campo operatorio, lo que produce tensión e incluso daños en la piel. El anillo retractor Alexis<sup>®</sup> mejora la exposición y facilita el acceso a la celda tiroidea de forma estable, protegiendo la piel de lesiones durante la intervención.

© 2018 AEC. Publicado por Elsevier España, S.L.U. Todos los derechos reservados.

<sup>☆</sup> Please cite this article as: Lois-Ortega Y, García-Curdi F, Brotons-Durbán S, Vendrell-Marqués JB. Uso de retractor Alexis en cirugía de tiroides y paratiroides. Cir Esp. 2019;97:46–49.

\* Corresponding author.

E-mail address: yloisortega@gmail.com (Y. Lois-Ortega).

## Introduction

Thyroid and parathyroid surgery requires good exposure of the glands, for which an incision must be made to provide access to the superior and inferior thyroid poles.<sup>1</sup> Meanwhile, the incision should be as small as possible so that the scar is not unsightly in such a visible body area and, in certain cultures, a mark in this area can be a social stigma.

Exposure of the gland during thyroidectomy can be maintained with different methods. One of the most frequently used techniques is the fixation of the upper and lower flaps to the operative field with silk sutures, which can leave marks on the skin of the chin. Another common method is the use of an automatic separator between the two flaps.<sup>2</sup>

The Alexis<sup>®</sup> retractor (Alexis<sup>®</sup> O Wound Retractor/Protector, Applied Medical Technology, Modesto, CA, USA) is a device designed to provide stable atraumatic exposure, while protecting the flap skin from damage during surgery.<sup>3</sup> The device is widely used in different surgical specialties for a multitude of procedures, especially in abdominal, pelvic, thoracic and urological surgery.<sup>3,4</sup> Our hospital has recently begun performing thyroid and parathyroid surgery using this device.

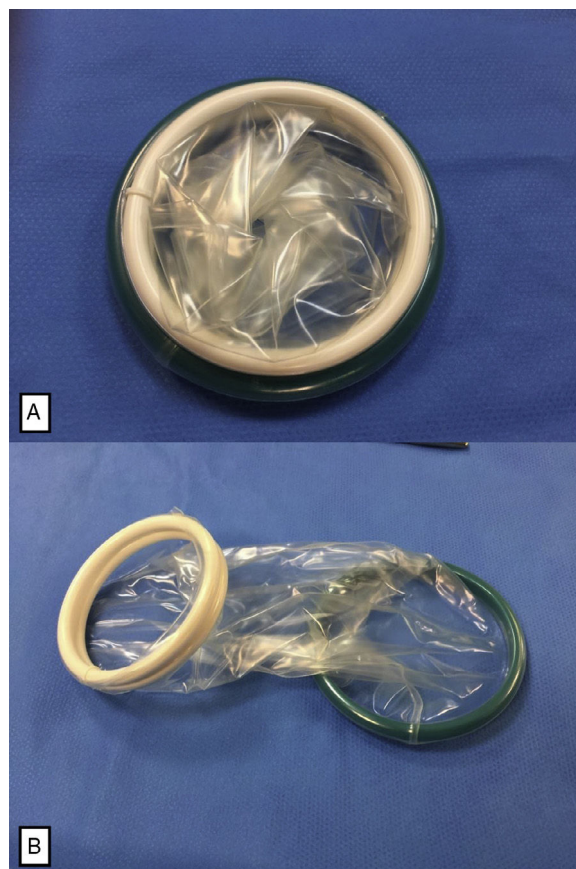
## Technique

The different steps in the procedure are similar to conventional thyroid surgery, except in the manner of maintaining field exposure. A 4–5 cm transverse incision is made, depending on the size of the thyroid and the condition being treated, involving the skin, the subcutaneous cellular tissue and the platysma.

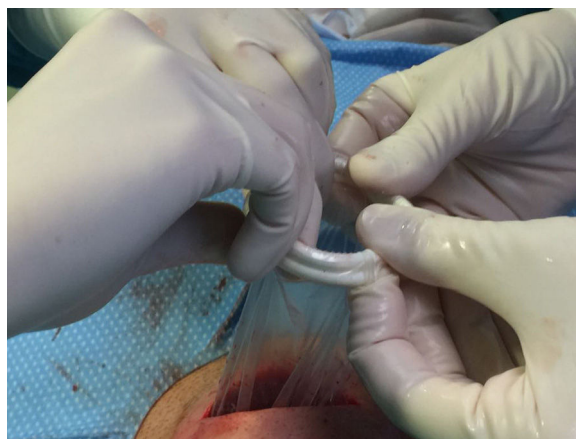
After releasing the subplatysmal flap above, below and laterally, the Alexis<sup>®</sup> retractor is positioned, which consists of 2 semi-rigid rings joined by a flexible polymer membrane (Fig. 1). From among the different ring diameter sizes, the manufacturer recommends size “XS” (4 cm in diameter) in thyroid surgery, requiring a minimal incision, although operations for large goiters may require size “S” (6 cm in diameter). The green ring is inserted under the flap and the white ring is rolled over the membrane until the 2 rings are adjacent<sup>5</sup> (Fig. 2). Once in position, static circumferential vision is achieved, providing good access to both thyroid lobes (Fig. 3). Its placement does not prevent the use of instruments by the assistant, such as Farabeuf, Mathieu or Langenbeck separators to improve access in certain areas.

After placement of the retractor, the infrahyoid muscles are separated to access the thyroid gland. Thereafter, the surgical times depend on the type of procedure performed. In our hospital, the device has been used in lobectomies, total thyroidectomies and parathyroid surgery (Fig. 4).

After performing the corresponding surgical procedure and hemostasis of the surgical bed, the Alexis<sup>®</sup> retractor is removed by pulling the inner ring. One or two Jost-Redon drain tubes are inserted, the strap muscles are approximated and the incision is sutured.



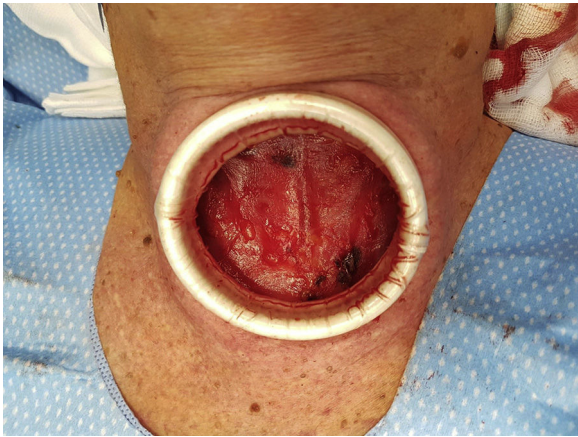
**Fig. 1 – (A) Alexis<sup>®</sup> retractor device, size XS (4 cm in diameter), comprised of 2 flexible rings joined by a polymer membrane; (B) Alexis<sup>®</sup> retractor device, unrolled before placement.**



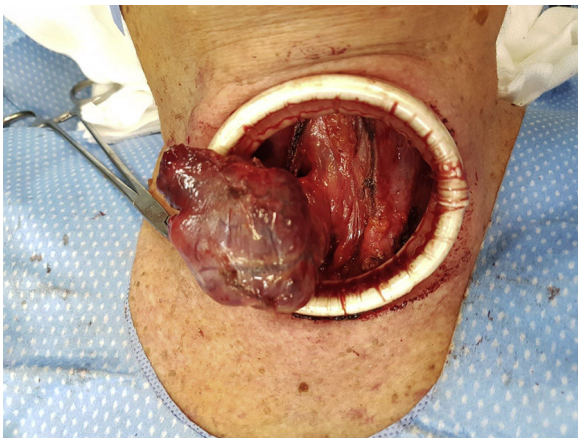
**Fig. 2 – Placement of the Alexis<sup>®</sup> retractor device in the surgical field, rolling it over the plastic membrane.**

## Discussion

Although recent studies have been published about the use of the Alexis<sup>®</sup> retractor in surgical procedures of the head and neck, such as oral and maxillofacial surgery,<sup>6</sup> transoral



**Fig. 3 – Alexis® retractor placed in the incision, exposing the superficial cervical fascia and infrahyoid muscles.**



**Fig. 4 – Photograph during right lobectomy showing the right hemithyroid connected to the isthmus.**

robotic surgery<sup>7</sup> and orbital surgery,<sup>4</sup> there are no reports in the literature describing the use of this device in thyroid surgery.

In a period of 2 months, a total of 13 interventions were performed in patients with thyroid or parathyroid disease using the Alexis® retractor device, specifically in 11 women and 2 men, aged between 43 and 68 years. In 12 of the interventions, the “XS” size retractor was used: 4 total thyroidectomies (2 for multinodular goiter and 2 for papillary carcinoma); 6 lobectomies for multinodular goiter; and 2 parathyroidectomies for parathyroid adenomas. Total thyroidectomy was performed with an “S” size retractor in a large goiter.

The authors consider that this technique offers some advantages over traction sutures. The main ones are the

greater visibility and easier illumination of the thyroid gland and better access to the superior thyroid pedicles, avoiding the need to extend the incision on certain occasions. Insertion of the device is easy and fast, and the homogenous tension created favors hemostasis of the skin, which maintains its moisture<sup>3</sup> and protects it from possible burns or tears during the intervention. Its use also avoids skin damage caused by the tension of traditional traction sutures.<sup>5</sup> It does not interfere with the use of instruments and reduces the need for the assistant to use handheld separators; however, when these are used, direct traction on the skin is also avoided.<sup>4</sup> The device is removed by simply pulling the inner ring.

The device has been demonstrated to reduce surgical site infection rates in gastrointestinal surgery by protecting the wound from contamination by intestinal bacteria.<sup>8,9</sup> Surgical site infection in thyroid surgery is very rare, so it offers no advantages for these procedures. None of the cases in which the Alexis® retractor has been used have presented surgical wound infections, or any other type of postoperative complication related to the use of the device.

In conclusion, the authors have found that the Alexis® retractor ring allows the tissue to be exposed in thyroid and parathyroid surgery with a minimal incision in a quick, simple and static manner. The device improves visibility compared to other methods, while facilitating hemostasis and protecting the skin from traction injuries, so the authors recommend its use in this type of procedure.

### Conflict of Interests

The authors have no conflict of interests to declare.

### REFERENCES

1. Miller FR. Surgical anatomy of the thyroid and parathyroid glands. *Otolaryngol Clin North Am.* 2003;36:1-7.
2. Bliss RD, Gauger PG, Delbridge LW. Surgeon's approach to the thyroid gland: Surgical anatomy and the importance of technique. *World J Surg.* 2000;24:891-7.
3. Alexis retractor [Internet]. Applied medical; 2018. Recovered from: <http://www.appliedmedical.com/Products/Alexis/OWoundProtectorRetractor>
4. Wong Y, Lee P, Sullivan T. Utilising the Alexis retractor for lateral orbital access, a case series. *Orbit.* 2018;8:1-3. <http://dx.doi.org/10.1080/01676830.2017.1423361> [Epub ahead of print].
5. Rutledge A, Carroll G, Smith S, Gani J. How to do it: use of the Alexis wound protector as a laparostomy device. *ANZ J Surg.* 2017;87:732-3. <http://dx.doi.org/10.1111/ans.14097> [Epub 2017 Jul 5].
6. Mubeen S, Mubeen S, Falconer D. Use of the Alexis ring retractor in oral and maxillofacial surgery. *Br J Oral Maxillofac Surg.* 2014;52:470-2. <http://dx.doi.org/10.1016/j.bjoms.2014.03.002> [Epub 2014 Mar 27].
7. Perenyi M, Dobbs TD, Fraser LR, Winter SC. Use of the self-retaining Alexis ring retractor in transoral robotic surgery. *Head Neck.* 2017;39:2132-4. <http://dx.doi.org/10.1002/hed.24882> [Epub 2017 Jul 24].

- 
8. Gomes Ferreira C, Lacreuse I, Geslin D, Schmitt F, Schneider A, Podevin G, et al. Staged gastroschisis closure using Alexis wound retractor: first experiences. *Pediatr Surg Int*. 2014;30:305-11. <http://dx.doi.org/10.1007/s00383-013-3440-3> [Epub 2013 Dec 12].
  9. Cheng KP, Roslani AC, Sehha N, Kueh JH, Law CW, Chong HY, et al. ALEXIS O-Ring wound retractor vs conventional wound protection for the prevention of surgical site infections in colorectal resections. *Colorectal Dis*. 2012;14:e346-51. <http://dx.doi.org/10.1111/j.1463-1318.2012.02943.x>.