



# CIRUGÍA ESPAÑOLA

[www.elsevier.es/cirugia](http://www.elsevier.es/cirugia)



## Image of the month

### Hydatid Cyst Causing Pancoast Syndrome: A Rare Settlement<sup>☆</sup>



### El quiste hidatídico como causa del síndrome de Pancoast: extraña asociación

Kutsi Tunce,<sup>a</sup> Yener Aydin,<sup>b,\*</sup> Hayri Ogul,<sup>c</sup> Atilla Eroglu<sup>b</sup>

<sup>a</sup> Department of Orthopedics and Traumatology, Ataturk University, Erzurum, Turkey

<sup>b</sup> Department of Thoracic Surgery, Ataturk University, Erzurum, Turkey

<sup>c</sup> Department of Radiology, Ataturk University, Erzurum, Turkey

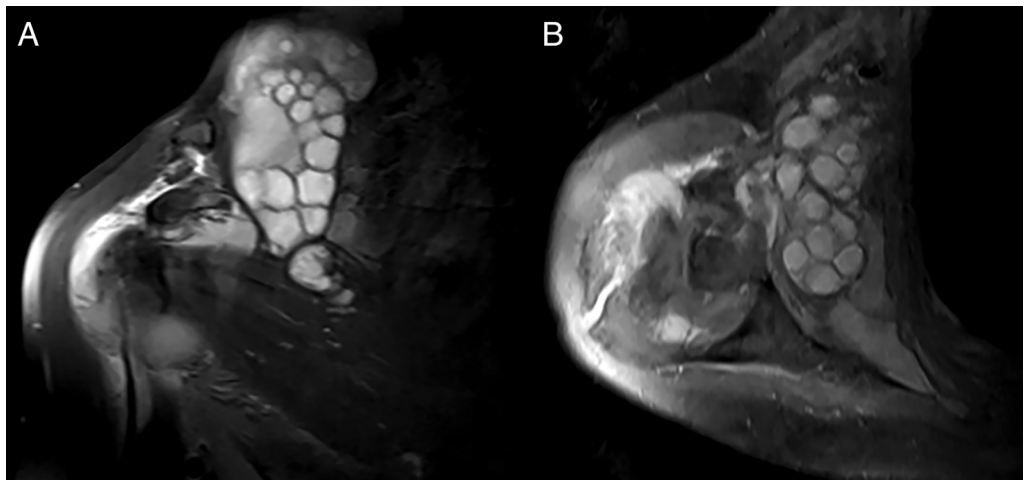


Figure 1

A 76-year-old female presented with severe pain in the neck and right shoulder. However, she had no findings of Horner syndrome and recurrent laryngeal nerve compression. MR images show a hyperintense multicystic lesion with multiple daughter cysts in the superolateral side of the right hemithorax (Fig. 1A, B). The patient's symptoms improved postoperatively. Hydatid cyst is most commonly located in the liver and lung. However, it may occur at any site of the body. The current image is presented as a reminder that hydatid cyst should be kept in mind especially in patients who are shoulder pain.

<sup>☆</sup> Please cite this article as: Tunce K, Aydin Y, Ogul H, Eroglu A. El quiste hidatídico como causa del síndrome de Pancoast: extraña asociación. Cir Esp. 2018;96:655.

\* Corresponding author.

E-mail address: [dryeneraydin@hotmail.com](mailto:dryeneraydin@hotmail.com) (Y. Aydin).