



Image of the month

Postraumatic Pseudoaneurysm of the Axillary Artery Presenting as an Axillary Tumor[☆]



Seudoaneurisma postraumático de arteria axilar presentado como tumoración axilar

Emiliano Cano-Trigueros,^{a,b,*} Romina Díaz-Serrano^a

^a Servicio de Angiología y Cirugía Vascular, Hospital Universitario Morales Meseguer, Murcia, Spain

^b Facultad de Medicina, Universidad de Murcia, Murcia, Spain

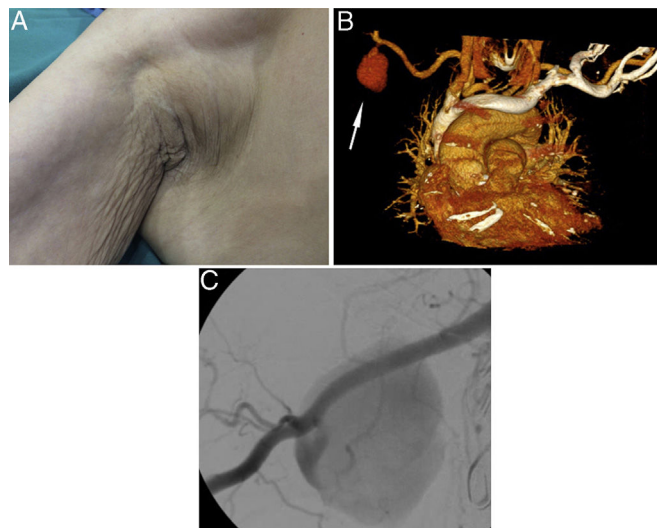


Figure 1

An 82-year-old male reported a fall and axillary contusion with a walking aid (crutch) that he carried. He described a right axillary tumor (Fig. 1A) as well as functional loss of the right hand. Physical examination demonstrated a pulsating axillary mass and sensorimotor paralysis of the radial, median and ulnar nerves. CT angiography and intraoperative angiography showed a 43 mm right axillary artery pseudoaneurysm (Fig. 1B-arrow and C). A coated stent was implanted, and the residual hematoma was drained to decompress the plexus. Post-traumatic pseudoaneurysm of the axillary artery is a very rare entity that is usually caused due to fractures and dislocations of the glenohumeral joint.

Diagnosis: post-traumatic pseudoaneurysm of the right axillary artery.

[☆] Please cite this article as: Cano-Trigueros E, Díaz-Serrano R. Seudoaneurisma postraumático de arteria axilar presentado como tumoración axilar. Cir Esp. 2018;96:451.

* Corresponding author.

E-mail address: emilianocanotrigueros@gmail.com (E. Cano-Trigueros).