

## Review article

# Approach and Management of Traumatic Retroperitoneal Injuries<sup>☆</sup>

Patrizio Petrone,<sup>a,b,\*</sup> Cristina Magadán Álvarez,<sup>a</sup> D'Andrea Joseph,<sup>a</sup> Lee Cartagena,<sup>a</sup> Fahd Ali,<sup>a</sup> Collin E.M. Brathwaite<sup>a</sup>

<sup>a</sup> Department of Surgery, NYU Winthrop Hospital, Mineola, Long Island, New York, United States

<sup>b</sup> Universidad de Las Palmas de Gran Canaria, Canary Islands, Spain

## ARTICLE INFO

## Article history:

Received 12 December 2017

Accepted 27 February 2018

Available online 18 May 2018

## Keywords:

Retroperitoneum

Trauma

Prevalence

Injuries

Diagnosis

Management

Treatment

## A B S T R A C T

Traumatic retroperitoneal injuries constitute a challenge for trauma surgeons. They usually occur in the context of a trauma patient with multiple associated injuries, in whom invasive procedures have an important role in the diagnosis of these injuries. The retroperitoneum is the anatomical region with the highest mortality rates, therefore early diagnosis and treatment of these lesions acquire special relevance. The aim of this study is to present current published scientific evidence regarding incidence, mechanism of injury, diagnostic methods and treatment through a review of the international literature from the last 70 years. In conclusion, this systematic review showed an increasing trend toward non-surgical management of retroperitoneal injuries.

© 2018 AEC. Published by Elsevier España, S.L.U. All rights reserved.

## Abordaje y manejo de las lesiones retroperitoneales traumáticas

## R E S U M E N

Las lesiones traumáticas retroperitoneales constituyen un desafío para el cirujano de traumatología. Ocurren generalmente en el contexto de un paciente politraumatizado, con múltiples lesiones asociadas y en el que los procedimientos invasivos tienen un rol preponderante en el diagnóstico de estas lesiones. El retroperitoneo es la región anatómica que presenta mayores tasas de mortalidad, por lo que el diagnóstico precoz y tratamiento de estas lesiones adquiere especial relevancia. El objetivo de este trabajo es presentar la

## Palabras clave:

Retroperitoneo

Traumatismo

Prevalencia

Lesiones

Diagnóstico

<sup>☆</sup> Please cite this article as: Petrone P, Magadán Álvarez C, Joseph D, Cartagena L, Ali F, Brathwaite CEM. Abordaje y manejo de las lesiones retroperitoneales traumáticas. Cir Esp. 2018;96:250-259.

\* Corresponding author.

E-mail addresses: [patrizio.petrone@gmail.com](mailto:patrizio.petrone@gmail.com), [ppetrone@nyuwinthrop.org](mailto:ppetrone@nyuwinthrop.org) (P. Petrone).

Manejo  
Tratamiento

evidencia científica publicada hasta el momento en cuanto a su prevalencia, mecanismo lesional, métodos diagnósticos y tratamiento mediante una revisión de la literatura internacional de los últimos 70 años. Como conclusión, en esta revisión sistemática se pone de manifiesto una creciente tendencia al manejo no quirúrgico de las lesiones que afectan el retroperitoneo.

© 2018 AEC. Publicado por Elsevier España, S.L.U. Todos los derechos reservados.

## Introduction

Abdominal trauma, both blunt and penetrating, occurs with a frequency of approximately 10% in torso trauma cases.<sup>1</sup> The mechanism of injury varies depending on the country, socioeconomic status and culture. This trauma type is one of the main causes of morbidity and mortality in any age group. Trauma in the retroperitoneal compartment has the highest mortality rates.<sup>1</sup> Considering its complex anatomy, the management of retroperitoneal injuries can vary widely (Fig. 1).<sup>2</sup> The objective of this study is to carry out a review of the literature about retroperitoneal injuries, with an emphasis on their prevalence, diagnosis and management.

## Methods

A systematic review of the literature was performed using the SCOPUS database under the criteria established by the reviewers, performing specific searches by organs using the following keywords: *abdominal aorta, inferior vena cava, duodenum, pancreas, renal vessels, kidney, adrenal glands, ureters, and iliac vessels, associated with trauma*. All publications in English and Spanish were included. Subsequently, a manual review was conducted

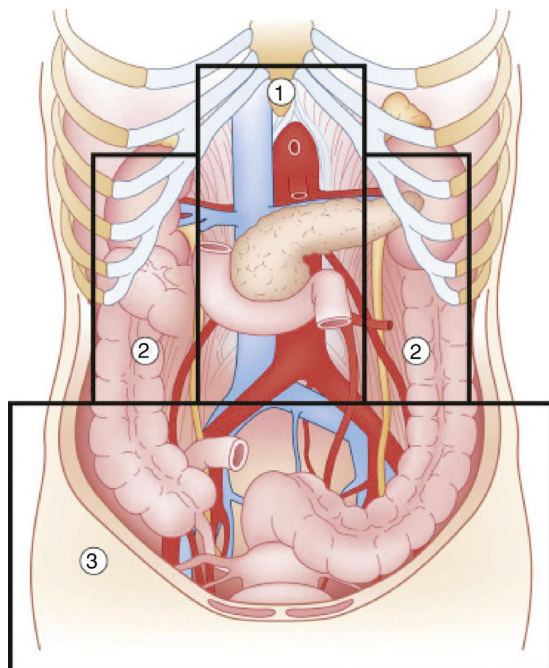


Fig. 1 – Diagram of the retroperitoneal zones (source: Martin et al.<sup>2</sup>).

from 1960 to date, excluding publications that did not refer to humans, clinical case reports or reviews of the literature, non-trauma mechanisms of injury and pediatric patients (Fig. 2).

## Prevalence

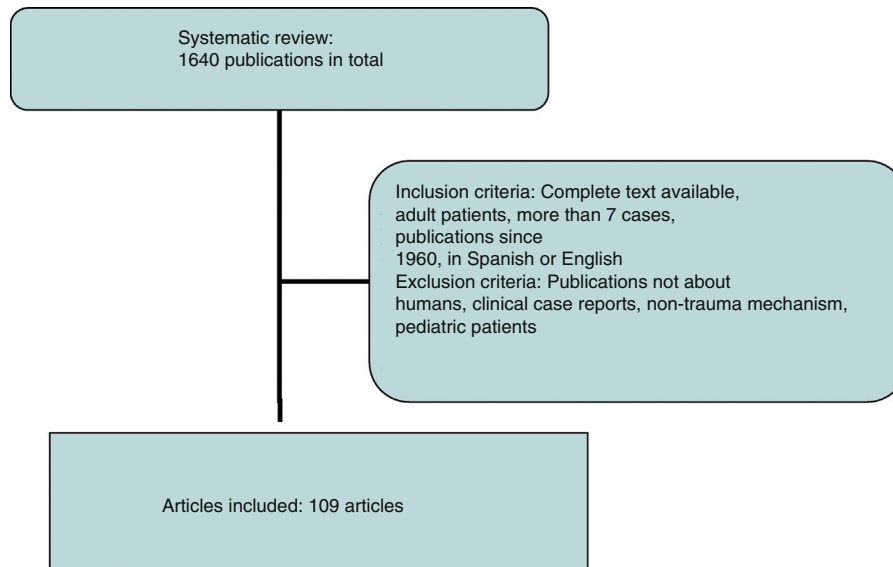
The incidence of retroperitoneal involvement in the literature is variable. In a study<sup>1</sup> conducted on more than 6000 patients admitted to a specialized unit, 15% had abdominal involvement, 15% of which involved the retroperitoneum. Similarly, an incidence of 12%<sup>3</sup> was reported in blunt abdominal trauma in hemodynamically stable patients by computerized axial tomography (CT). The kidney has been described as the most frequently affected retroperitoneal organ (18%), followed by the pancreas (3.7%) and the aorta (1%), with a predominance of blunt trauma over penetrating.<sup>1</sup>

While demonstrating a variable incidence, the abdominal organs most frequently affected by penetrating trauma are the liver and colon, followed by vascular injuries and the pancreas.<sup>4</sup>

### Zone 1

Zone 1, or the central zone, is delimited by the diaphragm above and reaches the aortic bifurcation below. It includes the aorta, the origin of the large vessels, the duodenum and the pancreas. Blunt trauma to this region affects the duodenum and the pancreas to a greater extent, with vascular lesions being less frequent. Most of the series analyzed report a duodenal injury rate that does not exceed 12%.<sup>4-9</sup> Pancreatic injuries have an incidence that ranges between 1% and 12% of penetrating trauma, and 5% of blunt trauma.<sup>10</sup> Mortality ranges from 10% to 46%, with ductal damage being an important predictor of morbidity and mortality.<sup>10</sup> Regarding the mortality due to duodenal injury, some series report ranges from 15% to 47%, which increases to 67% with seven or more associated organs injured.<sup>4</sup> The most frequent complication is duodenal fistula or dehiscence.

Among the vascular lesions, inferior vena cava injury stands apart, representing 30%–40% of abdominal vascular injuries. Their overall mortality rate varies from 34% to 70%, and factors for morbidity and mortality include both the level of the injury and the existence of active bleeding or other associated lesions.<sup>11</sup> Mortality due to suprahepatic and retrohepatic lesions varies between 78% and 100%, while adrenal injury mortality ranges from 33% to 66% versus 25% mortality in infrarenal vein cava involvement.<sup>11,12</sup> Prehospital mortality rates are reported to range from 30% to 50%, and these figures are maintained after hospital admission.<sup>12</sup> Abdominal aorta injuries are around 0.2%,<sup>13</sup> and its high immediate mortality rate is the second most common cause of



**Fig. 2 – Inclusion and exclusion criteria for the selection of articles.**

death in blunt trauma injuries. It is estimated that 80% of patients die before hospital care, and between 50% and 78% do so after.<sup>14,15</sup>

### Zones 2

Zones 2, or the lateral zones, are the areas between the diaphragm and the aortic bifurcation, delimited medially by the renal vessels and laterally with Toldt's fascia, so they therefore encompass the adrenal glands, kidneys, renal vessels, ureters, and a portion of ascending and descending colon.

The incidence of renal injuries stands out in this anatomical region at approximately 1.2%.<sup>16</sup> Few urological lesions are life threatening, although they represent some of the most frequent complications. However, adrenal injuries have a lower incidence, situated at around 0.4%.<sup>17</sup> Renal vascular damage, on the other hand, occurs in less than 5% of blunt traumas. Mortality associated with renal trauma is between 5%<sup>18</sup> and 11%,<sup>16</sup> while the mortality rate secondary to arterial injuries reaches 20% in some series.<sup>19</sup> Mortality associated with the adrenal gland is very variable, ranging from 8%<sup>20</sup> to 32%. It is noteworthy that the mortality rate associated with unilateral injury is 0% in certain studies.<sup>17,21</sup>

### Zone 3

Zone 3, or the pelvic zone, is delimited by the aortic bifurcation above. It includes the iliac vessels, distal ureters, distal sigmoid colon and the rectum.

The incidence of iliac vessel injuries is less than 1%. Specifically, they represent between 2% and 6.5% of vascular lesions.<sup>22</sup> The associated mortality ranges between 25% and 42%, although in some series this figure can reach 62%, presenting higher mortality rates in penetrating trauma injuries. Within this group, mortality increases in combined arterial and venous injuries (43%–62%) versus isolated venous injuries (6%–45%).<sup>22,23</sup>

## Mechanism of Injury

### Zone 1

According to the data obtained from the review of the literature, penetrating trauma is most frequently associated with aortic injuries. The most frequently associated vascular lesions affect the inferior vena cava, and only 2% of the cases present isolated vascular injury.<sup>15</sup> The most common aortic injury is intimal disruption, which may be partial or involve the entire aortic circumference, and may associate thrombosis and/or dissection. If the complete thickness is affected, this may lead to the formation of an aneurysm or rupture and subsequent death by exsanguination. The infrarenal aorta represents 50% of cases, however, this region has the lowest mortality rates.<sup>15</sup> In the same way, vena cava injuries occur in more than 80% of cases with penetrating trauma, and gunshot wounds are the main mechanism.<sup>12</sup> The adrenal region is the most frequently affected, while in blunt trauma there is an increase of retrohepatic lesions.<sup>11</sup>

In the review of 13 published series, the most frequent mechanism of duodenal injury was penetrating, with 1550 cases (90.7%) out of a total of 1709 patients.<sup>4-9,24-30</sup> The data reveal the higher incidence of firearm injuries over knife wounds. In blunt duodenal trauma, there is an increased association with pancreatic lesions, with fewer hepatic and colic injuries.<sup>25</sup> Within this group, there is a predominance of traffic accidents over falls. Underlying these lesions is the shear force mechanism between fixed and mobile portions, as well as compressive forces against the spinal column.<sup>31</sup> Penetrating pancreas trauma occurs in an isolated manner in 11% of cases. The second duodenal portion is the most frequently affected, with a variable incidence of 35%–62.5%, followed by the 3rd and 4th portion (12%–28%), with the first duodenal portion being the least affected.<sup>5-8,25,28,30,31</sup> The most common pancreatic injury affects the body and tail versus the

head and neck of the gland. The American Association for the Surgery of Trauma proposes a classification according to 5 degrees of duodenal and pancreatic injury.<sup>32</sup>

### Zones 2

In the United States, between 80% and 95% of renal trauma occur due to traffic accidents, falls or assaults.<sup>18</sup> In all the analyzed series, the rate of penetrating injuries is lower, with the proportion of injuries by gunshot versus stab wounds being variable. The most frequent is the presence of contusions, followed by lacerations, renal ruptures and vascular pedicle injuries. In adrenal lesions, theoretically there is an increase in the inferior vena cava pressure, which would explain the predominance of right-sided injuries.<sup>17,20,33-36</sup> Other mechanisms described are deceleration, affecting the adrenal arterioles, and crushing between the spinal column and neighboring organs, which is associated with a greater probability of associated ipsilateral lesions.<sup>20,37</sup> Ureteral injuries are uncommon, accounting for only 17% of penetrating urological trauma, and the blunt mechanism is a rare cause of injury.<sup>38</sup>

### Zone 3

Penetrating trauma is the main cause of injury, with isolated venous injury being the most common (41%),<sup>22</sup> followed by isolated arterial injury (33%) versus the combination of both (25.5%). In 73% of blunt trauma, there is an association with pelvic fractures, which increases the probability of genitourinary and intestinal injuries. The reported incidence of vascular injury is 3.5% in complex pelvic fractures, which increases to 7% in severe fractures.<sup>39</sup> Table 1 shows the most frequently affected organs according to the mechanisms of injury and age ranges.

## Diagnosis

The retroperitoneal location helps unmask the early clinical signs found in the diagnosis of the usual injuries.<sup>31</sup> Some of the most frequent symptoms are pain and abdominal distension, although up to 8% of patients remain asymptomatic.<sup>130</sup> Both peritoneal aspiration and focused abdominal ultrasound (Focused Abdominal Sonography for Trauma) can be positive, although they may give both false negatives and false positives.<sup>25,26</sup> In hemodynamically stable patients, the use

of CT with oral and intravenous contrast stands out, with high sensitivity and specificity, although in 40% of cases of early pancreatic trauma this test may be normal.

Since most duodenal injuries occur in the context of penetrating trauma, their diagnosis is made during exploratory laparotomy. The findings that suggest duodenal injury are the presence of bile, crepitations in the duodenal fascia and the presence of retroperitoneal or perirenal hematoma<sup>31</sup> as well as necrosis of peritoneal fat and peripancreatic edema.<sup>30,130</sup> These latter findings are also related to ductal pancreatic lesions together with the presence of transparent fluid in the bed. Additionally, in the diagnosis of vascular injuries, there may be the presence of a pulsatile mass, reduction in or absence of femoral pulses, coldness, cyanosis or weakness of the lower extremities.<sup>13</sup> Neurological symptoms are described in around 70% of patients presenting aortic injury, and shock rates of up to 82% in the largest published series.<sup>15</sup>

The presence of both macro- and microscopic hematuria varies between 66%<sup>39</sup> and 96% of patients according to some series, although other indirect signs may be noted, such as pain in the affected flank or signs of hemodynamic instability. When renal injury is suspected, the most widely used diagnostic method in hemodynamically stable patients is CT with intravenous contrast, which provides for classification of the lesions and rules out contrast extravasation.<sup>129</sup> This not only demonstrates active hemorrhage but is also related to greater kinetic energy and therefore is an indicator of the severity of the associated injuries.<sup>20</sup> In adrenal injuries, the most frequent finding is an oval hematoma measuring 2-3 cm,<sup>37</sup> and they present more than 90% of associated injuries. In addition to the use of CT and angiography, the use of urethrography is recommended in the presence of perineal hematomas or pelvic ring disruptions.

## Treatment

The initial assessment and management of patients presenting with abdominal trauma are based on the indications established by the Advanced Trauma Life Support (ATLS<sup>®</sup>) guidelines of the American College of Surgeons. The initial objective of surgical management is based on 3 points: controlling the site of the hemorrhage, controlling gastrointestinal contamination and reviewing the abdominal cavity for diagnostic purposes.

**Table 1 – Organs Affected According to the Mechanism of Injury.**

Organ (n)	Mechanism	
	Penetrating, n (%)	Blunt, n (%)
Kidney (18 581) <sup>77-104</sup>	2967 (16)	15 614 (84)
Adrenal gland (8305) <sup>105-112</sup>	706 (8.5)	7599 (91.5)
Duodenum (1709) <sup>4-9,24-30</sup>	1550 (90.7)	159 (9.3)
Pancreas (5368) <sup>40-76</sup>	1211 (22.6)	4157 (77.4)
Iliac vessels (1472) <sup>23,126-128</sup>	756 (51.3)	716 (48.7)
Renal artery (634) <sup>104,119-125</sup>	25 (4)	609 (96)
Inferior vena cava (329) <sup>11,12,118</sup>	293 (89.1)	36 (10.9)
Aorta (309) <sup>13-15,113-117</sup>	227 (73.5)	82 (26.5)

Isolated vascular injuries with no indication for urgent laparotomy may benefit from non-operative management, including intravascular therapy, while surgery is indicated in cases of bleeding or arterial thrombosis. In the series by Lopez-Viego et al.,<sup>15</sup> the procedure most commonly used is arteriorrhaphy (53%). For the approach of the supramesocolic region, the Mattox maneuver is used, which involves the medial mobilization of the kidney and left colon along with the spleen and tail of the pancreas. As an alternative, the Kocher maneuver is used, although its evaluation through the smaller omentum is possible. In contrast, the approach of the inframesocolic region requires cephalic and medial mobilization of the small intestine and right colon, known as the Cattle-Braasch maneuver, which facilitates the evaluation of the portal vein and inferior cava.

Proximal and distal vascular control of the injured vessel is imperative, including proximal control at the supraceliac level of the aorta at the esophageal hiatus. In unsuccessful cases or when this is not possible, left thoracotomy is performed with thoracic aortic clamping or placement of an intravascular occlusion balloon (Resuscitative Endovascular Balloon Occlusion of the Aorta).<sup>130</sup> Recent studies suggest that this device is an effective method for the treatment of hemorrhages in which direct compression is not possible, providing temporary aortic occlusion and temporary control of bleeding with an increase in mean blood pressure. In venous injuries, lateral venorrhaphy is recommended regardless of its location and when possible, including injuries of the mesenteric veins and inferior vena cava, provided that doing so does not endanger the patient's life, although ligation of the inferior cava in zone 1 has been described as a last resort.<sup>131</sup>

The most commonly used technique in the repair of iliac artery injuries is primary arteriography, followed by bypass. Meanwhile, in venous lesions, the use of ligation prevails over venorrhaphy.<sup>23</sup> The largest published series has demonstrated a greater use of intravascular techniques in blunt trauma. Embolization of the internal iliac artery is not associated with higher rates of short-term complications, although in the long term an increase in the incidence of paresthesia is observed.<sup>128</sup> As for the duodenum, when the hemodynamic situation and absence of associated injuries allow, conservative treatment can be proposed, especially patients with maintained duodenal wall integrity.<sup>9,129</sup> For correct exploration of the 4 duodenal portions and its anterior and posterior sides, it is necessary to perform the Kocher maneuver, the Cattell-Braasch maneuver, or both, and division of the ligament of Treitz may be necessary.<sup>6,31</sup>

Multiple surgical techniques have been employed, ranging from primary closure to the Whipple technique. All authors agree on the recommendation of primary closure as the initial choice technique, which is successful in up to 85% of patients and should preferably be transversal, with no tension. More complex procedures are reserved for the severest injuries.<sup>5-9,25</sup> If this is not possible, resection can be considered with primary end-to-end anastomosis or anastomosis of a jejunal loop over the defect itself. In grade I or II pancreatic injuries, it is recommended to initially opt for conservative treatment, even when the finding is intraoperative. In grade III or IV lesions, the surgical approach is recommended, for which several options have been proposed, from simple suture to

segmental resection; the decision should be individualized for each case, taking into account both the extent of the injury and the surgeon's experience. The initial maneuvers involve hemostasis and debridement of the necrotic tissue, which may require pancreatojejunostomy or pancreaticogastrotomy to avoid pancreatic insufficiency. The Whipple technique is reserved for unreconstructable injuries, large tissue losses, severe duodenal or head of the pancreas injuries, or in cases with transection of the proximal Wirsung duct in the neck of the pancreas, averting resection of the spleen and tail of the pancreas to preserve its endocrine and exocrine function.<sup>9,25,26,31,132</sup> On the other hand, the risk of anastomotic leakage and morbidity is significant, as is the learning curve of the technique, which is more complex than resection.<sup>133</sup>

In renal trauma, conservative treatment is advocated in hemodynamically stable patients with no other surgical indication,<sup>82</sup> with a success rate surpassing 90% for grades I to IV, and up to 35% for grade V.<sup>88</sup> There is an increase in the use of embolization, with failure rates of less than 15%. Delays in surgical indication have not been shown to be associated with a higher incidence of complications in the most current series.<sup>86</sup> Conservative treatment of a damaged but perfused kidney in selected patients results in less morbidity than nephrectomy. The non-surgical treatment of renal lacerations due to blunt trauma associated with extravasation is associated with fewer complications, which can generally be treated by endourological or percutaneous methods. In lacerations due to penetrating trauma, non-surgical treatment may be considered in stable patients, with no associated lesions and correctly staged, with a high index of suspicion to avoid ureteral injuries. The success of non-surgical treatment can be improved with the use of angioembolization.<sup>18,82,83</sup>

Surgical treatment ranges from the use of nephrorrhaphy to nephrectomy, either partial or total, with variable rates between series (13%-38%).<sup>94,96</sup> Cases have been described requiring delayed nephrectomy due to post-traumatic complications. There is an association between the degree of renal injury of the American Association for the Surgery of Trauma and the significant decrease in post-traumatic renal function from grade III on.<sup>92</sup> In the management of avulsions and renal lacerations, embolization is proposed as a safe alternative to surgical treatment, citing success rates higher than 94%.<sup>19,121</sup> Another consideration would be to perform angioembolization to avoid nephrectomy and the loss of renal tissue after other surgical procedures. In renal vascular lesions, there is a growing tendency toward conservative management; the percentage of nephrectomies is variable, surpassing 30% in some series compared to percentages of around 18% in the most recent publications. In the series by Sanghtong et al.,<sup>120</sup> only 27% of the total patients underwent surgical exploration of the renal artery, 67% of which underwent nephrectomy versus 32% vascular reconstructions. The use of vascular reconstruction is controversial, with percentages of late nephrectomies of up to 35% being cited, while currently it is not used in the presence of a functioning contralateral kidney.<sup>19</sup>

Most publications about ureteral injuries are composed of case reports and small series, so there is no consensus for their management. It seems clear that the presence of shock upon admission or severe colon injury requiring colectomy

**Table 2 – Most Frequently Affected Organs and Their Corresponding Approach.**

Zone	Organ	Mechanism	Diagnosis	Treatment
1	Inferior cava, aorta	Penetrating	Symptoms Intraoperative	Vascular control and suture, preferably
2	Duodenum, pancreas Kidney, adrenal gland	Blunt Blunt	CT with contrast CT with contrast	Variable according to findings Conservative
3	Iliac vessels	Penetrating	Symptoms Intraoperative	Arteriorrhaphy, venous ligation or intravascular techniques

precludes ureteral repair, so diversion or primary nephrectomy are proposed in these circumstances.

Regarding the management of adrenal trauma, this will depend on the extent of the damage, state of the contralateral gland, hemodynamic status and associated injuries.<sup>33,35,37</sup> Conservative treatment is the most widely accepted, relegating surgical treatment to the presence of associated injuries or hemodynamic instability.<sup>20,33,36,37</sup> With active extravasation of contrast during angiography and patient stability, embolization has been proposed as a safe alternative comparable to surgery.<sup>33</sup> The complex adrenal vascularization allows for selective embolization to lead to a localized infarction that does not lead to glandular insufficiency. In the largest series to date, it is estimated that around 1% of adrenal lesions require adrenalectomy.<sup>17</sup> Other than excision, procedures to achieve hemostasis are suture of the affected gland or the application of hemostatic agents and packing.

Finally, in the management of bone injuries, the main objective is to achieve hemostasis as well as to restore the integrity and stability to the pelvic ring before definitive stabilization.<sup>134</sup> In minor pelvic lesions with mechanical and hemodynamic stability, non-surgical management can be considered. In contrast, in moderate lesions (with hemodynamic stability and mechanical instability) after radiological diagnosis, the possibility of embolization can be considered individually when faced with surgical treatment or conservative management. Severe pelvic lesions are characterized by hemodynamic instability, regardless of the mechanism of injury according to the classification of the World Society of Emergency Surgery.<sup>134</sup> In these cases, the possibility of temporary stabilization measures (pelvic compression belt), preperitoneal packing, placement of an intravascular occlusion balloon and angioembolization should be considered in addition to the surgical approach.<sup>134</sup> Table 2 describes the most frequently affected organs, classified by zones, mechanism of injury, diagnostic method and treatment.

## Conclusions

### Zone 1

- The highest mortality rates are related to large vessels, so the diagnostic suspicion is essential.
- The most frequent aortic injuries are infrarenal, while vena cava injuries are predominantly adrenal.
- The therapeutic objectives are based on the control of hemostasis/contamination and the assessment of injuries.
- In the presence of hemodynamic stability and absence of contraindication, conservative management, including

angioembolization, should initially be considered. Otherwise, the use of sutures is preferable to more complex maneuvers.

### Zone 2

- Conservative treatment is the most widely accepted, and surgery is defined by the presence of associated injuries or instability. Within the surgical approach, conservative maneuvers are more frequent than nephrectomy or adrenalectomy.
- A high index of suspicion of ureteral injuries is necessary.
- Vascular reconstruction is reserved for patients with anomalies of the contralateral kidney.

### Zone 3

- Iliac vessel injuries prevail in importance due to their associated high mortality.
- Arteriorrhaphy and venous ligation stand out, together with an increase in the use of intravascular techniques.
- The management of bone injury is based on the multidisciplinary approach and individualized for each case.

## Conflict of Interest

The authors have no conflict of interests to declare.

## REFERENCES

1. El-Menyar A, Abdelrahman H, Al-Thani H, Zarour A, Parchani A, Peralta R, et al. Compartmental anatomical classification of traumatic abdominal injuries from the academic point of view and its potential clinical implication. *J Trauma Manag Outcomes*. 2014;1-8.
2. Martin RS, Meredith JW. Gastrointestinal tract injury management of acute trauma. *Essential Surgical Procedures*. Cap. 72. In: Townsend CM, editor. *Sabiston textbook of surgery 19th ed*. Philadelphia, PA: Saunders; 2012. e1351-66.
3. Porter JM, Singh Y. Value of computed tomography in the evaluation of retroperitoneal organ injury in blunt abdominal trauma. *Am J Emerg Med*. 1998;16:225-7.
4. Phillips B, Turco L, McDonald D, Mause A, Walters RW. Penetrating injuries to the duodenum: an analysis of 879 patients from the National Trauma Data Bank, 2010-2014. *J Trauma Acute Care Surg*. 2017;83:810-7.

5. Schroepel TJ, Saleem K, Sharpe JP, Magnotti LJ, Jordan AW, Fischer PE, et al. Penetrating duodenal trauma: a 19-year experience. *J Trauma Acute Care Surg.* 2016;80:461-5.
6. Fraga GP, Biazotto G, Bortoto JB, Andreollo NA, Mantovani M. The use of pyloric exclusion for treating duodenal trauma: case series. *Sao Paulo Med J.* 2008;126:337-41.
7. Bozkurt B, Ozdemir BA, Kocer B, Unal B, Dolapci M, Cengiz O. Operative approach in traumatic injuries of the duodenum. *Acta Chir Belg.* 2006;106:405-8.
8. Timaran CH, Martinez O, Ospina JA. Prognostic factors and management of civilian penetrating duodenal trauma. *J Trauma Inj Infect Crit Care.* 1999;47:330-5.
9. Levison MA, Petersen SR, Sheldon GF, Trunkey DD. Duodenal trauma: experience of a trauma center. *J Trauma Inj Infect Crit Care.* 1984;24:475-80.
10. Petrone P, Moral Álvarez S, González Pérez M, Ceballos Esparragón J, Marini CP. Traumatismos de páncreas: manejo y revisión de la literatura. *Cir Esp.* 2017; 95:123-30.
11. Tsai R, Raptis C, Schuerer DJ, Mellnick VM. CT appearance of traumatic inferior vena cava injury. *Am J Roentgenol.* 2016;207:705-11.
12. Cudworth M, Fulle A, Ramos JP, Arriagada I. GCS as a predictor of mortality in patients with traumatic inferior vena cava injuries: a retrospective review of 16 cases. *World J Emerg Surg.* 2013;8:59.
13. Charlton-Ouw KM, Dubose JJ, Leake SS, Sanchez-Perez M, Sandhu HK, Holcomb JB, et al. Observation may be safe in selected cases of blunt traumatic abdominal aortic injury. *Ann Vasc Surg.* 2016;30:34-9.
14. Deree J, Shenvi E, Fortlage D, Stout P, Potenza B, Hoyt DB, et al. Patient factors and operating room resuscitation predict mortality in traumatic abdominal aortic injury: a 20-year analysis. *J Vasc Surg.* 2007;45:493-7.
15. Lopez-Viego MA, Snyder WH III, Valentine RJ, Clagett GP. Penetrating abdominal aortic trauma: a report of 129 cases. *J Vasc Surg.* 1992;16:332-6.
16. Kuan JK, Wright JL, Nathens AB, Rivara FP, Wessells H, American Association for the Surgery of Trauma organ injury scale for kidney injuries predicts nephrectomy, dialysis, and death in patients with blunt injury and nephrectomy for penetrating injuries. *J Trauma Inj Infect Crit Care.* 2006;60:351-6.
17. Raup VT, Eswara JR, Vetter JM, Brandes SB. Epidemiology of traumatic adrenal injuries requiring surgery. *Urology.* 2016;94:227-31.
18. Burns J, Brown M, Assi ZI, Ferguson EJ. Five-year retrospective review of blunt renal injuries at a level 1 trauma center. *Am Surg.* 2017;83:148-56.
19. Chow SJD, Thompson KJ, Hartman JF, Wright ML. A 10-year review of blunt renal artery injuries at an urban level I trauma center. *Injury.* 2009;40:844-50.
20. Liao C, Lin K, Fu C, Wang S, Yang S, Ouyang C. Adrenal gland trauma: is extravasation an absolute indication for intervention? *World J Surg.* 2015;39:1312-9.
21. Asensio JA, Rojo E, Roldán G, Petrone P. Isolated adrenal gland injury from penetrating trauma. *J Trauma.* 2003;54:364-5.
22. Lauerman MH, Rybin D, Doros G, Kalish J, Hamburg N, Eberhardt RT, et al. Characterization and outcomes of iliac vessel injury in the 21st century: a review of the National Trauma Data Bank. *Vasc Endovasc Surg.* 2013;47:325-30.
23. Asensio JA, Petrone P, Roldán G, Kuncir E, Rowe VL, Chan L, et al. Analysis of 185 iliac vessel injuries: risk factors and predictors of outcome. *Arch Surg.* 2003;138:1187-94.
24. Kunin JR, Korobkin M, Ellis JH, Francis IR, Kane NM, Siegel SE. Duodenal injuries caused by blunt abdominal trauma: value of CT in differentiating perforation from hematoma. *Am J Roentgenol.* 1993;160:1221-3.
25. Cogbill TH, Moore EE, Feliciano DV, Hoyt DB, Jurkovich GJ, Morris JA, et al. Conservative management of duodenal trauma: a multicenter perspective. *J Trauma Inj Infect Crit Care.* 1990;30:1469-75.
26. Stevens A, Little JM. Duodenal trauma. *Aust New Zealand J Surg.* 1987;57:709-13.
27. Hasson JE, Stern D, Moss GS. Penetrating duodenal trauma. *J Trauma Inj Infect Crit Care.* 1984;24:471-4.
28. Corley RD, Norcross WJ, Shoemaker WC. Traumatic injuries to the duodenum. A report of 98 patients. *Ann Surg.* 1975;181:92-8.
29. McInnis WD, Aust JB, Cruz AB, Root HD. Traumatic injuries of the duodenum: a comparison of 1° closure and the jejunal patch. *J Trauma.* 1975;15:847-53.
30. Burrus GR, Howell JF, Jordan GL. Traumatic duodenal injuries: an analysis of 86 cases. *J Trauma Inj Infect Crit Care.* 1961;1:96-104.
31. García Santos E, Soto Sánchez A, Verde JM, Marini CP, Asensio JA, Petrone P. Lesiones duodenales secundarias a traumatismo: revisión de la literatura. *Cir Esp.* 2015; 93:68-74.
32. Moore EE, Cogbill TH, Malangoni MA, Jurkovich GJ, Champion HR, Gennarelli TA, et al. Organ injury scaling II: pancreas, duodenum, small bowel, colon and rectum. *J Trauma.* 1990;30:1427-9.
33. Liao C, Ouyang C, Fu C, Wang S, Lin K, Kuo I, et al. The current status and management of blunt adrenal gland trauma. *Surgery.* 2015;157:338-43.
34. Panda A, Kumar A, Gamanagatti S, Bhalla AS, Sharma R, Kumar S, et al. Are traumatic bilateral adrenal injuries associated with higher morbidity and mortality? A prospective observational study. *J Trauma Manag Outcomes.* 2015;9:6.
35. Alsayali MM, Atkin C, Rahim R, Niggemeyer LE, Doody O, Varma D. Traumatic adrenal gland injury: epidemiology and outcomes in a major Australian trauma center. *Eur J Trauma Emerg Surg.* 2010;36:567-72.
36. Burks DW, Mirvis SE, Shanmuganathan K. Acute adrenal injury after blunt abdominal trauma: CT findings. *Am J Roentgenol.* 1992;158:503-7.
37. Lee YS, Jeong JJ, Nam K, Chung WY, Chang H, Park CS. Adrenal injury following blunt abdominal trauma. *World J Surg.* 2010;34:1971-4.
38. Serafetinides E, Kitrey ND, Djakovic N, Kuehhas FE, Lumen N, Sharma DM, et al. Review of the current management of upper urinary tract injuries by the EAU trauma guidelines panel. *Eur Urol.* 2015;67:930-6.
39. Shariat SF, Roehrborn CG, Karakiewicz PI, Dhami G, Stage KH. Evidence-based validation of the predictive value of the American Association for the Surgery of Trauma kidney injury scale. *J Trauma Inj Infect Crit Care.* 2007;62:933-9.
40. Krige JE, Spence RT, Navsaria PH, Nicol AJ. Development and validation of a pancreatic injury mortality score (PIMS) based on 473 consecutive patients treated at a level 1 trauma center. *Pancreatol.* 2017;17:592-8.
41. Krige JE, Kotze UK, Setsshedi M, Nicol AJ, Navsaria PH. Management of pancreatic injuries during damage control surgery: an observational outcomes analysis of 79 patients treated at an academic level 1 trauma centre. *Eur J Trauma Emerg Surg.* 2017;43:411-20.
42. Kim S, Kim JW, Jung PY, Kwon HY, Shim H, Jang JY, et al. Diagnostic and therapeutic role of endoscopic retrograde pancreatography in the management of traumatic pancreatic duct injury patients: single center experience for 34 years. *Int J Surg.* 2017;42:152-7.
43. Mansfield N, Inaba K, Berg R, Beale E, Benjamin E, Lam L, et al. Early pancreatic dysfunction after resection in trauma: an 18-year report from a level I trauma center. *J Trauma Acute Care Surg.* 2017;82:528-33.

44. Siboni S, Kwon E, Benjamin E, Inaba K, Demetriades D. Isolated blunt pancreatic trauma: a benign injury? *J Trauma Acute Care Surg.* 2016;81:855-9.
45. Koganti SB, Kongara R, Boddepalli S, Mohammad NS, Thumma V, Nagari B, et al. Predictors of successful non-operative management of grade III & IV blunt pancreatic trauma. *Ann Med Surg.* 2016;10:103-9.
46. Girard E, Abba J, Arvieux C, Trilling B, Sage PY, Mouglin N, et al. Management of pancreatic trauma. *J Visc Surg.* 2016;153:259-68.
47. Morita T, Takasu O, Sakamoto T, Mori S, Nakamura A, Nabeta M, et al. Long-term outcomes of pancreatic function following pancreatic trauma. *Kurume Med J.* 2016;63:53-60.
48. Bao W-, She G, Duan Y, Liu S, Sun D, Yang Y, et al. Diagnosis and management of high-grade pancreatic trauma: report of 14 cases. *Indian J Surg.* 2015;77:1222-6.
49. Krige JE, Kotze UK, Nicol AJ, Navsaria PH. Isolated pancreatic injuries: an analysis of 49 consecutive patients treated at a level 1 trauma centre. *J Visc Surg.* 2015;152:349-55.
50. Krige JE, Kotze UK, Navsaria PH, Nicol AJ. Endoscopic and operative treatment of delayed complications after pancreatic trauma: an analysis of 27 civilians treated in an academic level 1 trauma centre. *Pancreatology.* 2015;15:563-9.
51. Krige JE, Kotze UK, Setshedi M, Nicol AJ, Navsaria PH. Prognostic factors, morbidity and mortality in pancreatic trauma: a critical appraisal of 432 consecutive patients treated at a level 1 trauma centre. *Injury.* 2015;46:830-6.
52. Lv F, Tang J, Luo Y, Nie Y, Liang T, Jiao Z, et al. Emergency contrast-enhanced ultrasonography for pancreatic injuries in blunt abdominal trauma. *Radiol Med.* 2014;119:920-7.
53. Kong Y, Zhang H, He X, Liu C, Piao L, Zhao G, et al. Endoscopic management for pancreatic injuries due to blunt abdominal trauma decreases failure of nonoperative management and incidence of pancreatic-related complications. *Injury.* 2014;45:134-40.
54. Krige JE, Kotze UK, Nicol AJ, Navsaria PH. Morbidity and mortality after distal pancreatectomy for trauma: a critical appraisal of 107 consecutive patients undergoing resection at a level 1 trauma centre. *Injury.* 2014;45:1401-8.
55. Thomson DA, Krige JE, Thomson SR, Bornman PC. The role of endoscopic retrograde pancreatography in pancreatic trauma: a critical appraisal of 48 patients treated at a tertiary institution. *J Trauma Acute Care Surg.* 2014;76:1362-6.
56. Gordon RW, Anderson SW, Ozonoff A, Rekh S, Soto JA. Blunt pancreatic trauma: evaluation with MDCT technology. *Emerg Radiol.* 2013;20:259-66.
57. Memon AA, Zafar H, Raza R, Murtaz G. Traumatic pancreatic injury – an elusive diagnosis: experience from a developing country urban trauma referral centre. *J Pak Med Assoc.* 2013;63:440-4.
58. Iqbal CW, Levy SM, Tsao K, Petrosyan M, Kane TD, Pontarelli EM, et al. Laparoscopic versus open distal pancreatectomy in the management of traumatic pancreatic disruption. *J Laparoendosc Adv Surg Tech.* 2012;22:595-8.
59. Kaman L, Iqbal J, Pall M, Bhukal I, Behera A, Singh G, et al. Current management of pancreatic trauma. *Trop Gastroenterol.* 2012;33:200-6.
60. Bhasin DK, Rana SS, Rao C, Gupta R, Verma GR, Kang M, et al. Endoscopic management of pancreatic injury due to abdominal trauma. *J Pancreas.* 2012;13:187-92.
61. Lee PH, Lee SK, Kim GU, Hong S, Kim J, Hyun Y, et al. Outcomes of hemodynamically stable patients with pancreatic injury after blunt abdominal trauma. *Pancreatology.* 2012;12:487-92.
62. Heuer M, Hussmann B, Lefering R, Taeger G, Kaiser GM, Paul A, et al. Pancreatic injury in 284 patients with severe abdominal trauma: outcome, course, and treatment algorithm. *Langenbeck's Arch Surg.* 2011;396:1067-76.
63. Lee W, Foo N, Lin H, Huang Y, Chen K. The efficacy of four-slice helical CT in evaluating pancreatic trauma: a single institution experience. *J Trauma Manag Outcomes.* 2011;5.
64. Krige JE, Hameed M, Navsaria PH. Pancreatic injuries after blunt abdominal trauma: an analysis of 110 patients treated at a level 1 trauma centre. *S Afr J Surg.* 2011; 49:58-67.
65. Rogers SJ, Cello JP, Schecter WP. Endoscopic retrograde cholangiopancreatography in patients with pancreatic trauma. *J Trauma Inj Infect Crit Care.* 2010;68:538-44.
66. Tan K, Chan DX, Vijayan A, Chiu M. Management of pancreatic injuries after blunt abdominal trauma. Experience at a single institution. *J Pancreas.* 2009; 10:657-63.
67. Recinos G, DuBose JJ, Teixeira PGR, Inaba K, Demetriades D. Local complications following pancreatic trauma. *Injury.* 2009;40:516-20.
68. Thomas H, Madanur M, Bartlett A, Marangoni G, Heaton N, Rela M. Pancreatic trauma-12-year experience from a tertiary center. *Pancreas.* 2009;38:113-6.
69. Lochan R, Sen G, Barrett AM, Scott J, Charnley RM. Management strategies in isolated pancreatic trauma. *J Hepato-Biliary-Pancreatic Surg.* 2009;16:189-96.
70. Seong YH, Young CC. Prognostic determinants in patients with traumatic pancreatic injuries. *J Korean Med Sci.* 2008;23:126-30.
71. Al-Ahmadi K, Ahmed N. Outcomes after pancreatic trauma: experience at a single institution. *Can J Surg.* 2008;51:118-24.
72. Scollay JM, Yip VSK, Garden OJ, Parks RW. A population-based study of pancreatic trauma in Scotland. *World J Surg.* 2006;30:2136-41.
73. Olah A, Issekutz A, Haulik L, Makay R. Pancreatic transection from blunt abdominal trauma: early versus delayed diagnosis and surgical management. *Dig Surg.* 2003;20:408-12.
74. Mayer JM, Tomczak R, Rau B, Gebhard F, Beger HG. Pancreatic injury in severe trauma: early diagnosis and therapy improve the outcome. *Dig Surg.* 2002;19:291-7.
75. Kim HS, Lee DK, Kim IHW, Baik SK, Kwon SO, Park JW, et al. The role of endoscopic retrograde pancreatography in the treatment of traumatic pancreatic duct injury. *Gastrointest Endosc.* 2001;54:49-55.
76. Vasquez JC, Coimbra R, Hoyt DB, Fortlage D. Management of penetrating pancreatic trauma: an 11-year experience of a level-1 trauma center. *Injury.* 2001;32:753-9.
77. Burns J, Brown M, Assi ZI, Ferguson EJ. Five-year retrospective review of blunt renal injuries at a Level 1 Trauma Center. *Am Surg.* 2017;83:148-56.
78. Shariat SF, Roehrborn CG, Karakiewicz PI, Dhimi G, Stage KH. Evidence-based validation of the predictive value of the American Association for the Surgery of Trauma kidney injury scale. *J Trauma Inj Infect Crit Care.* 2007;62:933-9.
79. Winters B, Wessells H, Voelzke BB. Readmission after treatment of grade 3 and 4 renal injuries at a level 1 trauma center: statewide assessment using the Comprehensive Hospital Abstract Reporting System. *J Trauma Acute Care Surg.* 2016;80:466-71.
80. Patel DP, Redshaw JD, Breyer BN, Smith TG, Erickson BA, Majercik SD, et al. High-grade renal injuries are often isolated in sports-related trauma. *Injury.* 2015;46:1245-9.
81. Kuan JK, Wright JL, Nathens AB, Rivara FP, Wessells H. American Association for the Surgery of Trauma organ injury scale for kidney injuries predicts nephrectomy, dialysis, and death in patients with blunt injury and nephrectomy for penetrating injuries. *J Trauma Inj Infect Crit Care.* 2006;60:351-6.



82. McPhee M, Arumainayagam N, Clark M, Burfitt N, DasGupta R. Renal injury management in an urban trauma centre and implications for urological training. *Ann R Coll Surg Engl.* 2015;97:194-7.
83. Santucci RA, McAninch JW, Safir M, Mario LA, Service S, Segal MR. Validation of the American Association for the Surgery of Trauma organ injury severity scale for the kidney. *J Trauma Inj Infect Crit Care.* 2001;50:195-200.
84. Saour M, Charbit J, Millet I, Monnin V, Taourel P, Klouche K, et al. Effect of renal angioembolization on post-traumatic acute kidney injury after high-grade renal trauma: a comparative study of 52 consecutive cases. *Injury.* 2014;45:894-901.
85. Figler BD, Malaeb BS, Voelzke B, Smith T, Wessells H. External validation of a substratification of the American association for the surgery of trauma renal injury scale for grade 4 injuries. *J Am Coll Surg.* 2013;217:924-8.
86. Van Der Wilden GM, Velmahos GC, Joseph DK, Jacobs L, DeBusk MG, Adams CA, et al. Successful nonoperative management of the most severe blunt renal injuries: a multicenter study of the research consortium of New England centers for trauma. *JAMA Surg.* 2013;148:924-31.
87. Hardee MJ, Lowrance W, Stevens MH, Nirula R, Brant WO, Morris SE, et al. Process improvement in trauma: compliance with recommended imaging evaluation in the diagnosis of high-grade renal injuries. *J Trauma Acute Care Surg.* 2013;74:558-62.
88. Shoobridge JJ, Bultitude MF, Koukounaras J, Martin KE, Royce PL, Corcoran NM. A 9-year experience of renal injury at an Australian level 1 trauma centre. *BJU Int.* 2013;112 Suppl 2:53-60.
89. Van Der Vlies CH, Olthof DC, van Delden OM, Ponsen KJ, de La Rosette JJMCH, de Reijke TM, et al. Management of blunt renal injury in a level 1 trauma centre in view of the European guidelines. *Injury.* 2012;43:1816-20.
90. Sugihara T, Yasunaga H, Horiguchi H, Nishimatsu H, Fukuhara H, Enomoto Y, et al. Management trends, angioembolization performance and multiorgan injury indicators of renal trauma from Japanese administrative claims database. *Int J Urol.* 2012;19:559-63.
91. Buckley JC, McAninch JW. Revision of current American Association for the Surgery of Trauma renal injury grading system. *J Trauma Inj Infect Crit Care.* 2011;70:35-7.
92. Tasian GE, Aaronson DS, McAninch JW. Evaluation of renal function after major renal injury: correlation with the American Association for the Surgery of Trauma Injury Scale. *J Urol.* 2010;183:196-200.
93. Nuss GR, Morey AF, Jenkins AC, Pruitt JH, Dugi DD, Morse B, et al. Radiographic predictors of need for angiographic embolization after traumatic renal injury. *J Trauma Inj Infect Crit Care.* 2009;67:578-82.
94. García HA, Urrea MF, Serna A, Aluma LJ. Clinical management of renal injuries at Hospital Universitario Del Valle (Cali Colombia). *Actas Urol Esp.* 2009;33:881-7.
95. Dunfee BL, Lucey BC, Soto JA. Development of renal scars on CT after abdominal trauma: does grade of injury matter? *Am J Roentgenol.* 2008;190:1174-9.
96. Nash PA, Bruce JE, McAninch JW, Corriere J. Nephrectomy for traumatic renal injuries. *J Urol.* 1995;153:609-11.
97. Presti JC, Carroll PR, McAninch JW. Ureteral and renal pelvic injuries from external trauma: diagnosis and management. *J Trauma Inj Infect Crit Care.* 1989; 29:370-4.
98. Cass AS, Bublick M, Luxenberg M, Gleich P, Smith C. Renal trauma found during laparotomy for intra-abdominal injury. *J Trauma Inj Infect Crit Care.* 1985;25:997-1000.
99. Bogash M, Pollack H, Cates JL. Renal injuries caused by external blunt trauma. Moderate approach to serious injuries. *Urology.* 1974;4:509-13.
100. Peterson NE, Norton LW. Injuries associated with renal trauma. *J Urol.* 1973;109:766-8.
101. Cass AS, Ireland GW. Comparison of the conservative and surgical management of the more severe degrees of renal trauma in multiple injured patients. *J Urol.* 1973;109:8-10.
102. Del Villar RG, Ireland GW, Cass AS. Management of renal injury in conjunction with the immediate surgical treatment of the acute severe trauma patient. *J Urol.* 1972;107:208-11.
103. Lang EK, Trichel BE, Turner RW, Fontenot RA, Johnson B, St Martin EC. Arteriographic assessment of injury resulting from renal trauma. An analysis of 74 patients. *J Urol.* 1971;106:1-8.
104. Rohner TJ. Experience with renal injuries from penetrating trauma in Vietnam. *J Trauma Inj Infect Crit Care.* 1971;11:118-21.
105. Raup VT, Eswara JR, Vetter JM, Brandes SB. Epidemiology of traumatic adrenal injuries requiring surgery. *Urology.* 2016;94:227-31.
106. Liao C, Lin K, Fu C, Wang S, Yang S, Ouyang C. Adrenal gland trauma: Is extravasation an absolute indication for intervention? *World J Surg.* 2015;39:1312-9.
107. Liao C, Ouyang C, Fu C, Wang S, Lin K, Kuo I, et al. The current status and management of blunt adrenal gland trauma. *Surgery.* 2015;157:338-43.
108. Panda A, Kumar A, Gamanagatti S, Bhalla AS, Sharma R, Kumar S, et al. Are traumatic bilateral adrenal injuries associated with higher morbidity and mortality? A prospective observational study. *J Trauma Manag Outcomes.* 2015;9:6.
109. Lee YS, Jeong JJ, Nam K, Chung WY, Chang H, Park GS. Adrenal injury following blunt abdominal trauma. *World J Surg.* 2010;34:1971-4.
110. Alsayali MM, Atkin C, Rahim R, Niggemeyer LE, Doody O, Varma D. Traumatic adrenal gland injury: epidemiology and outcomes in a major Australian trauma center. *Eur J Trauma Emerg Surg.* 2010;36:567-72.
111. Stawicki SP, Hoey BA, Grossman MD, Anderson HL III, Reed JF III. Adrenal gland trauma is associated with high injury severity and mortality. *Curr Surg.* 2003;60:431-6.
112. Burks DW, Mirvis SE, Shanmuganathan K. Acute adrenal injury after blunt abdominal trauma: CT findings. *Am J Roentgenol.* 1992;158:503-7.
113. Berthet J, Marty-Ané C, Veerapen R, Picard E, Mary H, Alric P, et al. Dissection of the abdominal aorta in blunt trauma: endovascular or conventional surgical management? *J Vasc Surg.* 2003;38:997-1004.
114. Inaba K, Kirkpatrick AW, Finkelstein J, Murphy J, Brenneman FD, Boulanger BR, et al. Blunt abdominal aortic trauma in association with thoracolumbar spine fractures. *Injury.* 2001;32:201-7.
115. Gupta BK, Khaneja SC, Flores L, Eastlick L, Longmore W, Shaftan GW. The role of intra-aortic balloon occlusion in penetrating abdominal trauma. *J Trauma Inj Infect Crit Care.* 1989;29:861-5.
116. Myles RA, Yellin AE. Traumatic injuries of the abdominal aorta. *Am J Surg.* 1979;138:273-7.
117. Freeark RJ, Love L, Baker RJ. The role of aortography in the management of blunt abdominal trauma. *J Trauma Inj Infect Crit Care.* 1968;8:557-71.
118. Graham JM, Mattox KL, Beall AC, Debakey ME. Traumatic injuries of the inferior vena cava. *Arch Surg.* 1978; 113:413-8.
119. Chow SJD, Thompson KJ, Hartman JF, Wright ML. A 10-year review of blunt renal artery injuries at an urban level I trauma centre. *Injury.* 2009;40:844-50.
120. Sangthong B, Demetriades D, Martin M, Salim A, Brown C, Inaba K, et al. Management and hospital outcomes of blunt renal artery injuries: analysis of 517 patients from the

- National Trauma Data Bank. *J Am Coll Surg.* 2006; 203:612-7.
121. Sofocleous CT, Hinrichs C, Hubbi B, Broutzos E, Kaul S, Kannarkat G, et al. Angiographic findings and embolotherapy in renal arterial trauma. *Cardiovasc Intervent Radiol.* 2005;28:39-47.
  122. Lupetin AR, Mainwaring BL, Daffner RH. CT diagnosis of renal artery injury caused by blunt abdominal trauma. *Am J Roentgenol.* 1989;153:1065-8.
  123. Cass AS, Luxenberg M. Management of renal artery injuries from external trauma. *J Urol.* 1987;138:266-8.
  124. Cass AS, Luxenberg M. Traumatic thrombosis of a segmental branch of the renal artery. *J Urol.* 1987;137:1115-6.
  125. Cosgrove MD, Mendez R, Morrow JW. Traumatic renal arteriovenous fistula: report of 12 cases. *J Urol.* 1973;110:627-31.
  126. Lauerman MH, Rybin D, Doros G, Kalish J, Hamburg N, Eberhardt RT, et al. Characterization and outcomes of iliac vessel injury in the 21st century: a review of the National Trauma Data Bank. *Vasc Endovasc Surg.* 2013;47:325-30.
  127. Cestero RF, Plurad D, Green D, Inaba K, Putty B, Benfield R, et al. Iliac artery injuries and pelvic fractures: a national trauma database analysis of associated injuries and outcomes. *J Trauma Inj Infect Crit Care.* 2009;67:715-8.
  128. Travis T, Monsky WL, London J, Danielson M, Brock J, Wegelin J, et al. Evaluation of short-term and long-term complications after emergent internal iliac artery embolization in patients with pelvic trauma. *J Vasc Intervent Radiol.* 2008;19:840-7.
  129. Best CD, Petrone P, Buscarini M, Demiray S, Kuncir E, Kimbrell B, et al. Traumatic ureteral injuries: a single institution experience validating the american association for the surgery of trauma-organ injury scale grading scale. *J Urol.* 2005;173:1202-5.
  130. Moore LJ, Martin CD, Harvin JA, Wade CE, Holcomb JB. Resuscitative endovascular balloon occlusion of the aorta for control of noncompressible truncal hemorrhage in the abdomen and pelvis. *Am J Surg.* 2016;212:1222-30.
  131. Van Rooyen PL, Karusseit VO, Mokoena T. Inferior vena cava injuries: a case series and review of the South African experience. *Injury.* 2015;46:71-5.
  132. Asensio JA, Petrone P, Roldán G, Kuncir E, Demetriades D. Pancreaticoduodenectomy: a rare procedure for the management of complex pancreaticoduodenal injuries. *J Am Coll Surg.* 2003;197:937-42.
  133. Subramanian A, Dente CJ, Feliciano DV. The management of pancreatic trauma in the modern era. *Surg Clin N Am.* 2007;87:1515-32.
  134. Coccolini F, Stahel PF, Montori G, Biffi W, Horer TM, Catena F, et al. Pelvic trauma: WSES classification and guidelines. *World J Emerg Surg.* 2017;12:5.