



## Image of the month

## Thrombosis of the Hepatic Round Ligament Associated With Acute Cholangitis<sup>☆</sup>



### Trombosis del ligamento redondo del hígado asociado a colangitis aguda

Andrea Craus Miguel,<sup>a,\*</sup> Fátima Sena Ruiz,<sup>a</sup> Myriam Fernández Isart,<sup>b</sup> Francisco González Argente<sup>a</sup>

<sup>a</sup> Servicio de Cirugía General y Aparato Digestivo, Hospital Son Espases, Palma de Mallorca, Spain

<sup>b</sup> Unidad de Cirugía Colorrectal, Servicio de Cirugía General y Aparato Digestivo, Hospital Son Espases, Palma de Mallorca, Spain

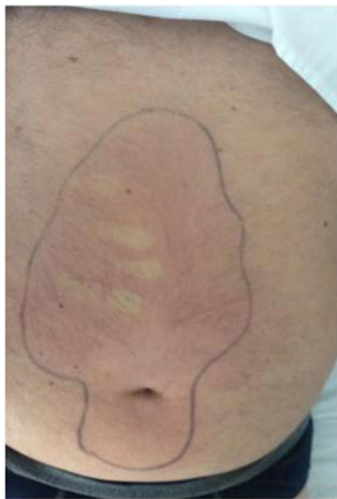

Fig. 1

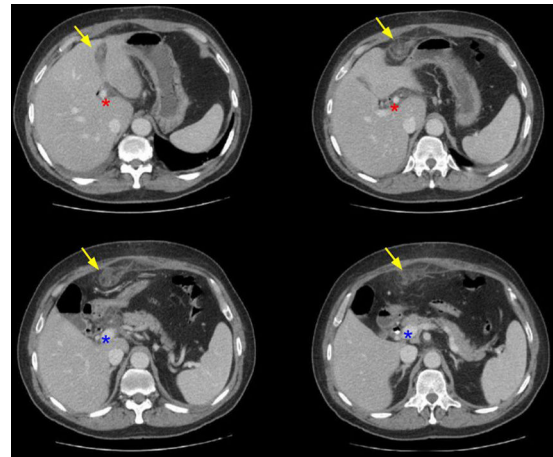


Fig. 2

A 63-year-old patient with no history came to the Emergency Room with pain in the right hypochondrium.

On examination, the patient presented tachycardia and respiratory failure. Lab work showed total bilirubin 6.3 mg/dL, affecting direct levels, GGT 717 U/L and PCR 15.62 mg/dL.

Abdominal CT scan was compatible with cholechololithiasis, with no signs suggestive of acute cholecystitis. With a diagnosis of cholangitis, antibiotic therapy was initiated and ERCP was performed with papillotomy and biliary stent placement. On the 4th day, a new pattern of pain began, revealing an area of cellulitis from the periumbilical region to the epigastrium (Fig. 1). A new CT scan (Fig. 2) showed occlusion and thickening of the umbilical vein, while the splenic-portal-mesenteric venous axis remained permeable. Anticoagulant treatment was started without requiring surgical drainage as there was no abscess, and the risk of generalized peritonitis was therefore low. After 10 days, the biliary prosthesis was removed and laparoscopic cholecystectomy was conducted afterwards.

<sup>☆</sup> Please cite this article as: Craus Miguel A, Sena Ruiz F, Fernández Isart M, González Argente F. Trombosis del ligamento redondo del hígado asociado a colangitis aguda. Cir Esp. 2018;96:302.

\* Corresponding author.

E-mail address: [acrausm@gmail.com](mailto:acrausm@gmail.com) (A. Craus Miguel).