



Image of the month

Unusual Complication of a Lung Hydatid Cyst: Pneumomediastinum, Hydropneumothorax, and Massive Soft Tissue Emphysema[☆]



Complicación infrecuente de un quiste hidatídico de pulmón: neumomediastino, hidroneumotórax y enfisema masivo de tejidos blandos

Gökhan Polat,^{*} Hayri Ogul, Fatih Ergun, Mecit Kantarci

Department of Radiology, Faculty of Medicine, Ataturk University, Erzurum, Turkey

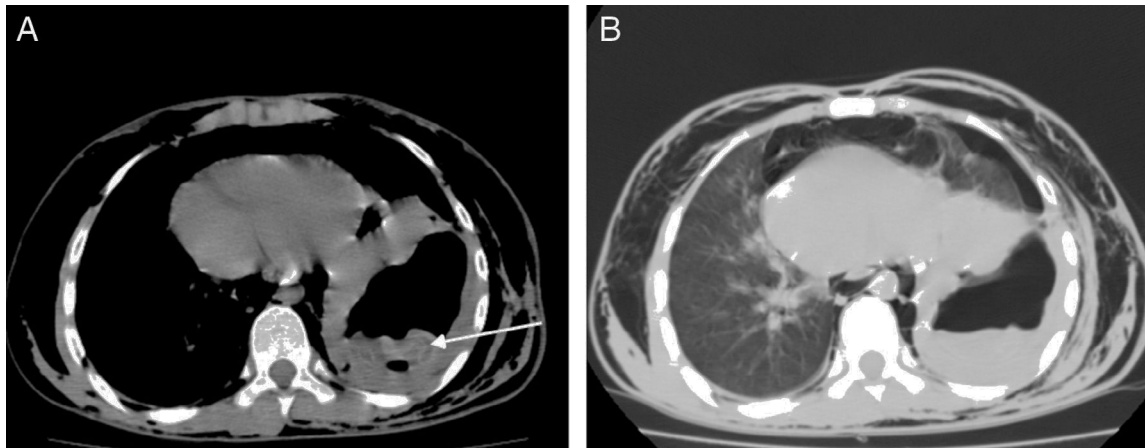


Fig. 1

A 15-year-old male came to the emergency department after 3 days with intense chest pain and dyspnea. Thoracic computed tomography (CT) without contrast showed pneumomediastinum, soft tissue emphysema, hydropneumothorax and a giant hydatid cyst with ruptured membranes in the lower lobe of the left lung (Fig. 1A and B; arrow: rupture of membranes). As a result of these findings, the patient was diagnosed with a ruptured hydatid cyst. The treatment consisted of thoracotomy, cystectomy and lavage of the pneumomediastinum. No complications were observed in the patient follow-up.

[☆] Please cite this article as: Polat G, Ogul H, Ergun F, Kantarci M. Complicación infrecuente de un quiste hidatídico de pulmón: neumomediastino, hidroneumotórax y enfisema masivo de tejidos blandos. Cir Esp. 2017;95:610.

^{*} Corresponding author.

E-mail address: dr.g.polat@gmail.com (G. Polat).